

Esthetic and Functional Management of Diastema

A Multidisciplinary
Approach

Ugur Erdemir
Esra Yildiz *Editors*

 Springer

Esthetic and Functional Management of Diastema

Ugur Erdemir • Esra Yildiz
Editors

Esthetic and Functional Management of Diastema

A Multidisciplinary Approach

 Springer

Editors

Ugur Erdemir
Faculty of Dentistry
University of Istanbul
Istanbul
Turkey

Esra Yildiz
Faculty of Dentistry
University of Istanbul
Istanbul
Turkey

ISBN 978-3-319-24359-7

ISBN 978-3-319-24361-0 (eBook)

DOI 10.1007/978-3-319-24361-0

Library of Congress Control Number: 2015957405

Springer Cham Heidelberg New York Dordrecht London

© Springer International Publishing Switzerland 2016

This work is subject to copyright. All rights are reserved by the Publisher, whether the whole or part of the material is concerned, specifically the rights of translation, reprinting, reuse of illustrations, recitation, broadcasting, reproduction on microfilms or in any other physical way, and transmission or information storage and retrieval, electronic adaptation, computer software, or by similar or dissimilar methodology now known or hereafter developed.

The use of general descriptive names, registered names, trademarks, service marks, etc. in this publication does not imply, even in the absence of a specific statement, that such names are exempt from the relevant protective laws and regulations and therefore free for general use.

The publisher, the authors and the editors are safe to assume that the advice and information in this book are believed to be true and accurate at the date of publication. Neither the publisher nor the authors or the editors give a warranty, express or implied, with respect to the material contained herein or for any errors or omissions that may have been made.

Printed on acid-free paper

Preface

Diastemas can negatively affect the patients' smile and can be a major esthetic concern for patients as well as observers. In some situations, closure of diastema particularly in cases with excessive spaces presents a challenging treatment procedure, and it is not possible to correct diastemas to achieve the desired harmony, esthetics, and function without multidisciplinary interventions including orthodontics and/or periodontology because neither of the disciplines is able to correct this problem alone.

Due to recent advances in the art and science of dentistry, there are a variety of tools and treatment options that a practitioner can use. Recent trends in dentistry require multidisciplinary and collaborative treatment procedures using minimal invasive treatment approaches, and these provide clinicians with optimal treatment options ensuring esthetically pleasing, functional, and long-lasting restorations. This book represents a comprehensive and multidisciplinary management of diastema by collaboration of restorative dentistry, periodontology, and orthodontics using minimally invasive and functional treatment procedures.

The aim of this book is to demonstrate the necessity of the multidisciplinary approaches with minimally invasive treatment procedures and the clinical protocol for the esthetic treatment of diastema with an integrated orthodontic, periodontal, and restorative approach. In addition, it provides a comprehensive treatment planning by the analysis of the study models, photographs, occlusion, and soft and hard tissue as well as facial analysis which should also be evaluated for a satisfactory treatment outcome. Each chapter addresses various aspects of diastema starting from its etiology toward clinical considerations, esthetic evaluations, occlusion, and periodontal considerations with interdisciplinary treatment procedures and treatment options. Specific tips in the relevant chapters were also highlighted in the text for the clinicians regarding the application procedures.

Treating an esthetic dental problem as in the case of diastema requires determining etiological factors, diagnosis, treatment planning, and selection of the appropriate materials and instrument. Then, a collaborative treatment should be performed in order to achieve esthetically pleasing and functional restorations. Therefore, we organized this book in order to better understand diastema, from its etiology to the treatment options.

Clinicians will find definition of diastema and underlying etiological factors in Chap. 2 for a better understanding of the causative factors related to this esthetical

problem. In Chap. 3, patient history and clinical considerations in diastema cases were defined, and in Chap. 4, the diagnosis of this problem was presented in detail. As a part of the treatment planning in diastema cases, we have also provided the clinicians with the esthetic considerations starting from the planning through the smile design for treating unaesthetic alignment, shape or form of the teeth, and shade, enhancing the esthetic appearance along with the function (Chaps. 5, 6, 7, and 8). We have also provided information about soft tissue considerations and management of diastema cases in Chap. 9. In Chap. 10, 11, 12, 13, and 14, clinicians can find multidisciplinary treatment planning, its importance in the treatment phase and treatment sequencing in the light of a well-planned treatment, and direct and/or indirect treatment options with the proper material selection.

We have used hundreds of scientific citations in this book to present to clinicians the evidence-based recommendations and techniques in the treatment of diastema cases. After reading this book clinicians will have detailed and comprehensive knowledge on diastema and its interdisciplinary esthetic and functional management for creation of a pleasant final outcome.

Istanbul, Turkey

Ugur Erdemir
Esra Yildiz

Acknowledgments

When we decided to write this book, we did not know it would be a laborious and time-consuming mission. Regarding accepting this book project, we would like to gratefully acknowledge Professor Dr. Taner Yucel for supporting us in every step of this project and sharing his experiences and professionalism.

We the editors of this book also express our special thanks to the esteemed contributing authors for accepting our proposal in writing this book and their contributions, cooperation, and dedication in spite their busy working schedules.

We also thank Dr. Nese Gonul who gave considerable time and invaluable assistance for orthodontic chapters and Dr. Bekir Baysal who provided the digital software program.

We are grateful to Drs. Nurhan Inan Altay, Miiiddin Saipullaev, and Ilkin Babakishiev for their kind assistance during the clinical applications and taking the photographs.

We also wish to thank laboratory technician Levent Ozyilan for his excellent work and local dental products companies who supported us with novel materials.

In addition, we would like to express our thanks to the staff at Springer, Ulrike Huesken and Joni Fraser, for their effort in developing this project.

Finally, we would like to express our gratitude to our families for their support and encouragement.

Contents

1 Introduction	1
Ugur Erdemir and Esra Yildiz	
2 Definition and Causes of Diastema	5
Esra Yildiz, Taner Yucel, Ugur Erdemir, Derya Germec Cakan, and Korkmaz Sayinsu	
3 Initial Consultation and/or Clinical Considerations (Patient History)	17
Ugur Erdemir, Esra Yildiz, and Taner Yucel	
4 Diagnosis	39
Taner Yucel, Esra Yildiz, Ugur Erdemir, Derya Germec Cakan, and Korkmaz Sayinsu	
5 Esthetic Parameters/Smile Design	53
Ugur Erdemir, Esra Yildiz, and Taner Yucel	
6 Facial-Dentofacial Analysis	65
Esra Yildiz, Taner Yucel, Ugur Erdemir, and Derya Germec Cakan	
7 Dentolabial Analysis	81
Taner Yucel, Esra Yildiz, and Ugur Erdemir	
8 Dental Analysis	101
Ugur Erdemir, Taner Yucel, Esra Yildiz, Derya Germec Cakan, and Korkmaz Sayinsu	
9 Soft Tissue Considerations in the Management of Diastemas	121
Korkud Demirel	
10 Treatment Planning	131
Esra Yildiz, Taner Yucel, Ugur Erdemir, and Korkud Demirel	

11 Treatment Options, Timing and Sequencing: Orthodontics	141
Derya Germec Cakan and Korkmaz Sayinsu	
12 Treatment Options, Timing and Sequencing: Direct-Indirect Restorative Treatment	169
Ugur Erdemir, Taner Yucel, and Esra Yildiz	
13 Material Selection: Restorative Materials	185
Taner Yucel, Esra Yildiz, and Ugur Erdemir	
14 Cases: Applications	197
Esra Yildiz, Taner Yucel, Ugur Erdemir, Korkmaz Sayinsu, Derya Germec Cakan, and Korkud Demirel	
Index	223

Ugur Erdemir and Esra Yildiz

Abstract

The space between the anterior teeth is called diastema and negatively affects the patients' smile, psychology, and daily business life by creating disharmony on the patients' face and unattractive smile. Therefore, a comprehensive treatment planning including determination of etiologic factors, soft tissue morphology, occlusion, patient needs, demands, and esthetic considerations should be evaluated carefully for satisfactory outcomes. To accomplish a successful treatment plan and final outcome, multidisciplinary collaboration between orthodontics, restorative dentistry, and periodontology has become necessary in the recent years.

The presence of a gap or space between the adjacent anterior teeth with black areas is called diastema. This unpleasant problem of the teeth commonly occurring in adult dentition negatively affects the patients smile and can be a major esthetic concern for both patients and observers. However, in some situation, especially in small midline diastemas, these spaces do not adversely affect the patient's image and, hence, may not require a treatment [2] (Fig. 1.1). Therefore, before the treatment planning, the etiology of the diastema, patient needs, and demands [1], esthetic considerations, as well as the soft tissue morphology should be evaluated carefully for the satisfactory outcomes.

The etiology of diastema, may be a disproportion in size and shape of the teeth, affecting the dental harmony [3] (Fig. 1.2). Consequently, these problems can cause the formation of single or polydiastema in the arch. Therefore, a

U. Erdemir, PhD, DDS (✉) • E. Yildiz, PhD, DDS
Operative Dentistry, University of Istanbul Faculty of Dentistry, Istanbul, Turkey
e-mail: uerdemir@hotmail.com

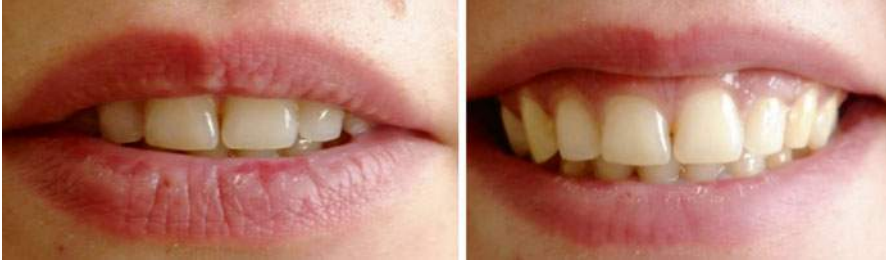

Fig. 1.1 A 20-year-old patient representing approximately 0.5 mm midline diastema without any esthetic complaint

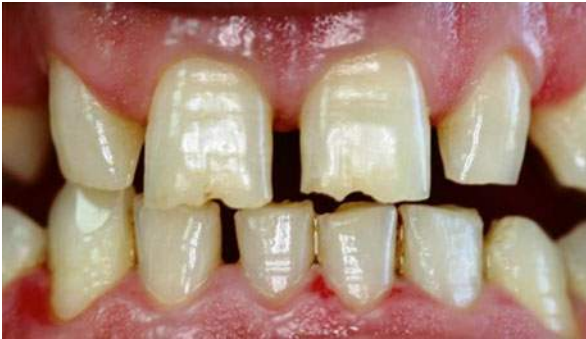

Fig. 1.2 The patient representing disproportionate teeth with polydiastema

comprehensive examination and detailed diagnosis are important for understanding the contributing factors of diastema in adult dentition before planning the appropriate treatment [1, 4].

Current literature suggests that diastemas can be treated by orthodontics, restorative dentistry and prosthodontics or by their combinations [5–8]. In some of the cases, periodontal surgery either frenectomy or crown lengthening or in both (Fig. 1.3a, b) would also be necessary in diastema closure for creating a long-term harmony between the final restoration and soft tissue morphology [5, 6]. Therefore, a careful diagnosis, meticulously prepared treatment plan addressing the causative factors of diastema and communication with the patient would allow the practitioner to select the best treatment option for each case [1].

Among the suggested treatment options, orthodontic treatment stands for effectively correcting the diastema beside the high appreciation of the patients despite the longer treatment time and expensive treatment costs [1, 6]. However, this treatment option is not able to correct all diastema cases with a satisfactory results, especially in the presence of excessive spaces [1, 6]. For this reason, restorative treatment with or without periodontal surgery is also mandatory for optimal treatment outcome. On the other hand, restorative treatments either by direct application with resin composite restorations or indirectly with porcelain laminate veneers

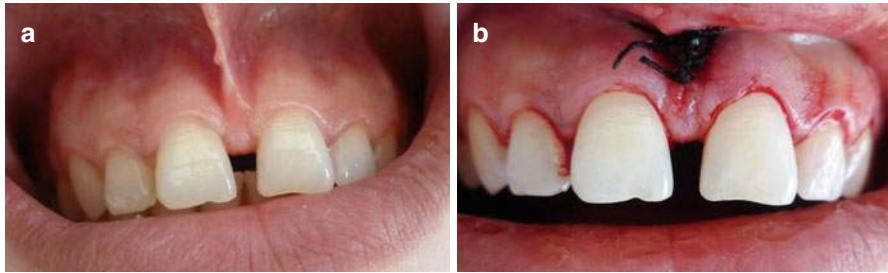


Fig. 1.3 (a) A midline diastema due to enlarged frenum and relatively short tooth crowns. (b) Surgical frenectomy and gingival crown lengthening procedure at the same visit

(PLVs) are minimal invasive diastema closure procedures that have been described as successful restorative treatments [1, 4, 9–11].

Soft tissue considerations are also essential for creating a harmonious and esthetic final result between the restorations, hard tissues and surrounding gingiva [8]. Therefore, periodontal treatments such as, gingivectomy, crown lengthening, soft tissue repositioning, frenectomy are essential for creating an ideal soft tissue form corresponding to the tooth proportions [1, 10].

Based on the above mentioned procedures, multidisciplinary collaborative treatment between orthodontics, restorative dentistry and periodontology has become vital in recent years for creating a harmony between the teeth, the soft tissue, the facial form and the function to optimize the final outcome in diastema closure [1, 7, 10] as in many dental treatment procedures.

In recent years, increased esthetic expectations and demands by the patients have emerged improvements in both adhesive technology and enhancement of esthetic, physical and mechanical properties of restorative dental materials, which enables a variety of direct-indirect minimally invasive restorations [1, 4, 7, 12]. Direct restorations with new generation composite resins or indirect restorations either with composite resins or PLVs are minimal invasive and esthetic restorative treatments for diastema closure requiring “no preparation” or “minimal preparation” of the tooth [1, 4, 10, 11].

The specific goal of this book is to present a multidisciplinary approach between the orthodontics, periodontics and restorative dentistry for diastema closure and discuss the most appropriate treatment planning related to its etiology.

References

1. Oquendo A, Brea L, David S. Diastema: correction of excessive spaces in the esthetic zone. *Dent Clin North Am.* 2011;55(2):265–81.
2. Kokich VO, Kokich VG, Kiyak HA. Perceptions of dental professionals and laypersons to altered dental esthetic: asymmetric and symmetric situations. *Am J Orthod Dentofacial Orthop.* 2006;130(2):141–51.
3. Chu FC, Siu AS, Newsome PR, Wei SH. Management of median diastema. *Gen Dent.* 2001;49(3):282–7.

4. Signore A, Kaitsas V, Tonoli A, Angiero F, Silvestrini-Biavati A, Benedicenti S. Sectional porcelain veneers for a maxillary midline diastema closure: a case report. *Quintessence Int.* 2013;44(3):201–6.
5. Blatz MB, Hürzeler MB, Strub JR. Reconstruction of the lost interproximal papilla – presentation of surgical and nonsurgical approaches. *Int J Periodontics Restorative Dent.* 1999;19(4):395–406.
6. De Araujo Jr EM, Fortkamp S, Baratieri LN. Closure of diastema and gingival recontouring using direct adhesive restorations: a case report. *J Esthet Restor Dent.* 2009;21(4):229–40.
7. Furuse AY, Herkrath FJ, Franco EJ, Benetti AR, Mondelli J. Multidisciplinary management of anterior diastemata: clinical procedures. *Pract Proced Aesthet Dent.* 2007;19(3):185–91.
8. Pinto RC, Chambrone L, Colombini BL, Ishikiriama SK, Britto IM, Romito GA. Minimally invasive esthetic therapy: a case report describing the advantages of a multidisciplinary approach. *Quintessence Int.* 2013;44(5):385–91.
9. Lenhard M. Closing diastemas with resin composite restorations. *Eur J Esthet Dent.* 2008;3(3):258–68.
10. Furuse AY, Franco EJ, Mondelli J. Esthetic and functional restoration for an anterior open occlusal relationship with multiple diastemata: a multidisciplinary approach. *J Prosthet Dent.* 2008;99(2):91–4.
11. Gurel G. Porcelain laminate veneers for diastema closure. In: *The science and art of PLV.* Ergolding: Quintessence Publishing; 2003. p. 369–92.
12. Belser UC, Magne P, Magne M. Ceramic laminate veneers: continuous evolution of indications. *J Esthet Dent.* 1997;9(4):197–207.

Esra Yildiz, Taner Yucel, Ugur Erdemir,
Derya Germec Cakan, and Korkmaz Sayinsu

Abstract

Diastema has a multifactorial etiology. Some of the etiological factors are clear-cut, whereas others are controversial and not completely elucidated. It is very important to define the possible causes because the treatment of diastema depends on the correct diagnosis of the etiology and elimination of the causes. This chapter will describe diastema and related etiological factors.

Diastema is defined as a space or a gap which is greater than 0.5 mm between the adjacent teeth [1]. It is called as “midline diastema” when seen between maxillary central incisors [2, 3] or “polydiastema” when seen between a group of teeth in the dental arch (Fig. 2.1a, b).

Generally these spaces create an unpleasant appearance for individuals. Sometimes they may lead to phonetic problems, particularly in cases with wide spaces [2].

Diastema necessitates treatment because of esthetic, psychological, and functional concerns. However, the maxillary midline diastema is a normal growth feature of children in the primary and mixed dentition period and, in most of the cases, it decreases or even completely closes by the medial eruption of the maxillary lateral incisors and canines in childhood [2–5]. However, for some individuals, the

E. Yildiz, PhD, DDS (✉) • T. Yucel, PhD, DDS • U. Erdemir, PhD, DDS
Operative Dentistry, University of Istanbul Faculty of Dentistry, Istanbul, Turkey
e-mail: eyildiz1966@hotmail.com

D. Germec Cakan, DDS, PhD
Orthodontics, Yeditepe University, Dental Faculty, Istanbul, Turkey

K. Sayinsu, DDS, PhD
Orthodontics, Private Practice, Istanbul, Turkey

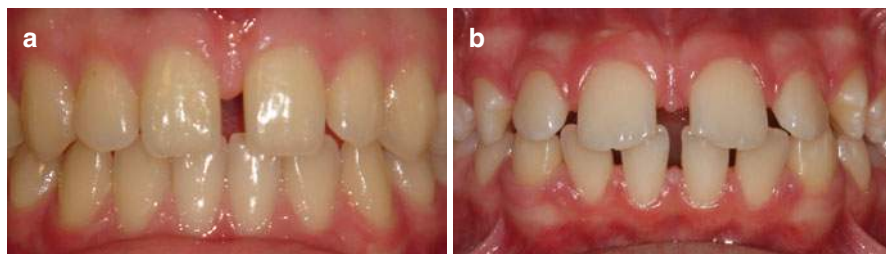


Fig. 2.1 (a) Midline diastema: space between maxillary central incisors, (b) polydiastema: generalized spacing between teeth

spaces remain after the transition of dentition [2, 6]. In contrast to the maxillary diastema, the mandibular one is rarely seen in children and is more dramatic than the maxillary diastema. To date, it has been reported that not only a factor is responsible in the formation of diastema but it has multifactorial etiology including the possible genetic predisposition [2, 3, 5, 7–9]. Due to the multifactorial etiology of the diastema, it is important to understand the causes of the condition to select the most appropriate treatment.

Key Note

Due to multifactorial origin of the diastema, clinician should understand the etiological factor before initiating any treatment modality.

2.1 Causes of Congenital or Acquired Diastema

2.1.1 Physiological Development of the Dentition

As mentioned above, spacing in anterior teeth is a normal feature of the primary and mixed dentition. The spacing of the primary dentition is the sign of the available spaces allowing for accommodation and proper alignment of the permanent teeth which are larger in size than their preceding [10, 11]. The average primary interdental spacing is 4 mm in the maxilla and 3 mm in the mandible [10] (Fig. 2.2a–c). This physiological diastema normally decreases or closes by the eruption of the lateral incisors and/or canines in most of the cases [2–5, 12]. If there is no blocking pathologic or physiologic condition, spontaneous closure can be expected [5].

Maxillary midline diastema may persist until the end of the mixed dentition [13] (Fig. 2.3). In this stage of development, also referred as “ugly duckling stage,” developing canines mesially push the roots of the central and lateral incisors causing distal movement of the crowns, leading to maxillary midline diastema (Fig. 2.4a–e). If the midline spacing is 2 mm or less, it will be spontaneously corrected by the eruption of the permanent canines resulting in mesial movement of the incisor’s crowns, whereas a greater diastema is unlikely to close without intervention [14].

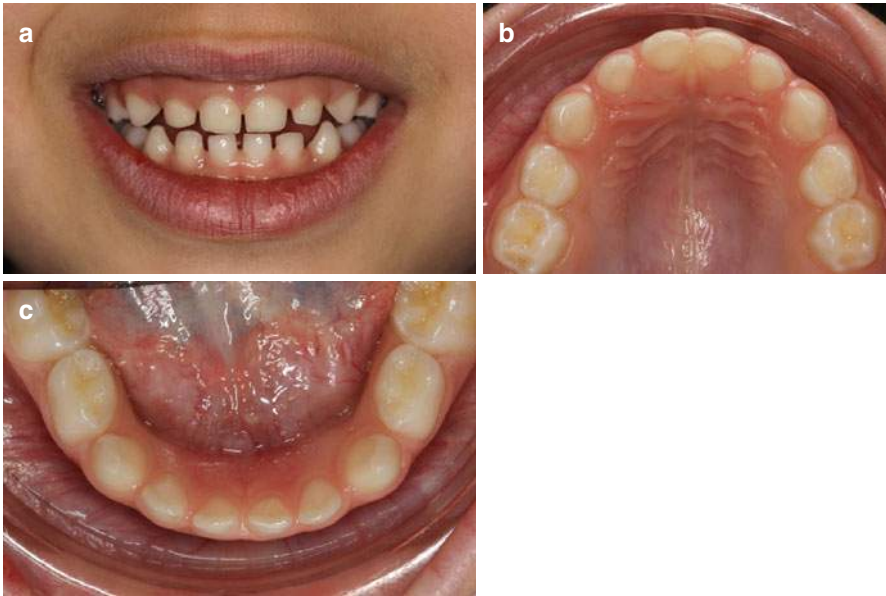


Fig. 2.2 (a–c) Physiologic spacing in a 5-year-old girl required for the proper alignment of the permanent incisors

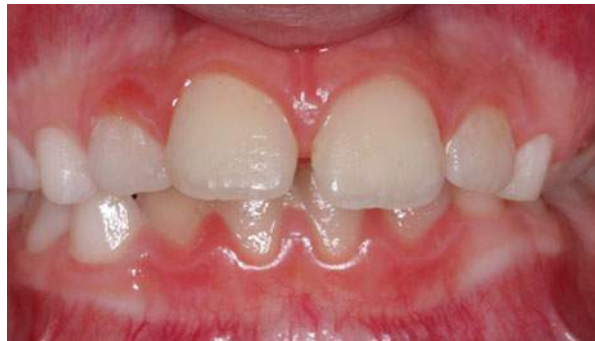

Fig. 2.3 Maxillary midline diastema in mixed dentition stage

2.1.2 Heredity and Ethnicity

A familial incidence of diastema has been shown, indicating a hereditary and genetic disposition [7, 9]. Its hereditary background is probably due to the genetic control of the tooth size and agenesis which are the most common etiological factors of dental spacing and seems to be supported by studies revealing the genetic basis of hypodontia and microdontia [15, 16]. Analysis of a pedigree data suggested an autosomal dominant mode of inheritance of maxillary midline diastema and showed a difference of heritability between ethnic groups [9]. Lower heritability in black race than in white race was explained by the possibility of greater influence of environmental factors on maxillary midline diastema in black population.

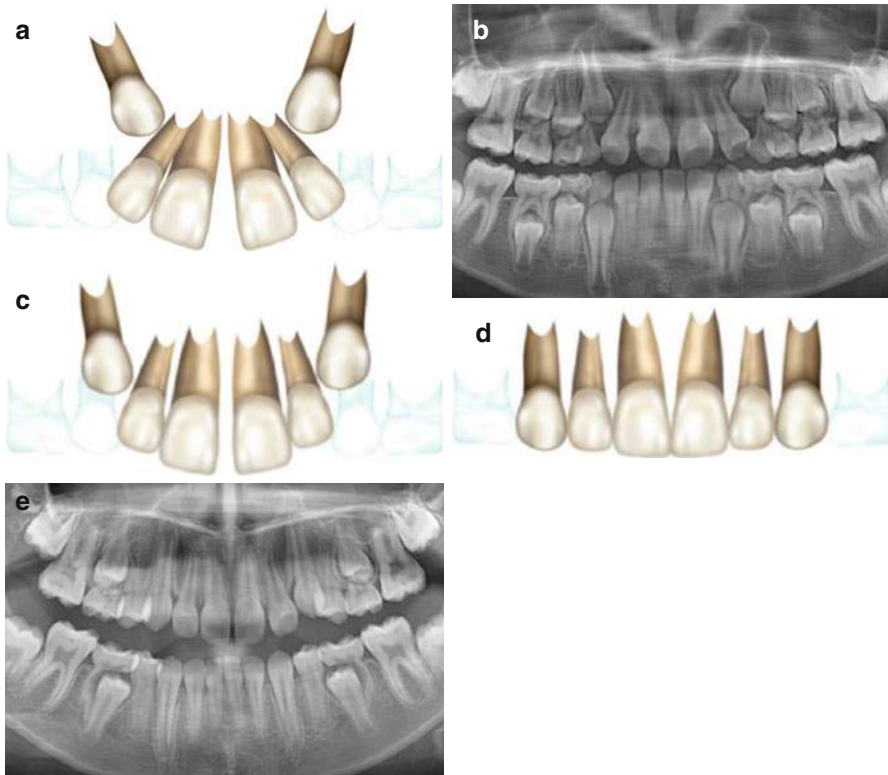


Fig. 2.4 Ugly duckling stage. (a, b) Obvious distal inclination of the maxillary incisors creating a midline diastema in the mixed dentition. (c) Maxillary incisors tend to upright by the eruption of the permanent canines and the midline diastema reduces. (d, e) Spontaneous closure of maxillary midline diastema after the canines are fully erupted

The incidence of midline diastema differs in terms of ethnicity. According to Lavelle [17], maxillary midline diastema incidence is 3.4 % in Caucasian population, 5.5 % in Negroid population, and 1.7 % in Mongoloid population, whereas 1.6 % was reported for Indian population [7].

2.1.3 Dentoalveolar Discrepancies (Tooth Size and Arch Length Discrepancies)

Conditions associated with the tooth size and arch length discrepancies which result in an imbalance between the width of the teeth and arch length are the most common causes of the diastema in adults [18, 19]. This can be due to microdontia, hypodontia, or increased arch dimensions. In other words, diastema occurs when the mesiodistal width of the anterior teeth is normal but the dental arch is larger (Fig. 2.5a, b) or the anterior teeth, particularly maxillary

lateral incisors, are smaller than the normal size (peg-shaped) and the arch length is normal [7, 20] (Fig. 2.6a–c).

It has been reported that small-sized or peg-shaped maxillary lateral incisors are the most common tooth size discrepancies among the tooth size abnormalities [4, 5]. This may result in localized spacing in the lateral incisor region or sometimes may lead to maxillary midline diastema due to distal migration of the central incisors into the space that have been formed at the mesial of the lateral incisors [5]. Similarly, when there is congenital or acquired absence of the lateral incisors, migration of the adjacent teeth creates generalized diastema [2, 5, 20] (Fig. 2.7a, b). Furthermore, the central incisors of the subjects with congenitally missing lateral incisors are likely to be smaller than the norms, leading to increased spacing. An association between hypodontia and microdontia has been revealed in the literature [21].

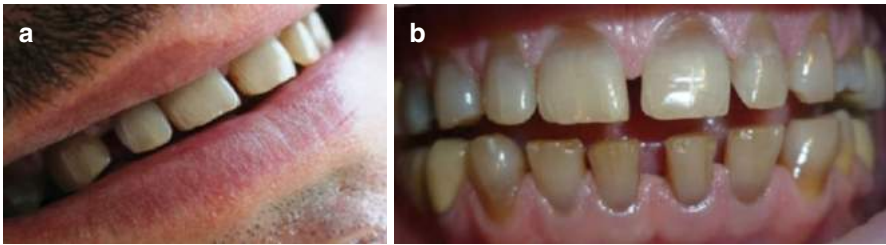


Fig. 2.5 (a, b) Generalized maxillary spacing due to tooth size–arch size discrepancy

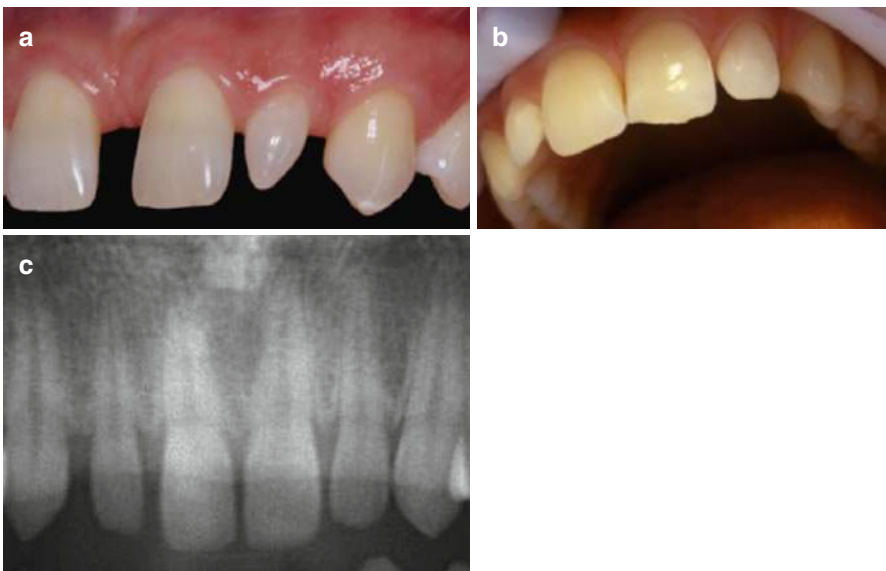


Fig. 2.6 (a) Peg-shaped maxillary lateral incisor. (b) Small-sized lateral incisor, (c) radiographic appearance of the figure b

2.1.4 Enlarged Labial Frenum and Deficient Intermaxillary Suture

Enlarged maxillary labial frenum has been reported as a cause or a consequence of the maxillary midline diastema [2, 5, 8] (Fig. 2.8a–c). At the beginning of 1900s, it has been described that the abnormal frenum was the cause of the maxillary midline diastema [22]. Shashua and Artun [8] have correlated existence of an enlarged labial

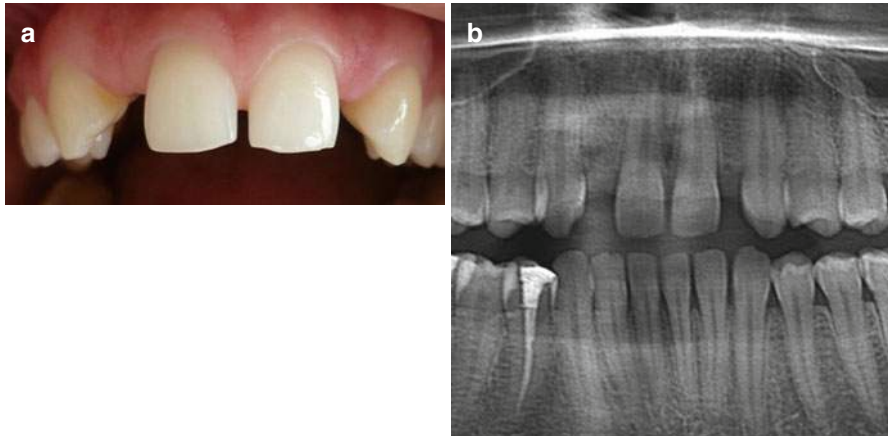


Fig. 2.7 (a) Clinical and (b) radiographic appearance of a generalized diastema in a case with bilateral congenitally missing maxillary lateral incisors

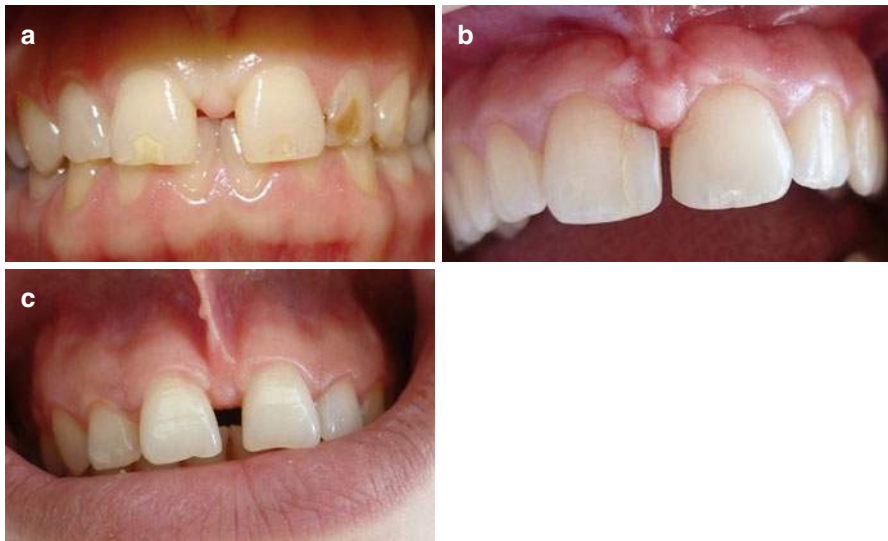


Fig. 2.8 (a–c) Clinical appearance of enlarged maxillary labial frenums causing maxillary midline diastema

frenum and occurrence of diastema in their study. During the eruption of the maxillary central incisors, a physiological space may exist between these teeth, and spontaneous closure of the space and atrophy of the labial frenum may occur at this stage after the eruption of the maxillary lateral incisors and canines [2, 23, 24]. However, sometimes this phenomenon does not occur, and the maxillary central incisors may erupt widely separated from each other. In this case, labial frenum can be attached deep within the tissue into the notch of the alveolar bone and create a heavily fibrous tissue between the central incisors causing a diastema [2, 23, 25]. In such cases, enlarged and deep fibrous frenum attachment does not change with age [5, 26] and will resist spontaneous closure of the space [3, 5, 12]. Contrary to these reports, it has been stated later that abnormal frenum was a consequence rather than the cause of diastema [2, 5, 27, 28]. It has been claimed that the eruption of the teeth, development of the alveolar process, and hypertrophic frenum occur simultaneously in the coronal direction. Thus, no or minimal pressure can be generated on the frenum to prevent the formation of diastema [28, 29]. It was previously reported that there were no correlation between the abnormal frenum and width of the diastema, width of frenum and diastema, or between the frenum length and width [2, 23]. Bergström et al. [27] concluded that the diastema closure progressed more rapidly in patients with surgically frenectomized group than in the non-frenectomized group, but the final results after 10 years were the same. In conclusion, enlarged or abnormal frenum can restrain the approximation of the maxillary central incisors, but may not be considered as an important etiological factor in maxillary midline diastema [2]. Before the management of this problem, a careful clinical evaluation should be carried on along with the patient's age and other relevant parameters related to this condition [5, 24, 26].

In cases with enlarged frenum, generally maxillary bone does not deposit inferior of the frenum, and a "V"-shaped bone structure develops between the central incisors [2, 5, 20, 23] (Fig. 2.9a, b). It has been suggested that slightly bisected V-shaped maxillary bone clefts can discontinue the formation of interdental gingival fibers and cause a median diastema [2, 5, 20]. Moreover, Popovich et al. [28, 29] stated that

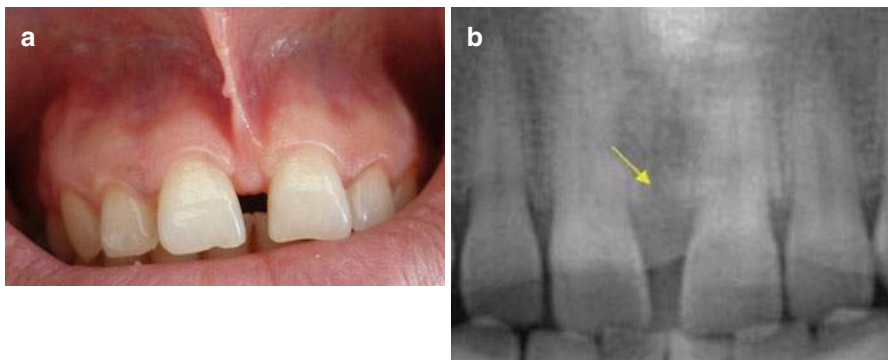


Fig. 2.9 (a) Clinical appearance of a 45-year-old female patient with midline diastema, (b) radiographic finding of notching of the intermaxillary alveolar bone (arrow)

incomplete maxillary bone commissure can result in a median diastema when other predisposing factors also present as confirmed in other studies [5, 8]. A V-shaped incomplete bone structure can be diagnosed by radiographs, particularly on periapical ones, and the maxillary central incisors and surrounding alveolar structures normally appear on radiographs with slightly divided intermaxillary structure [5].

Other appearances which are considered as abnormal are “W-shaped” and “circumscribed irregular ovoid” maxillary bone structures [5]. In these cases, maxillary suture is bisected relatively deeper and mostly accompanied by an inferiorly attached frenum that can cause wider diastemas than V-shaped one [5, 28, 29].

2.1.5 Systemic, Pathologic, and Physical Conditions

The loss of bone support around the teeth in alveolar socket due to periodontitis can lead to migration of the teeth and cause diastemas both in adolescents and adults (Fig. 2.10a, b). Localized juvenile periodontitis which is an aggressive periodontal problem in adolescents is characterized by the excessive loss of periodontal attachments and alveolar bone socket around the permanent incisors and can result in the migration of maxillary incisors creating a median diastema [2, 20].

Another pathological condition that can cause the diastema on the maxillary region is cysts and fibromas [2, 20, 30, 31]. These pathological conditions can create diastema on maxillary arch either by deviating the eruption pattern or by physically moving the incisors laterally. In such cases, central incisors generally

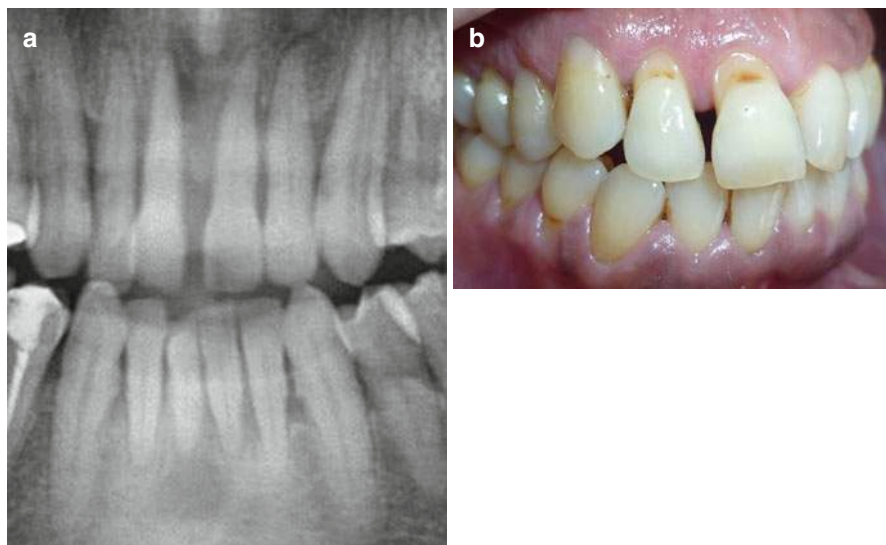


Fig. 2.10 (a) Radiographic appearance of the diastema in patients with periodontal problems, (b) clinical appearance of the diastema in adult patient due to periodontitis

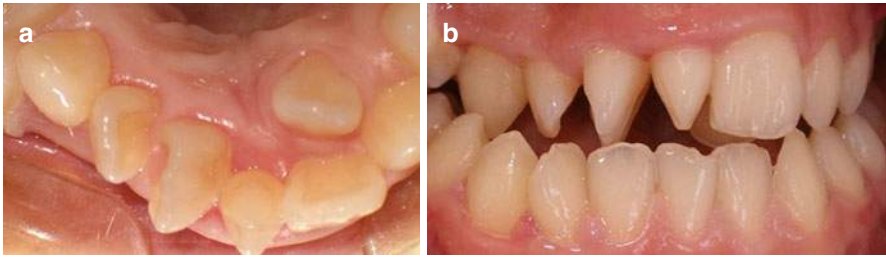


Fig. 2.11 (a, b) Clinical appearance of a supernumerary teeth between two central incisors, which caused creation of diastema

settle in an incorrect position on the arch, and therefore, approximation of the teeth is not possible [20, 30–32].

Mesiodens, a supernumerary teeth between two central incisors, is also a factor for the development of diastema [5, 33] (Fig. 2.11a, b). Mesiodens usually does not allow the approximation of central incisors by medial movement and closure of the diastema [5]. Tay et al. [34] reported that supernumerary teeth can cause delayed eruption of permanent teeth when they are in normal direction, but when they are not normally positioned, they cause displacement of central incisors leading to diastema.

Systemic disease such as diabetes mellitus can also cause the loss of bone support and hence can lead to formation of median and/or multiple diastema in the maxillary arch as well as in the mandibular arch. Acromegaly which is a condition of endocrinological disorder and characterized by excessive skeletal growth, may lead to diastema due to relatively large dental arch compared to tooth size [2].

2.1.6 Unbalanced Muscular Function and Habits

The teeth are exposed to forces created by tooth contacts, soft tissue pressures (lip, cheek, and tongue muscles), and intrinsic pressures (periodontal ligament and gingival fibers) during resting and function. There is an equilibrium between these forces which keeps the teeth in their neutral position [35]. If this equilibrium is disrupted due to macroglossia, oral syndrome, flabby lip muscle, tongue thrust, etc., tooth movement is likely to occur until a new balance is generated [2]. If there is no change or elimination of these imbalanced forces, tooth movement occurs, creating spaces between the teeth and causing the diastema.

Chronic and prolonged oral habits of the patients (e.g., digit sucking) are considered as possible equilibrium influences. The chronic pernicious habits can procline the incisors due to abnormal pressure. The alteration of the balanced forces between “lips, cheeks, and tongue” may cause the spacing of the dentition [2, 20].

The size, position, and functions of the tongue have been claimed as contributing factors to the development of spacing in the dental arches. But the relationship between the tongue and the malocclusion is controversial. Tongue thrusting has been proposed as an etiologic factor of diastema [36]. However, the duration of tongue thrusting during swallowing and speech is too short to create tooth movement. On the other hand, abnormal pressure due to forward tongue posture at rest generates light but long durational forces, which may lead to horizontal and vertical tooth movement [37]. Another tongue-related equilibrium problem causing diastema is defined as macroglossia [36, 38, 39]. In macroglossia, the resting tongue protrudes beyond the teeth leading to proclination of upper and lower incisors and development of diastemas.

2.1.7 Iatrogenic Factors (Rapid Maxillary Expansion)

Rapid maxillary expansion is a common method to treat maxillary constriction by opening of the midpalatal suture. The separation of the suture creates diastema between the maxillary central incisors [40]. The midline diastema increases by the activation of the expansion screw and spontaneously closes after the termination of expansion due to gingival stretch (Fig. 2.12a–d).

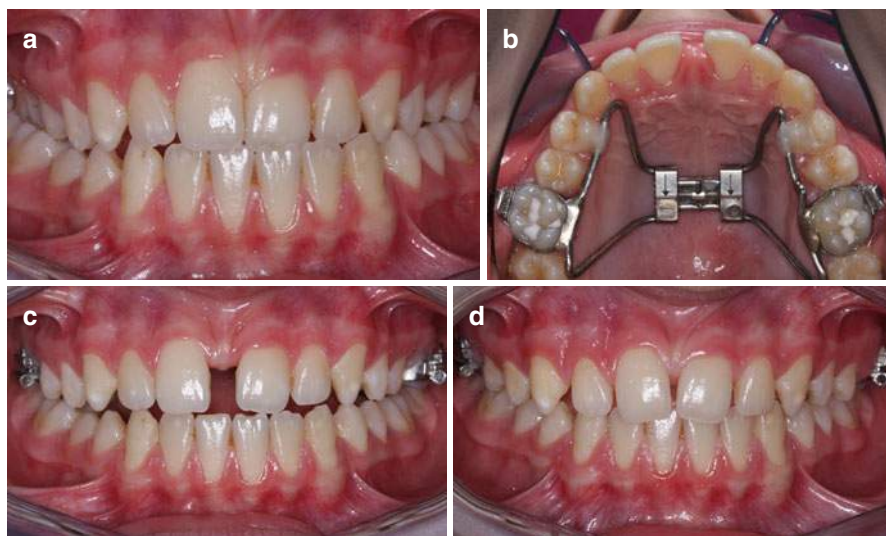


Fig. 2.12 Rapid maxillary expansion in a 13-year-old boy. (a) Maxillary constriction with bilateral posterior crossbite (note the tight proximal contact between the maxillary central incisors). (b, c) Appearance of a midline diastema indicating midpalatal suture opening after rapid maxillary expansion. (d) Spontaneous closure of the midline diastema during a retention period of 3 months

References

1. Keene HJ. Distribution of diastemas in the dentition of man. *Am J Phys Anthropol.* 1963;21:437–41.
2. Huang WJ, Creath CJ. The midline diastema: a review of its etiology and treatment. *Pediatr Dent.* 1995;17(3):171–9.
3. Osterle LJ, Shellhart WC. Maxillary midline diastemas: a look at the causes. *J Am Dent Assoc.* 1999;130(1):85–94.
4. Proffit WR, Fields Jr HW, Sarver DM. *Contemporary orthodontics.* 4th ed. St. Louis: Mosby Elsevier; 2007. p. 86, 98, 464.
5. Gkantidis N, Kolokitha OE, Topouzelis N. Management of maxillary midline diastema with emphasis on etiology. *J Clin Pediatr Dent.* 2008;32(4):265–72.
6. Proffit WR, Fields Jr HW, Sarver DM. *Contemporary orthodontics.* 4th ed. St. Louis: Mosby Elsevier; 2007. p. 100.
7. Nainar SM, Gnanasundaram N. Incidence and etiology of midline diastema in a population in south India (Madras). *Angle Orthod.* 1989;59(4):277–82.
8. Shashua D, Artun J. Relapse after orthodontic correction of maxillary median diastema: a follow-up evaluation of consecutive cases. *Angle Orthod.* 1999;69(3):257–63.
9. Gass JR, Valiathan M, Tiwari HK, Hans MG, Elston RC. Familial correlations and heritability of maxillary midline diastema. *Am J Orthod Dentofacial Orthop.* 2003;123:35–9.
10. Dale JG, Dale HC. Interceptive guidance of occlusion with emphasis on diagnosis. In: Graber TM, Vanarsdall Jr RL, Vig KWL, editors. *Orthodontics: current principles and techniques.* 5th ed. St. Louis: Elsevier Mosby; 2012. p. 423–76.
11. Proffit WR, Fields Jr HW, Sarver DM. *Contemporary orthodontics.* 4th ed. St. Louis: Mosby Elsevier; 2007. p. 98.
12. Moyers R. *Handbook of orthodontics.* 4th ed. Chicago: Year Book Medical Publishers; 1988. p. 348–60.
13. Van Der Linden FPGM. *Orthodontic concepts and strategies.* London: Quintessence Publishing; 2004. p. 2–16.
14. English JD, Peltomaki T, Pham-Litschel K. *Mosby's orthodontic review.* St. Louis: Mosby Elsevier; 2009. p. 195.
15. Woolf CM. Missing maxillary lateral incisors: a genetic study. *Am J Hum Genet.* 1971;23:289–96.
16. Arte S, Nieminen P, Pirinen S, Thesleff I, Peltonen L. Gene defect in hypodontia: exclusion of EGF, EGFR, and FGF-3 as candidate genes. *J Dent Res.* 1996;75:1346–52.
17. Lavelle CLB. The distribution diastemas in different human population samples. *Scand J Dent Res.* 1970;78:530–4.
18. Furuse AY, Herkrath FJ, Franco EJ, Benetti AR, Mondelli J. Multidisciplinary management of anterior diastemata: clinical procedures. *Pract Proced Aesthet Dent.* 2007;19(3):185–91.
19. Oquendo A, Brea L, David S. Diastema: correction of excessive spaces in the esthetic zone. *Dent Clin North Am.* 2011;55(2):265–81.
20. Joneja P, Pal V, Tiwari M, Hazari P. Factors to be considered in the treatment of midline diastema. *Int J Curr Pharm Res.* 2013;5(2):1–3.
21. Brook AH, Elcock C, al-Sharood MH, McKeown HF, Khalaf K, Smith RN. Further studies of a model for the etiology of anomalies of tooth number and size in humans. *Connect Tissue Res.* 2002;43:289–95.
22. Angle EH. *Treatment of malocclusion of teeth.* 7th ed. Philadelphia: SS White Dental Manufacturing Company; 1907. p. 103–4.
23. Dewel BF. The labial frenum, midline diastema, and palatine papilla: a clinical analysis. *Dent Clin North Am.* 1966;175–84.
24. Lindsey D. The upper mid-line space and its relation to the labial fraenum in children and in adults. A statistical evaluation. *Br Dent J.* 1977;143(10):327–32.

25. Díaz-Pizán ME, Lagravère MO, Villena R. Midline diastema and frenum morphology in the primary dentition. *J Dent Child (Chic)*. 2006;73(1):11–4.
26. Edwards JG. The diastema, the frenum, the frenectomy: a clinical study. *Am J Orthod*. 1977;71(5):489–508.
27. Bergström K, Jensen R, Mårtensson B. The effect of superior labial frenectomy in cases with midline diastema. *Am J Orthod*. 1973;63(6):633–8.
28. Popovich F, Thompson GW, Main PA. The maxillary interincisal diastema and its relationship to the superior labial frenum and intermaxillary suture. *Angle Orthod*. 1977;47(4):265–71.
29. Popovich F, Thompson GW, Main PA. Persisting maxillary diastema: differential diagnosis and treatment. *Dent J*. 1977;43(7):330–3.
30. Bishara SE. Management of diastemas in orthodontics. *Am J Orthod*. 1972;61(1):55–63.
31. Follin ME. Orthodontic movement of maxillary incisor into the midline. A case report. *Swed Dent J*. 1985;9(1):9–13.
32. Neville BW, Damm DD, Brock T. Odontogenic keratocysts of the midline maxillary region. *J Oral Maxillofac Surg*. 1997;55(4):340–4.
33. Tyrologou S, Koch G, Kurok J. Location, complications and treatment of mesiodentes – a retrospective study in children. *Swed Dent J*. 2005;29(1):1–9.
34. Tay F, Pang A, Yuen S. Unerupted maxillary anterior supernumerary teeth: report of 204 cases. *ASDC J Dent Child*. 1984;51(4):289–94.
35. Proffit WR, Fields Jr HW, Sarver DM. Contemporary orthodontics. 4th ed. St. Louis: Mosby Elsevier; 2007. p. 145–8.
36. Attia Y. Midline diastemas: closure and stability. *Angle Orthod*. 1993;63(3):209–12.
37. Proffit WR, Fields Jr HW, Sarver DM. Contemporary orthodontics. 4th ed. St. Louis: Mosby Elsevier; 2007. p. 153–4.
38. Kadouch DJM, Maas SM, Dubois L, van der Horst CMAM. Surgical treatment of macroglossia in patients with Beckwith-Wiedemann syndrome: a 20-year experience and review of the literature. *Int J Oral Maxillofac Surg*. 2012;41:300–8.
39. Farronato G, Salvadori S, Giannini L, Maspero C. Congenital macroglossia: surgical and orthodontic management. *Prog Orthod*. 2012;13:92–8.
40. Proffit WR, Fields Jr HW, Sarver DM. Contemporary orthodontics. 4th ed. St. Louis: Mosby Elsevier; 2007. p. 286.

Initial Consultation and/or Clinical Considerations (Patient History)

3

Ugur Erdemir, Esra Yildiz, and Taner Yucel

Abstract

Initial consultation is important for both patient and clinician for a joint evaluation of an esthetic treatment plan. Multiple appointments are necessary to create optimal results and satisfactory outcomes for both patient and clinician; hence, a comprehensive evaluation of the patient before initiation of any therapy is mandatory. Sufficient time should be allotted for initial consultation to gather necessary information and response the specific questions related to the case. Thereafter, a detailed medical history of the patient should be gathered to identify the conditions that could contraindicate, complicate, or alter the treatment procedure. In addition, extraoral, muscle, intraoral, periodontal, radiographic, and occlusion examinations should be performed meticulously, with attention also devoted to esthetic considerations.

Because of the multifactorial etiology of diastemas, a detailed analysis of the patient, involving medical/dental history and clinical evaluation along with dental x-rays, is essential for the long-term success of treatment [1]. Before the initiation of a definitive treatment procedure for a patient who has midline diastema or polydiastema, the clinician must first understand the etiology of the condition. The diastema or spaces between the teeth can be due to several factors, which was described in Chap. 2: an anomaly such as mesiodens or hypodontia, discrepancies between the tooth size and arch length such as microdontia, an enlarged frenum, pernicious oral habits, and systemic oral pathological conditions [2].

U. Erdemir, PhD, DDS (✉) • E. Yildiz, PhD, DDS • T. Yucel, PhD, DDS
Operative Dentistry, University of Istanbul Faculty of Dentistry, Istanbul, Turkey
e-mail: uerdemir@hotmail.com

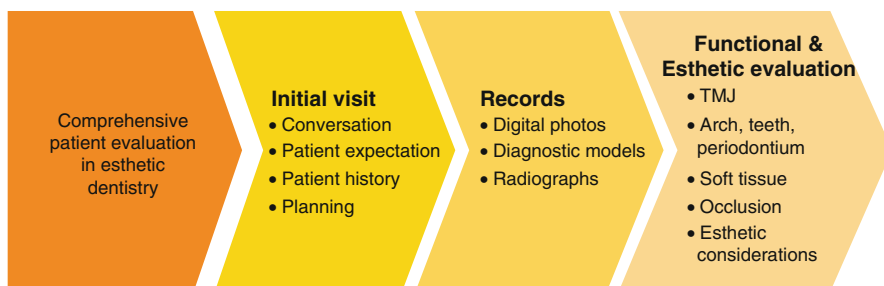


Fig. 3.1 Roadmap of comprehensive patient evaluation in esthetic dentistry

In addition, a treatment plan should not be based solely on closing the diastema by treating two or more teeth; it must also include the assessment of other dental hard tissues, functional elements, oral soft tissues, and lips, in addition to compliance with the patient's facial characteristics. Without these detailed evaluations, a satisfactory esthetic treatment outcome is neither possible nor desirable for both patient and dentist [3]. Patient–dentist communication is another important factor for the planned restorative treatment and satisfactory final outcome [4, 5]. Therefore, in esthetic treatments the assessment of the patient along with other variables, a detailed treatment plan and sequence, and, a restorative treatment procedure including communication with the patient and dental laboratory are important steps for success.

Patient assessment and initial consultation are important preliminary steps for both patient and clinician. In esthetic dentistry, multiple appointments are necessary to create optimal results leading to a satisfactory outcome [6].

In general, patients attend dental clinics for routine dental care, emergency therapies, and esthetic treatments. In esthetic dentistry, the expectations of patients and functional elements need to be evaluated comprehensively to obtain satisfactory results. Therefore, a detailed comprehensive evaluation of patients before initiation of any therapy is necessary. A roadmap of a comprehensive evaluation in esthetic dentistry is illustrated in Fig. 3.1.

For the initial visit of the patient, a private consultation room is advised, as this allows the meeting to take place in a quiet, personalized and relaxing environment in which the dentist can learn the desires, concerns, and expectations of the patient alongside the dental and medical history and determine the current situation [7]. This personal interview also lends credence to the patient's first impression of the clinician and clinical environment, and hence can create a positive clinician–patient relationship [6]. The collected data at this initial conversation are also mandatory for developing different treatment approaches for the subsequent course of treatment and ultimate outcome. During the second appointment, arranged to last much longer, the clinician should obtain specific information, perform examinations, and discuss the several possible treatment approaches with the patient. Sufficient time should be allotted at this stage to gather information and specific data on dental history, to perform diagnostic tests and to consult with medical specialists if necessary.

3.1 Medical History

For documenting the medical history of patients a standard, detailed history form should be completed at this stage to gather specific information to help identify any conditions that could contraindicate, complicate, or alter the treatment procedure [8]. With this detailed form, clinicians can obtain information on infections or systemic disease that may require specific prevention, prophylactic therapies, treatment modifications, and referral to medical specialists. Allergic reactions to drugs and restorative materials can contraindicate the restorative procedures, and physiological changes due to aging may affect the treatment plan. Besides such information, clinicians can also learn about the habits of the patients such as smoking, plaque control, and other pernicious habits (i.e., thumb sucking). Dietary habits of the patients also need to be recorded at this stage for both present and future restorative and oral care. Knowledge of previous dental visits and treatments is also essential for gathering information about past dental problems, previous conditions, and patient responses to procedures, to provide optimum oral care for future treatment plans [8]. In addition, a history of previous orthodontic therapy is important when planning the treatment because this may indicate the tendency of diastema to recur. All of this information must be documented scrupulously on the history form, to be used as needed.

3.2 Clinical Examination

After recording all necessary information on the history form, the next step should be detailed clinical evaluation of all determinants of the mouth such as periodontal condition, general tooth health, oral soft tissue, occlusion, and extraoral examination. As these patients are already seeking esthetic restorative treatment, a comprehensive clinical esthetic examination by listening sufficiently to the patient's desires and expectations is also mandatory for a satisfactory outcome [9].

3.3 Extraoral Examination

Although generally facial symmetry, lip position at rest and at smile, facial contours, and midline axis may not be major evaluation criteria in simple or routine restorative treatment procedures, all of these are important components of esthetic restorative procedures [7]. Determination of the harmonious function or dysfunction and all components of the stomatognathic system should be carefully evaluated step by step. For evaluation of the mandibular movement and switching limits, the clinician should be positioned at the 12 o'clock position (Fig. 3.2) to determine minor deviations during these motions. In addition, this position can allow the clinician to evaluate the pain response of the patient by pressing onto the capsule during the switching motion. Temporomandibular joint (TMJ) examination by palpation can also be performed at the 12 o'clock position (Fig. 3.3). Even in the absence of any significant symptom, it

Fig. 3.2 Evaluation of the patient from 12 o'clock position

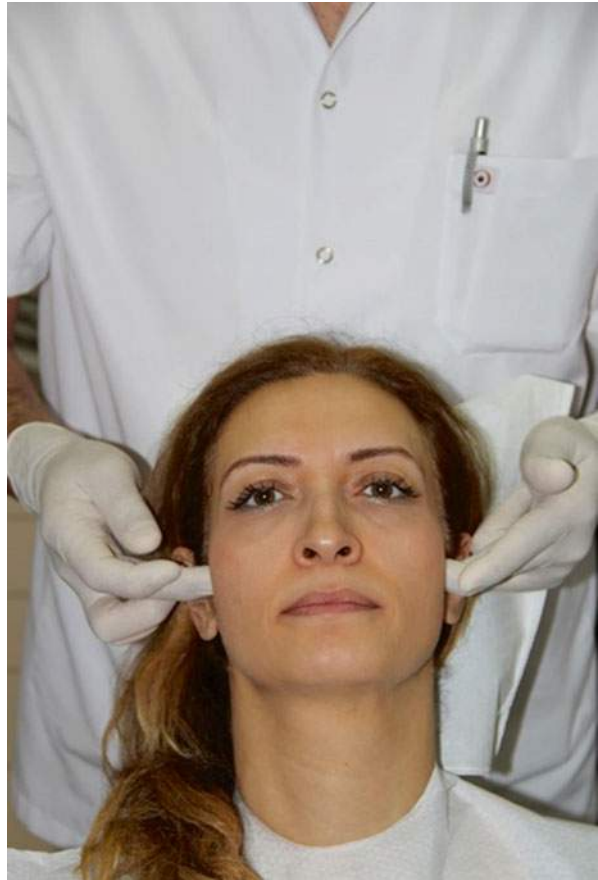
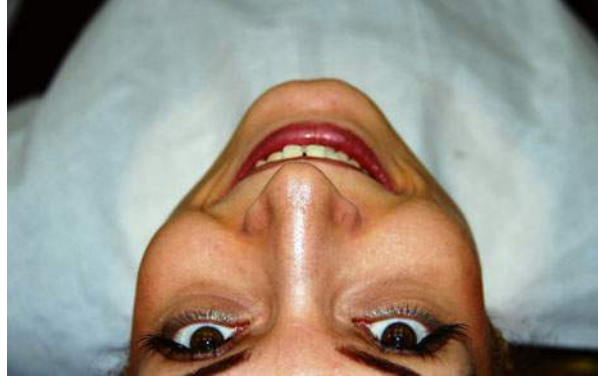
Fig. 3.3 Temporomandibular joint (TMJ) examination at 12 o'clock position by palpating onto the disks

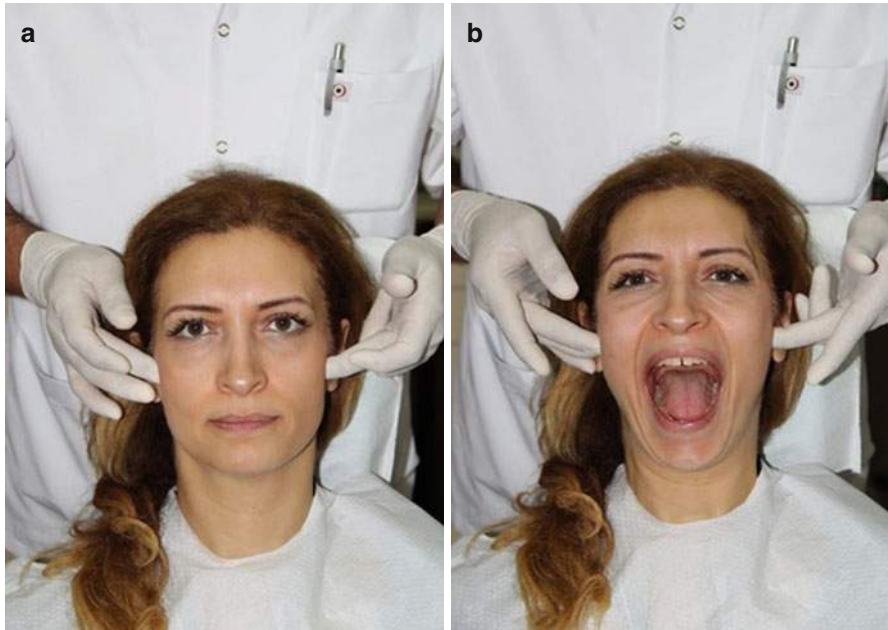


Fig. 3.4 Palpation of the TMJ (a) when mandible is closed and (b) mandible is opened widely

is important to record mandibular motion, switching limits, mastication, and the comfort of the patient during the extraoral evaluation of these movements [7, 10]. Significant TMJ changes (i.e., intracapsular) may occur with no symptoms, which could affect the long-term outcome of restoration and occlusion [10]. For this reason, early evaluation of the stomatognathic system with all its components is important. The information gathered at the initial conversation also allows a more helpful examination at this stage, as patients may report concerns with TMJ problems, rattling noise during chewing, headaches, or muscle tension [10]. Clicking noises can be due to a disk displacement [7, 11], and may require a detailed evaluation and physical therapy by a clinical expert in the field.

Key Note

Examination of all components of the stomatognathic system at the beginning is important for long-term stability and success.

Palpation of the TMJ can be done when the mandible is closed and opened widely (Fig. 3.4a, b). At the closed position of the mandible, one can evaluate the lateral pole and interrelated surrounding structures by palpating. When the mandible is widely opened, condylar movement occurs downward and forward throughout the articular eminence, and at this position the posterior part of the TMJ can be palpated [10]. During these palpations, patients with healthy structures generally should not feel any

pain or discomfort. Any discomfort or pain detected during the TMJ palpation could be due to dropsy or inflammation in those structures, probably caused by trauma such as bruxism, malocclusion, or any kind of facial accident history [10]. Evaluation of mandibular motion is another important criterion whereby maximum opening, lateral and protrusive movement of the mandible should be measured for consideration. In all these mandibular movements there should be no pain or discomfort, and if so it should be specifically detected through evaluating the motion while the patient is talking to specify the area of discomfort. These pains or discomforts may be TMJ induced, muscle related, or both. Normally, approximately a 50 mm opening and 10 mm excursive movements should be seen on mandibular motion [10]. Any deflection in these average limits detected during examination might suggest problems with the TMJ, especially with the capsular structures and muscles. Another important test that should be borne in mind for testing the TMJ is the superior compression test, whereby bimanual guidance is used to measure the load-bearing capacity of the TMJ [10] (Fig. 3.5). If pain and tension are apparent during this test, they probably arise in various forms from intracapsular or surrounding structures [10]. If the patient feels pain or tension during the superior compression test and points out a location in the TMJ area, this generally indicates intracapsular problems [10]. If tension is reported by the patient during the bimanual superior compression test, this may suggest hypercontraction of the lateral pterygoid muscles [10], which pulls pterygoids down and forward through the articular eminence. If sensitivity is reported by the patient during the bimanual compression test, this would indicate inflammation or dropsy in the capsular area [10]. Besides palpation, clinicians can also use auscultation devices such as ultrasonography to detect the current condition and any TMJ problems [10]. A step-by-step evaluation chart for all the components of the TMJ can be helpful for acquiring the necessary information to be kept for future consultation when needed. When these signs or conditions are detected by either palpation or auscultation during the extra-oral examination of the patient, it must be definitively treated before any restorative treatment procedure to achieve a long-term satisfactory result.

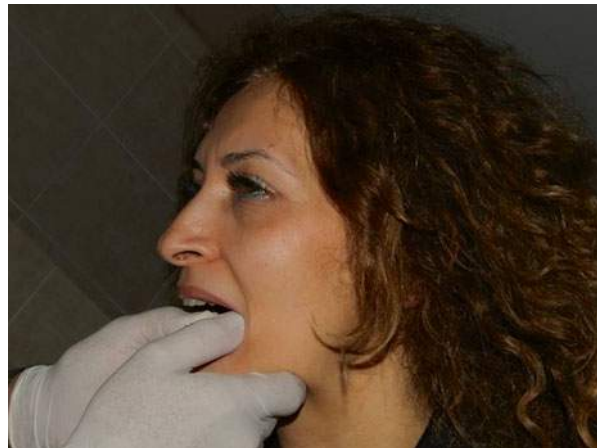

Fig. 3.5 Load-bearing capacity examination of the TMJ using bimanual guidance

3.4 Examination of Muscles

Testing the masticatory muscles is another important extraoral examination, for which various kinds of muscle examination such as palpation, the patient's own statement during function, and provocation tests are available [10]. While palpating, normally healthy and well-functioning muscle should not exhibit any hypertrophy, sign, or pain during examination. Any discomfort or pain detected on palpation would suggest that muscle is in hypercondition or hypertrophy. A variety of reasons can provoke muscle discomfort or pain, such as a pathological condition (e.g., atypical facial pain, migraine), parafunctional conditions (clenching, grinding, bruxism), and musculoskeletal disorders [7, 10]. Occlusal instability and bruxism can provoke muscle discomfort during function especially on the excursive movement of the posterior teeth, and hence creates pain by hyperactivating the elevator muscles [10, 12, 13]. In general, extraoral muscles are evaluated first, followed by the intraoral muscles. During extraoral examination the masseter muscle, temporalis muscles, occipital muscle, sternocleidomastoid muscles, medial pterygoid muscle, and digastric muscles should be palpated in sequence [7, 10]. When palpating these muscles, the patient is asked to point out exactly where a pain or discomfort occurs. The masseter and temporalis muscles are examined by palpation primarily at rest (Fig. 3.6a, b); the patient is then asked to clench the jaw (Fig. 3.7a, b) to allow evaluation of any differences detected between these palpations such as hardness on these

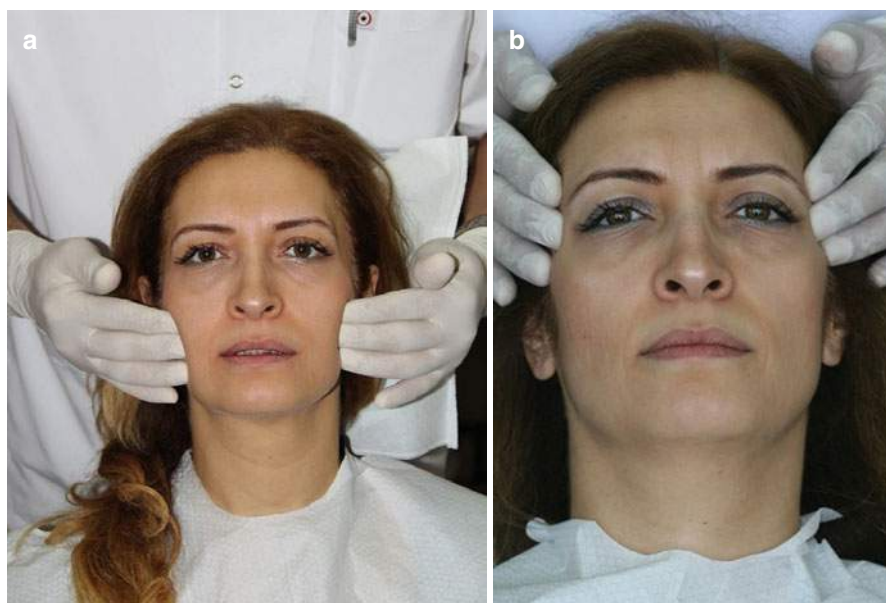


Fig. 3.6 (a) Palpation of masseter muscle at rest. (b) Palpation of the anterior temporalis at rest

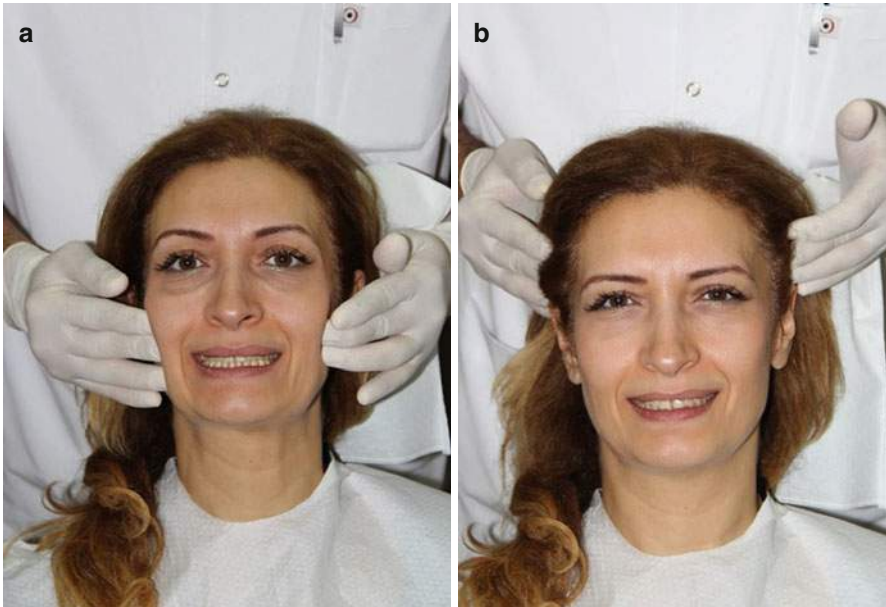


Fig. 3.7 (a) Palpation of masseter muscle while clenching. (b) Palpation of the anterior temporalis muscle while clenching

muscles during this function [7, 14]. If any differences are detected during the evaluation, the patient is asked about any parafunctional habits such as night-time bruxism, clenching, or any history of chronic headache [7]. Painful response or discomfort of patients during palpation of these muscles may also contribute to non-dental problems such as migraines and atypical facial pain; hence, a true-positive evaluation is mandatory [7]. During examination of occipital muscles (Fig. 3.8), if the patient gives a positive response to palpation this may signify a possible cervical component problem related to the discomfort, and before initiation of any restorative procedure the patient must be referred to a specialist for a full evaluation of TMJ and cervical muscle [7, 15]. When evaluating the sternocleidomastoid muscle by palpation (Fig. 3.9), the patient may refer to pain at the masseter and TMJ areas; in this case a detailed careful examination of all areas should be carried out [7]. In addition to the extraoral examination, an intraoral examination of medial pterygoid muscles (Fig. 3.10), the reference area of which is pterygomandibular groove, is important. If the patient reports any discomfort or sensitivity during palpation of this muscle, it may generally be related to posterior excursive interference [10]. The lateral pterygoid (Fig. 3.11) is another important muscle that is difficult to examine directly intraorally, owing to its anatomical location [7, 10]. Positioning in front of the patient, the clinician places his or her thumbs on the tip of the chin and asks the patient to move the mandible forward. During this motion more resistance will be generated by the thumb and the patient may feel discomfort or pain

Fig. 3.8 Palpation of occipital muscle

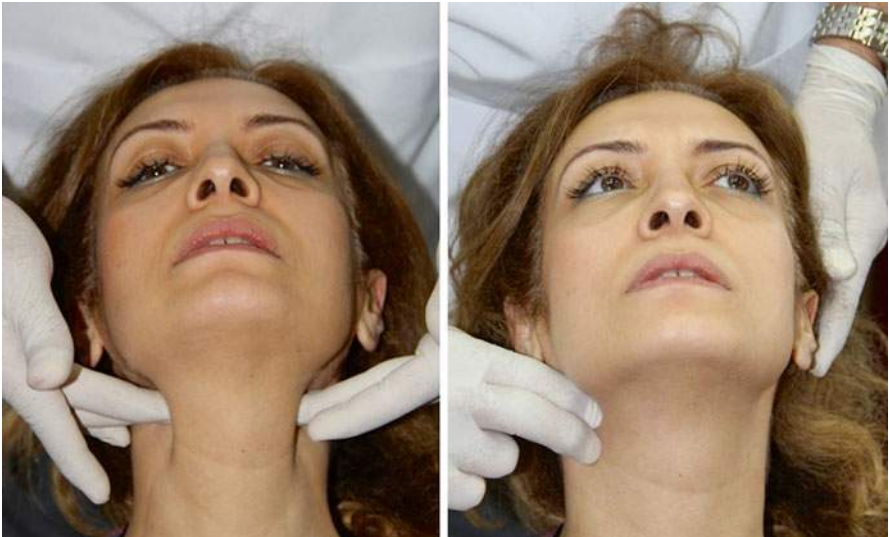
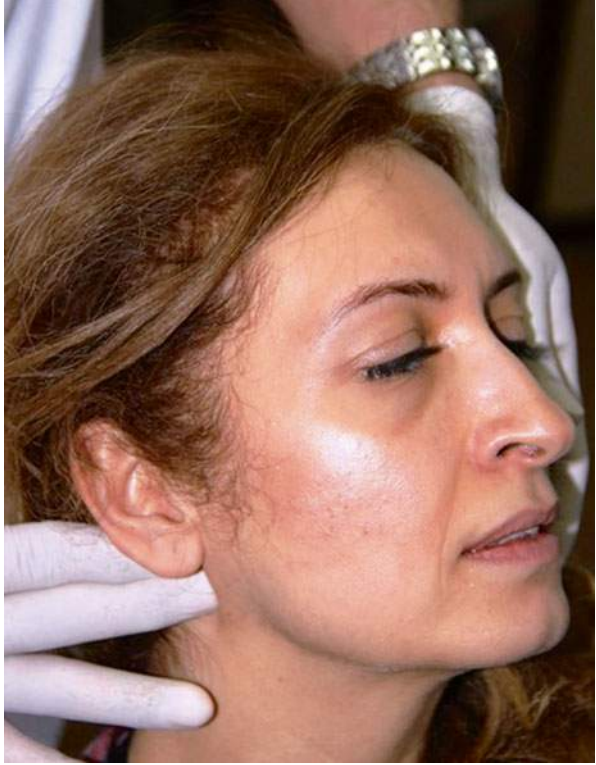
Fig. 3.9 Palpation of sternocleidomastoid muscle

Fig. 3.10 Palpation of medial pterygoid muscle

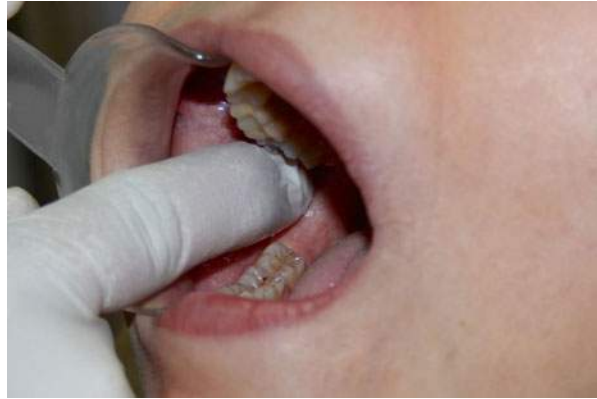
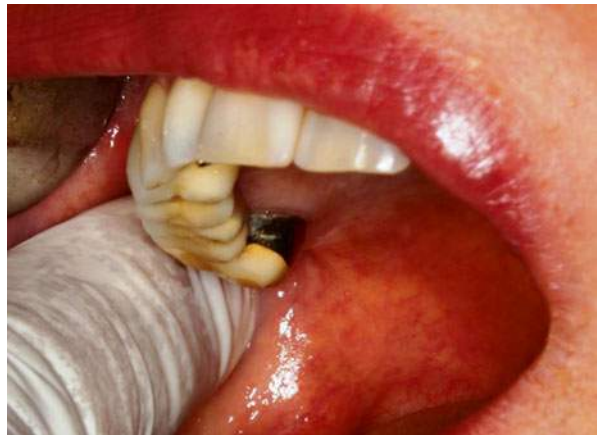
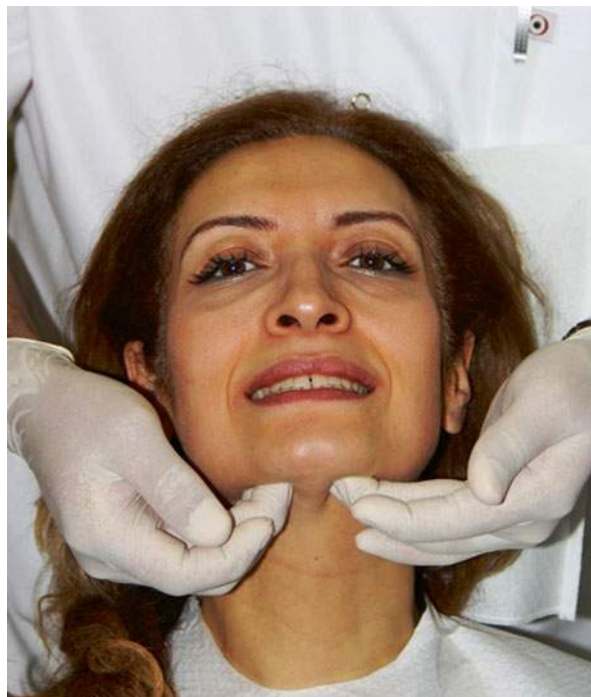Fig. 3.11 Palpation of lateral pterygoid area on the superior maxillary tuberosity



if there is a problem with the muscle at the anterior region of the condyle [10]. However, it must be borne in mind that due to the extended time period afforded by this examination, lactic acid can be deposited into the muscle even in healthy mouths, and may become painful for the patient [10]. Lastly, during palpation of the digastric muscle (Fig. 3.12) which is predominantly responsible for the opening of the mouth, patients will usually report pain or discomfort if there is any dysfunction of the muscle [7, 16]. In general, healthy muscles do not generate any pain and discomfort during palpation [17]. The importance of muscle examination to both the restorative treatment procedure and the restorations must be clearly explained to the patient. If there are any signs of discomfort or pain during the muscle examination or via self-reporting by the patient, esthetic restorative treatment should be postponed until full TMJ and muscle therapy is completed by an expert in the field [7].

Fig. 3.12 Palpation of digastric muscles



When all TMJ and muscle examinations are completed, mandibular movement values such as maximal opening and lateral and protrusive excursion should be determined and recorded [7]. Because all of these movements are important for the TMJ, the muscles, the comfort of patients, and long-term success, various tools should be used to meticulously record the relevant measurements. Several devices are available for determination of the range of motion of the mandible, such as a millimeter ruler, calipers or compasses, and therabite appliances [7]. Under normal conditions, the maximal opening range for the mandible specifically the vertical interincisal distance between the maxillary and mandibular anterior teeth is 45–50 mm for adults, whereas the measurements varies from person to person [7]. If an open-bite situation exists, a true measurement should be specified as the distance between the incisal edges, while the closed mandible distance should be subtracted from the incisal edge distance at maximal opening [7]. For evaluation of the lateral and protrusive excursion of the mandible, the lateral and protrusive movement must be approximately in the range of 9–15 mm. In addition, all of these mandible motions should be done under normal conditions without any reports or signs of discomfort from the patient [7]. After the entire extraoral examination is complete, intraoral examination involving dental status, periodontal status, periapical condition, occlusion, and esthetic analysis should take place. The order of the intraoral examinations is not important; the crucial point is to perform these examinations in detail and with sufficient time allowed.

3.5 Intraoral Examination

For intraoral examination, the clinician employs the patient's charts and medical records and performs a tooth-by-tooth examination for the analysis of the limitation of restoration, in addition to a complete functional and esthetic evaluation [9]. In general, there is no need to evaluate the teeth alignment for routine dental treatment; however, for esthetic procedures the clinician should also evaluate teeth alignment, tooth-tooth relationships, and tooth-gingival relationships. Sometimes it is impossible to visually evaluate the tooth surface clearly because of saliva, bacterial plaque, stains, and food deposits. For this reason, the use of an air syringe to remove saliva and food deposits, or professional tooth cleaning to remove calculus and extrinsic stains before examination of the teeth (Fig. 3.13). In addition, the use of magnifier tools (i.e., $\times 2.5$ or greater loops) are necessary when evaluating the teeth for caries lesions, defective restorations, and other kinds of defects in dentition [7, 9]. At this stage, the use of an intraoral camera or professional digital photographs (Fig. 3.14) of the dentition may also be beneficial, especially to allow the patient to see the current situation regarding dentition and more readily understand the future recommendations for treatment. In addition, as these digital devices have the capability to

Fig. 3.13 Professional tooth cleaning for removal of extrinsic stains before the examination of teeth

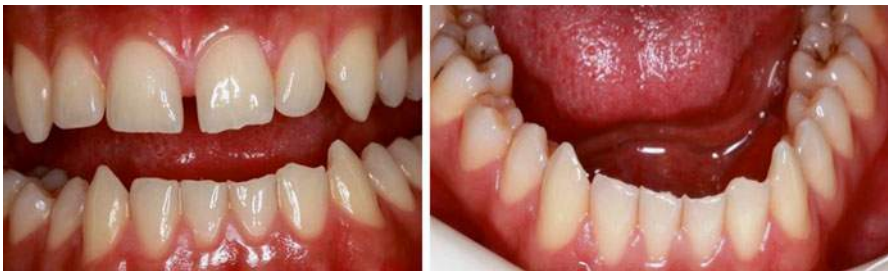
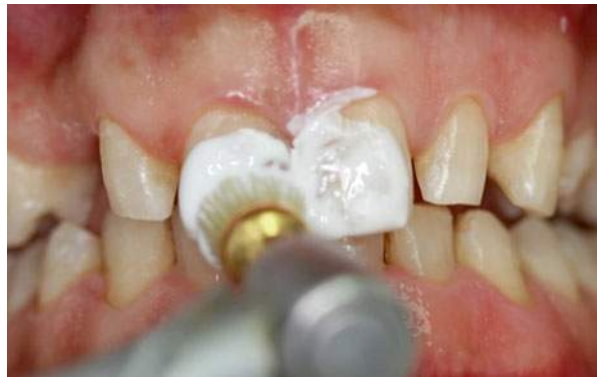
Fig. 3.14 Obtaining digital photographs helps the clinician to see the current situation of dentition and helps in formulating future recommendations on treatment

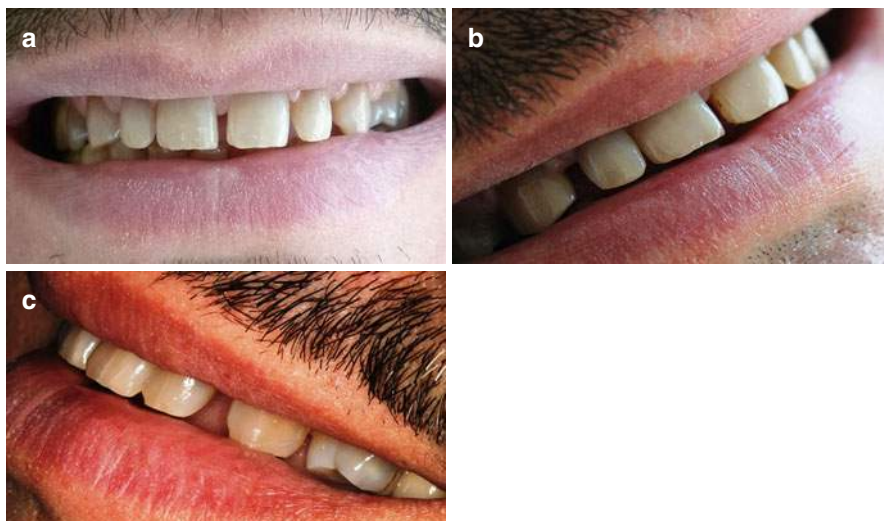


Fig. 3.15 Obtaining a series of photographs from different directions (**a** frontal; **b**, **c** lateral) for visualization of dentition and communicating with the laboratory regarding the situation

record the tooth surface, they may also allow the clinician to clearly visualize the tooth surface for cracks and hidden caries that may be sometimes overlooked during visual clinical examination or by a dental explorer. A series of photographs taken from different directions (Fig. 3.15a–c) not only helps visualization by the clinician and patient but is also helpful in communicating the situation to the laboratory. The clinician should also consider mechanical and/or chemical tooth defects such as erosion, abrasion, and attrition, since such defects can cause facial, occlusal/incisal, and palatal surface damage, and hence decrease the occlusion. All the critical points need to be recorded precisely at this stage, either on forms or digitally by photographs, for use in the later phases of the clinical plan.

To maintain a harmonious teeth relationships for a satisfactory outcome, both vertically and horizontally arch integrity regarding the tooth-to-tooth relationship should be considered as a part of intraoral examination.

3.6 Periodontal Examination

After the dental examination is complete, the periodontal status of the patient should be critically examined. In this step, digital photographs are also important for evaluation of the gingival levels, symmetry or asymmetry, gingival embrasures, and esthetics of the gingival tissue [10]. Clinical examination should be performed by a straight, calibrated, blunt periodontal probe (Fig. 3.16) to evaluate the bone support, any furcation defects, gingival bleeding, gingival recession, periodontal pockets, plaque, calculus, and mobility of a tooth [7, 9, 10]. A problem at any of these points will have a major influence on the function and esthetic characteristics of the final

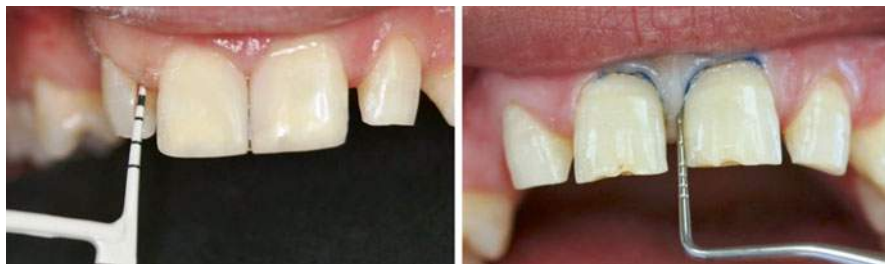

Fig. 3.16 Periodontal examination of the gingival structures using different blunt-edged periodontal probes

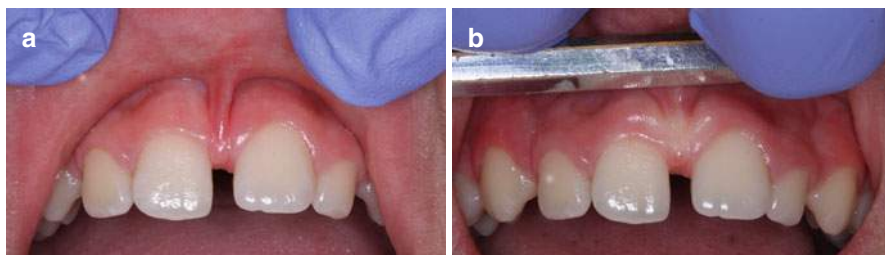


Fig. 3.17 (a, b) Blanching test

restoration; therefore, a comprehensive periodontal evaluation is imperative in esthetic restorative procedure. The clinician should carry out soft-tissue management in collaboration with a periodontologist, and sometimes with an orthodontist, before initiation of any esthetic therapy if required.

3.7 Examination of Labial Frenum

A deep labial frenum attachment may cause maxillary midline diastema. The differential diagnosis of abnormal maxillary labial frenum is important, since it determines the necessity of a frenectomy. In general, an abnormal frenum attachment can be directly visualized during intraoral examination. The clinician should check the blanching of interdental gingival tissue (blanching test) when the upper lip is lifted and the frenum is pulled (Fig. 3.17a, b). This can also be verified radiographically by detecting a significant bony fissure between the central incisors (see Chap. 2).

3.8 Examination of the Tongue

In cases of diastema, evaluation of the tongue is a step that must not be skipped because it may offer insight into the etiology of the malocclusion. If the etiological factor is the tongue, this will highly determine the treatment approach. In this case, reduction of the

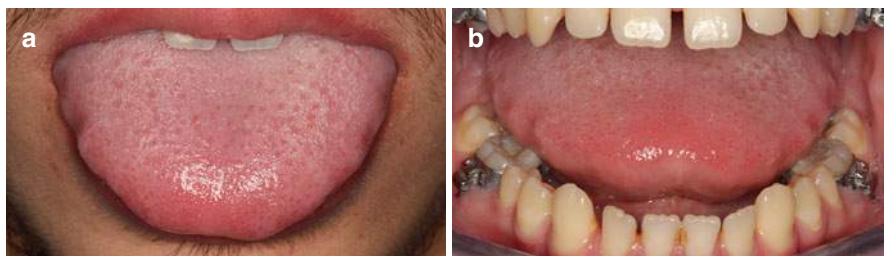


Fig. 3.18 (a, b) Indentations (imprints of the dentition) on the lateral borders of the tongue in a case of generalized spacing

available space of the tongue by retraction of the incisors should be avoided. The shape, size, and function of the tongue should be carefully evaluated. The presence of indentations on the lateral borders of the tongue may indicate macroglossia or a restricted oral cavity (Fig. 3.18a, b). The differential diagnosis of macroglossia is difficult because it is not always possible to evaluate its true size and adaptation capability to the space available in the oral cavity [18]. However, in syndromic cases it is easy to diagnose, as the resting tongue protrudes beyond the teeth [19, 20].

The position of the tongue at rest must be observed while the patient is unaware of what the dentist is examining [21]. The subject is instructed to calmly and slowly open the mouth to such an extent that the clinician can see the tongue position. In addition, tongue functions during swallowing and speaking should be attentively examined to detect tongue thrusting. Lingual frenum attachment deserves attention because a tight lingual frenum may restrict tongue movements and cause anterior positioning of the tongue against the incisors. The patient is told to contact the tip of the tongue to the palate while the mouth is wide open. When the lingual frenum is tight, the tip of the tongue cannot touch the palate.

3.9 Radiographic Evaluation

During intraoral examination, the clinician should also evaluate the teeth by percussion on different directions for any sign or symptom of periapical pathology [22]. If any sign or pain is detected during the percussion, an electrical or thermal vitality test can be conducted. If the clinician suspects any periapical pathology for a tooth or dentition, full-mouth periapical radiography should be added to the clinical examination. To protect the patient from radiation, technological radiographs such as radiovisiography can be used, as this technique performs the same function as traditional radiography but with approximately 80–90 % less radiation. Panoramic radiography can also be useful for evaluation, but the sensitivity of this technique is less than that of periapical. For interdisciplinary treatment including orthodontics, lateral cephalometric radiographs are required to evaluate skeletal relationships, incisor inclinations, lip positions, and overall soft-tissue facial profile. If necessary, other types of imaging such as computed tomography

and magnetic resonance imaging can be helpful for soft- and hard-tissue evaluation, depending on the situation [10].

3.10 Examination of Occlusion

It is obviously necessary to control and record patient occlusion in both esthetic and any other restorative treatment procedure for long-term success and comfort (Fig. 3.19a, b). The primary reason for documenting these data is to identify the current condition and any interference, and form a relevant approach for future workup [7]. The overjet, overbite, amount and localization of the diastema, crowding, and maxillary and mandibular relationships, both transversal and sagittal, should be examined. Properly obtained dental casts will help visualization of the interarch and tooth-to-tooth relationships, and can easily show the current condition, since it is difficult to evaluate patients by employing only visual examination (Fig. 3.20). Dental casts are also useful for performing tooth–arch size analysis

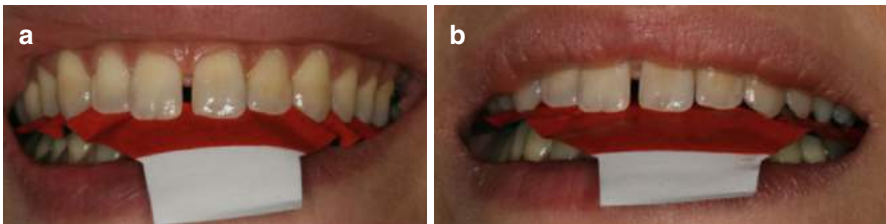


Fig. 3.19 (a) Centric occlusion control. (b) Lateral excursion control with articulating paper

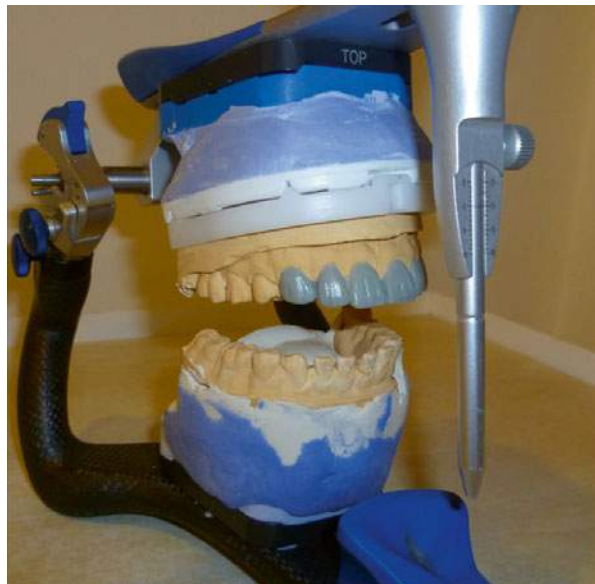

Fig. 3.20 Analyzing and visualizing interarch and tooth-to-tooth relationships on study models mounted on an articulator

(see Chap. 8) and wax setups (see Chap. 4). The obtained cast can be mounted on an articulator by way of a correctly recorded centric relation, and the articulator can properly aid the clinician in identifying the required interocclusal relationships of the patient. A properly obtained bite record from the patient with the aid of articulating paper can help the clinician to compare the initial tooth contacts in centric occlusion with that of the articulator (Fig. 3.21a, b), and hence aid the precision of obtained records [7]. In addition, the clinician can also control the patient's lateral and protrusive motion on the articulator, and document these motions on the dental health record for esthetic restorative treatments [7] (Fig. 3.22a, b). These determinations can affect the design of the final restoration and restorative treatment procedure. Clinically the clinician should also evaluate the current occlusal pattern in the patient and record whether the occlusion pattern is canine or anterior guidance. During the evaluation of the occlusion pattern, the clinician should bear in mind that interrelationships between the lower and upper teeth for working and nonworking side relationships can suggest a restorative

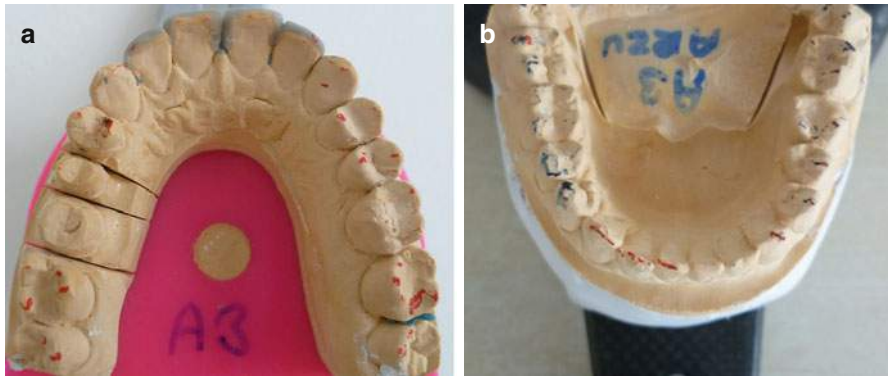


Fig. 3.21 (a, b) Analyzing initial tooth contacts in centric occlusion with study models mounted on an articulator

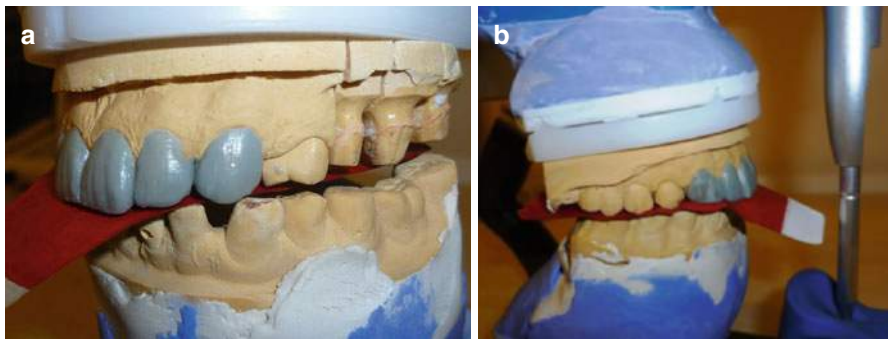


Fig. 3.22 Controlling the lateral motions on the articulator. (a) Left lateral motion of the mandible. (b) Right lateral motion of the mandible. Note: visible tooth contact during right lateral motion of the mandible (see right upper canine wax-up)

approach in accordance with the current occlusal pattern. In addition, as previously described during lateral and protrusive motion of the mandible, the patient must perform these movements with comfort and without any signs or symptoms. During lateral excursion, the patient is asked whether there are any contacting or inhibiting points this movement and if there are signs of discomfort on the teeth, muscles, and TMJ. It should be borne in mind that occlusal interferences or primary occlusal contacts may be a reason for several problems (e.g., TMJ, muscles, teeth, periodontal) (Fig. 3.23). Evaluation of patient occlusion and interference can also be recorded and analyzed by computerized systems. T-Scan is a sensor-based computerized system that identifies the occlusal contacts on the basis of the first contact tooth to maximal intercuspitation, forces, and timing for these contacts [9]. By using this computerized system, both clinician and patient can see on the

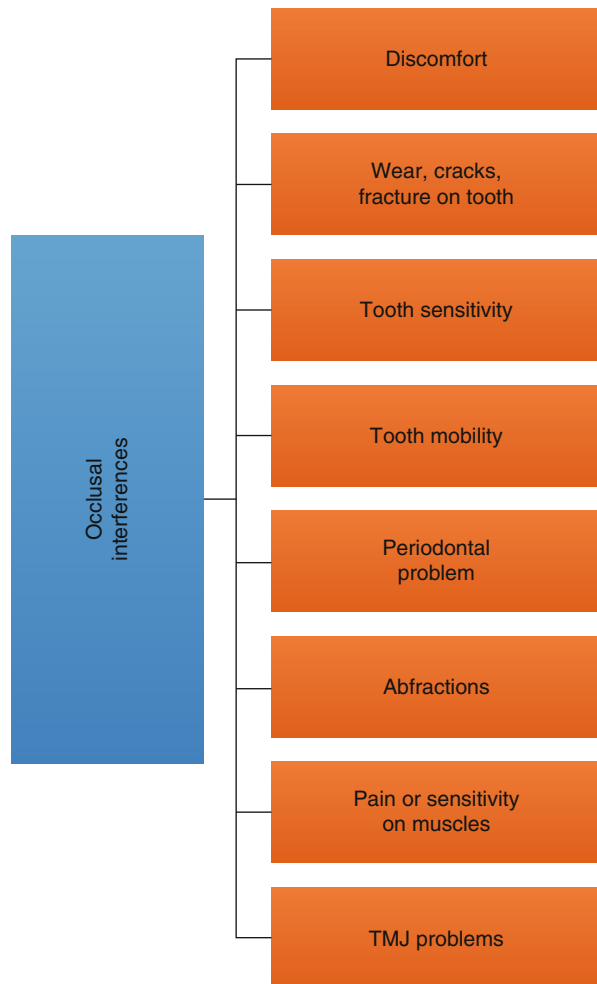


Fig. 3.23 Associated factors/problems for occlusal interference (Modified from Tarantola [10])

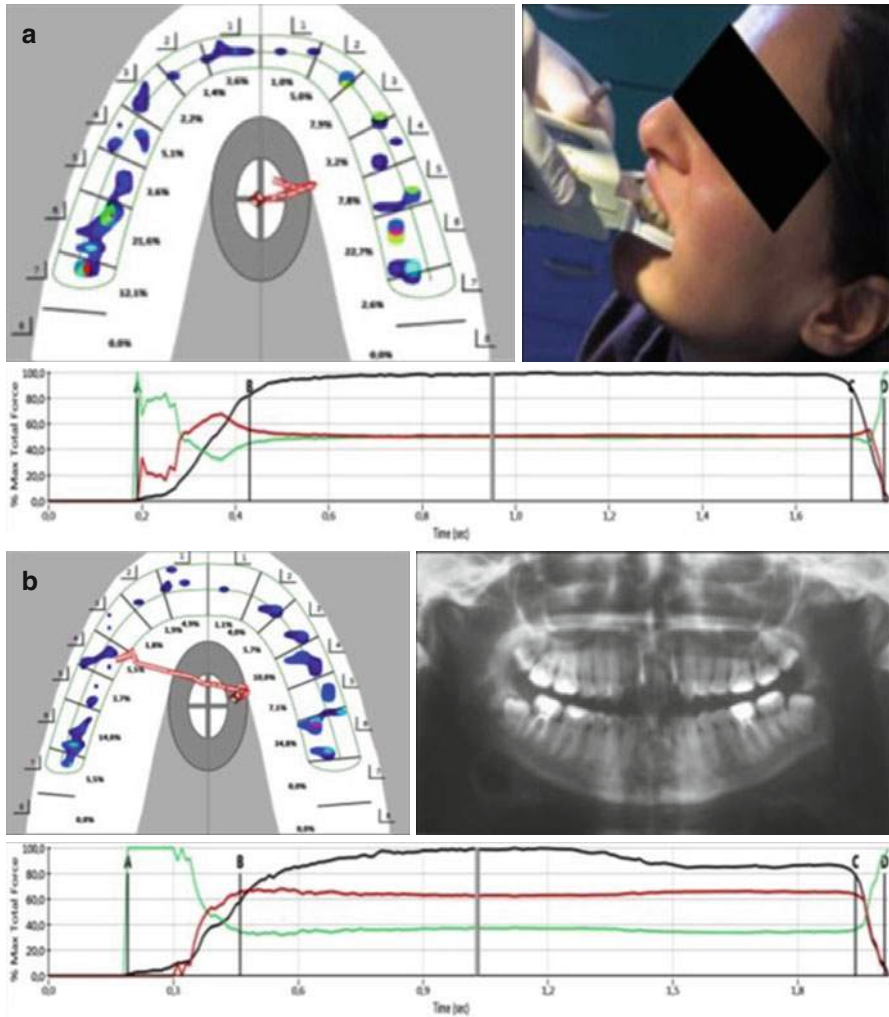


Fig. 3.24 Evaluation of patient occlusion and interference can also be recorded and analyzed by a T-Scan computerized system. (a) Patient representing an amalgam restoration on tooth 17, which has an early contact. (b) After selective grinding with a fine diamond bur, primary occlusal contact is rehabilitated (Courtesy of Dr Serdar Gözler)

screen the primary occlusal contact and trauma areas [9] in a diagram as red colored, so that the clinician can make adjustments by selective grinding with a fine diamond bur on the suspected tooth to correct the primary occlusal contact (Fig. 3.24). This system can also allow patients to more easily understand the current problem in comparison with traditional occlusion analysis, and make them more receptive to various treatment options through conversation [10]. This practical evaluation allows raising awareness and understanding the problem beside analysing the occlusal contacts, at the time of examination.

Key Note

Analysis and control of the occlusion are obviously necessary, not only in esthetic dentistry but also in any other restorative treatment procedure, for long-term function, successful restorations, and patient comfort.

3.11 Esthetic Evaluation

The esthetic considerations will be evaluated in detail in Chaps. 5, 6, 7, and 8, but the goal of this chapter is to outline the gathering of necessary information on esthetic parameters during the initial examination phase to help clinicians develop an esthetic treatment plan. Nowadays, esthetics is a critical part of and has an important role in all esthetic restorative procedures, and patients seek more conservative and esthetically pleasing restorative treatments. In esthetic dentistry, planned restorations need to be functional, biocompatible with the soft tissue, and esthetically pleasing for patients. Therefore, clinicians should plan a restorative treatment for each individual patient that serves these goals accordingly [10]. During the esthetic evaluation, firstly the clinician must know the patient's desires, expectations, and needs. Thereafter, in accordance with the gathered information as previously described, a direct or indirect treatment plan is developed to achieve the esthetic expectations of the patient [10]. At this stage the clinician should pay attention to the midline, smile line, gingival exposure at rest and smile, tooth-to-tooth relationships, tooth–soft tissue relationships, and relationships of teeth with the lips and face of the patients on the esthetic reconstruction area, and how the planned restoration will fit on this framework [10]. For a definitive restoration, previously obtained photographs, diagnostic casts, and occlusion analysis records will assist the clinician by providing important details on the final restoration and relationships with the surrounding soft and hard tissue, as well as the patient's lips and face. Bringing together all these records and analyses will create esthetic and functional restorations that are in harmony, in good occlusion, balanced with the TMJ and supporting muscles.

References

1. Huang WJ, Creath CJ. The midline diastema: a review of its etiology and treatment. *Pediatr Dent.* 1995;17(3):171–9.
2. Chu CH, Zhang CF, Jin LJ. Treating a maxillary midline diastema in adult patients: a general dentist's perspective. *J Am Dent Assoc.* 2011;142(11):1258–64.
3. Italian Academy of Conservative Dentistry. *Restorative dentistry.* 1st ed. St. Louis: Elsevier Mosby; 2012. p. 3–48.
4. Goldstein RE. Communicating esthetics. *N Y State Dent J.* 1985;51(8):477–9.
5. Almog D, Sanchez Marin C, Proskin HM, Cohen MJ, Kyrkanides S, Malmstrom H. The effect of esthetic consultation methods on acceptance of diastema-closure treatment plan: a pilot study. *J Am Dent Assoc.* 2004;135(7):875–81.

6. Ahmad I. *Protocols for predictable aesthetic dental restorations*. Oxford, UK: Blackwell Munksgaard; 2006. p. 1–16.
7. Santucci E, Santusci N. The initial patient examination. In: *Esthetic dentistry in clinical practice*. 1st ed. Ames: Wiley-Blackwell; 2010. p. 29–41.
8. Heymann HO, Swift Jr EJ, Ritter AV. *Sturdevant's art and science of operative dentistry*. 6th ed. St. Louis: Elsevier Mosby; 2013. p. 89–112.
9. Goldstein RE. *Esthetics in dentistry*. 2nd ed. Hamilton: B.C. Decker Inc.; 1998. p. 17–49.
10. Tarantola GJ. *Clinical cases in restorative and reconstructive dentistry*. 1st ed. Ames: Wiley-Blackwell; 2010. p. 5–25.
11. Yatani H, Suzuki K, Kuboki T, Matsuka Y, Maekawa K, Yamashita A. The validity of clinical examination for diagnosing anterior disk displacement without reduction. *Oral Surg Oral Med Oral Pathol Oral Radiol Endod*. 1998;85(6):654–60.
12. Gibbs CH, Mahan PE, Wilkinson TM, Mauderli A. EMG activity of the superior belly of the lateral pterygoid muscle in relation to other jaw muscles. *J Prosthet Dent*. 1984;51(5):691–702.
13. Manns A, Chan C, Miralles R. Influence of group function and canine guidance on electromyographic activity of elevator muscles. *J Prosthet Dent*. 1987;57(4):494–501.
14. Schindler HJ, Rues S, Turp JC, Schweizerhof K, Lenz J. Activity patterns of the masticatory muscles during feedback – controlled simulated clenching activities. *Cranio*. 2007;25(3):193–9.
15. Wright EF. Referred craniofacial pain patterns in patients with temporomandibular disorder. *J Am Dent Assoc*. 2000;131(9):1307–15.
16. Koolstra JH, van Eijden TM. The jaw open-close movements predicted by biomechanical modelling. *J Biomech*. 1997;30(9):943–50.
17. Okeson JP. *Management of temporomandibular disorders and occlusion*. 6th ed. St. Louis: Elsevier Mosby; 2008. p. 216–84.
18. Attia Y. Midline diastemas: closure and stability. *Angle Orthod*. 1993;63:209–12.
19. Kadouch DJM, Maas SM, Dubois L, van der Horst CMAM. Surgical treatment of macroglossia in patients with Beckwith-Wiedemann Syndrome: a 20-year experience and review of the literature. *Int J Oral Maxillofac Surg*. 2012;41:300–8.
20. Vogel JE, Mulliken JB, Kaban LB. Macroglossia: a review of the condition and a new classification. *Plast Reconstr Surg*. 1986;78:715–23.
21. Wright CR. Evaluation of the factors necessary to develop stability in mandibular dentures. *J Prosthet Dent*. 1966;16:414–30.
22. Okeson JP. *Bell's orofacial pains: the clinical management of orofacial pain*. 6th ed. Chicago: Quintessence Publishing Co, Inc.; 2005.

Taner Yucel, Esra Yildiz, Ugur Erdemir,
Derya Germec Cakan, and Korkmaz Sayinsu

Abstract

During the diagnostic process, all the information gathered at the initial conversation with the patient must be clearly brought together like pieces of a puzzle, allowing the clinician to set up a diagnosis schedule using all of the relevant data. At the next appointment, the clinician can use various effective tools to show the expected result to their patients, such as diagnostic wax models, computer-based smile design programs, or a composite mock-up taken from the patient's teeth during the clinical appointment. In addition, a diagnostic setup is needed for orthodontic-restorative diastema cases with microdontia or hypodontia, to guide both the orthodontist and restorative dentist in treatment planning and repositioning of the teeth to correct the malocclusion.

After completing the initial consultation phase and obtaining the required information, the clinician's next step is the diagnosis and treatment planning to share with the patient. A separate appointment is needed to discuss different treatment options for an esthetically pleasing outcome. Thus, the patient must be included in the decision-making process of diagnosis, treatment plan and treatment options leading to the desired expectation and satisfactory outcome [1, 2]. Information

T. Yucel, PhD, DDS (✉) • E. Yildiz, PhD, DDS • U. Erdemir, PhD, DDS
Operative Dentistry, University of Istanbul Faculty of Dentistry, Istanbul, Turkey
e-mail: t_yucel@superonline.com

D. Germec Cakan, DDS, PhD
Orthodontics, Yeditepe University, Dental Faculty, Istanbul, Turkey

K. Sayinsu, DDS, PhD
Orthodontics, Private Practice, Istanbul, Turkey

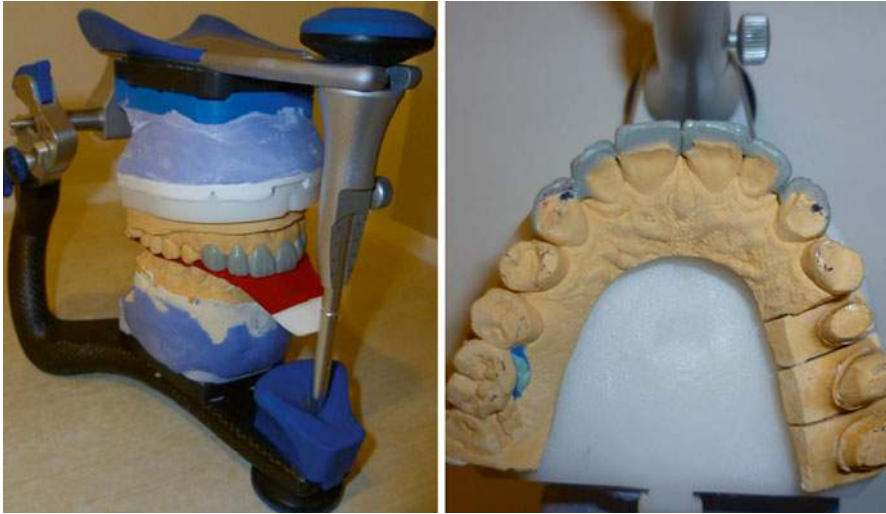

Fig. 4.1 Control of the occlusion with diagnostic wax-up model to observe current occlusal pattern on the articulator

gathered during the initial conversation must be brought together with all other relevant data to allow the clinician to set up a diagnostic process comprising a primary treatment plan and recommendations for the restorative treatment protocol [3]. At the subsequent appointment, the clinician has the opportunity and time to suggest esthetically pleasing results by using a diagnostic wax setup (wax-up), computer-based smile design programs, or a composite intraoral mock-up to effectively show the expected result. Diagnostic models are also useful for analyzing patient's occlusion with a wax-up and give an opportunity to observe the current occlusal pattern on an articulator (Fig. 4.1). Digital photographs obtained from different directions enable the clinician to see the condition more precisely and make a complete diagnosis [4] (Fig. 4.2). In addition, these photographs can be transferred to a monitor screen to allow the patient to clearly visualize the condition and help to understand the proposed direct or indirect treatment options. The main objective of esthetic dentistry is to create a biomimetic restoration that mimics tooth structure and is biologically compatible with the surrounding soft tissues. A comprehensive multidisciplinary approach with periodontal, orthodontic, and restorative dentistry is required to successfully create a natural-appearing restoration in a complex situation [5]. This comprehensive multidisciplinary diagnostic approach with patient involvement allows the clinician to successfully plan the case with respect to the esthetic and biological requirements and needs of the individual. It has been stated that common failures in esthetic dentistry are due to not only technical procedures but also communication problems between clinicians, patients [6], and the laboratory. For this reason, before initiation of any definitive esthetic restorative treatment, it is strongly recommended that clinicians enable patients to see planned restorative treatment results, including limitations

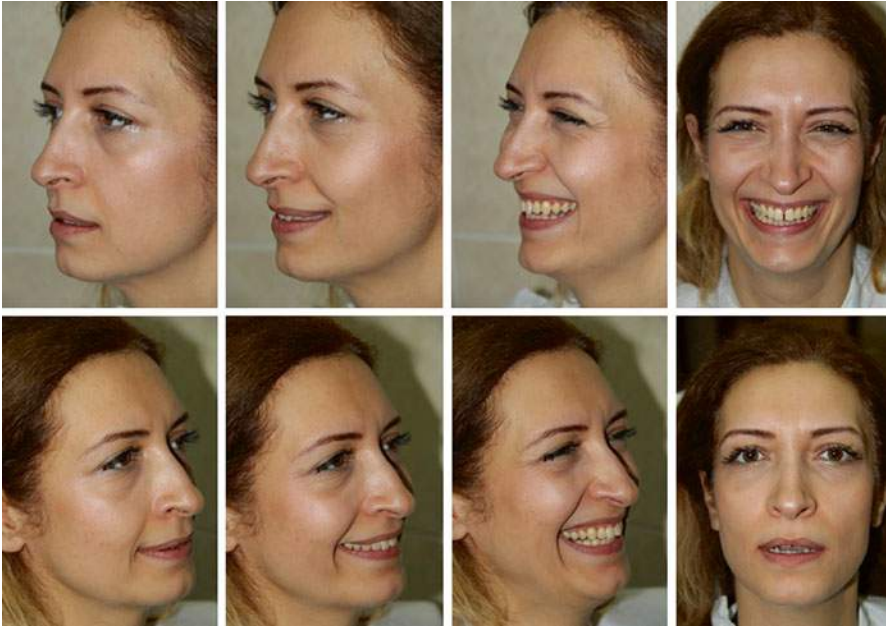

Fig. 4.2 Capturing extraoral digital photographs of the patient from different directions for appropriate diagnosis of the situation

of the procedure, and allow them to fully understand the projected restoration. Communication with patients and their involvement in the treatment planning is invaluable for a satisfactory treatment outcome [6]. Interdisciplinary discussion and communication with the other clinicians regarding patients' desires and expectation is also an important part of esthetic diagnosis and treatment planning [1]. During the diagnostic wax-up and photographic evaluation in the clinical environment, the clinician divulges to the patient the findings of the initial consultation and clearly describes the treatment options available in accordance with the situation. In this way the patient can clearly understand the proposed restorative treatment model and the limitations of the desired esthetic results [1]. To finalize the diagnosis, the treatment options, plan, and sequence, study models, and photographs must be evaluated also by the patient, and then the clinician can analyze each aspect in more detail to create a harmonious, natural, functional, and esthetically pleasing restoration [4].

For creation of an esthetically pleasing final restorative treatment, the clinician should also consider the patient's age, personality, and sex, and develop a bioesthetic procedure in accordance with these criteria [1]. Several diagnostic techniques are currently used by clinicians to create an optimal outcome and patient understanding for the recommended treatment plan as previously described, such as diagnostic wax-ups, direct mock-up with resin composites, computer-based digital imaging techniques, and before-after photographs of other patients [1, 2, 5, 7].

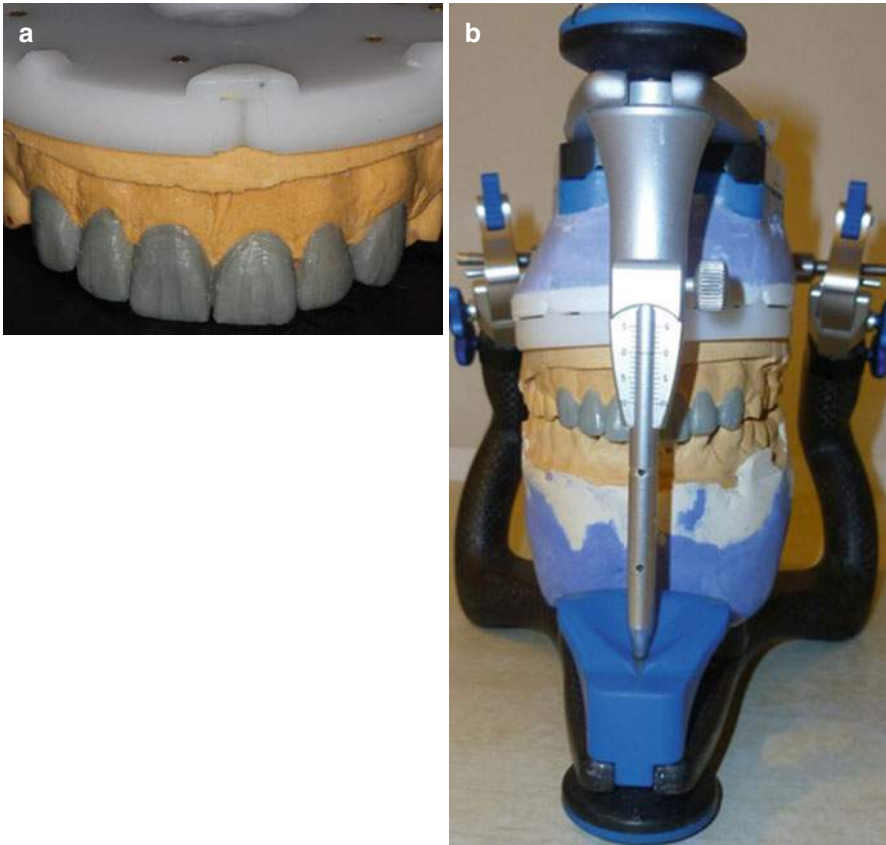


Fig. 4.3 (a) Laboratory-prepared diagnostic model with wax application. (b) Mounted on the articulator for occlusion analysis with the wax-up

Diagnostic models with the application of wax by modifying the size and shape of the teeth on a plaster model are useful tools for evaluating the current condition, restoration design, occlusion, and expected esthetic outcome in the spaced anterior region, even in simple cases [2] (Fig. 4.3a, b). A diagnostic plaster model with the wax-up is one of the best tools for esthetic diagnosis of a spaced dentition and for consultation with the patient [1]. It allows both clinician and patient to three dimensionally visualize the anticipated changes in form and function in a reversible way [8, 9]. These wax-up plaster models are also useful for evaluating the current clinical condition, restoration design, and education of the patient for the recommended treatment design protocol, and for determination of the occlusion [2]. This diagnostic wax-up model can be evaluated by patients and clinicians on the plaster, or on the articulator by the clinician for occlusion analysis, and can also be used intraorally with the use of silicone or acetate matrices (Fig. 4.4a–c). A well-prepared diagnostic wax-up can also aid clinicians to visualize the skipped necessary details which are not observed during

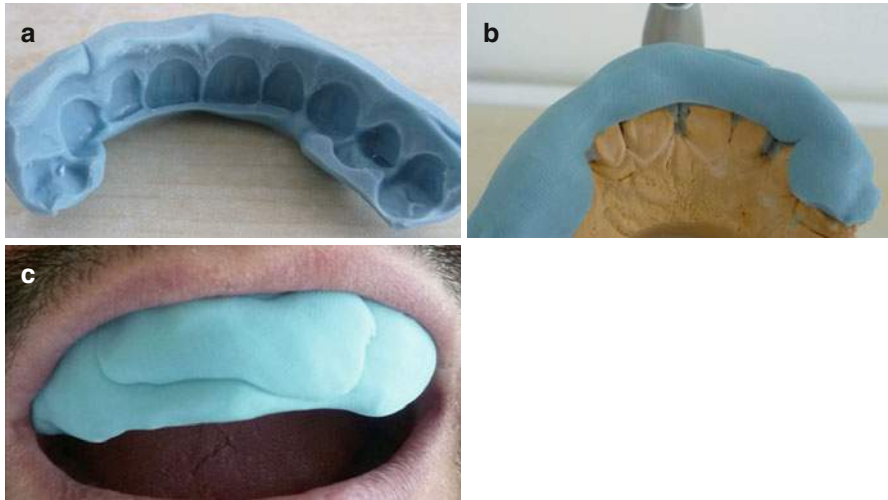


Fig. 4.4 (a) Laboratory-prepared silicone matrices. (b) Control of the silicone matrices on diagnostic wax-up model. (c) Control of the silicone matrices intraorally

clinical examination, and create predictable final results. These diagnostic models can resolve most of the critical questions regarding the restorative treatment plan and completion of treatment [2, 7, 10, 11]. In a multidisciplinary treatment procedure, this wax-up model can facilitate communication with other clinicians involved in the treatment procedure and can help clinicians to precisely communicate about the desired esthetic and function [8]. With this wax-up, other specialists (e.g., orthodontist, periodontologist) can precisely evaluate the model and make suggestions and recommendations in their field of expertise for creation of a functional, esthetically pleasing final outcome. Diagnostic wax-up study models also stands for the dental technician to evaluate the incisal edge position, dental midline, and teeth length and width [9]. By allowing visualization of the patient's current condition and proposed restorative treatment, the dental technician can also help the clinician regarding choice of material, preparation design, and treatment sequence [8]. These discussions with the other experts and dental clinicians in regard of the diagnostic wax-up should not be overlooked, especially in the multidisciplinary approach as in the case of diastema closure. It is advisable that the clinician always keeps an unmodified plaster model for future before-after comparisons and reference [6]. Sometimes it is difficult for the patient to visualize the proposed final results by simply observing a wax-up either directly (Fig. 4.5) or on the articulator; therefore, it is recommended that the clinician makes the wax-up model more understandable for the patient so that the proposed final outcome is more easily discerned [1]. An easy method of making realistic plaster wax-up models is to use pink matrix or wax (Fig. 4.6) around the teeth to simulate the gingiva [1]. This technique can give an opportunity to the patients to see final result in a more realistic environment compared to a simple wax model. Although diagnostic cast models are important tools for the patients to envision the final results either directly

Fig. 4.5 Chairside direct evaluation of diagnostic wax-up model by the patient

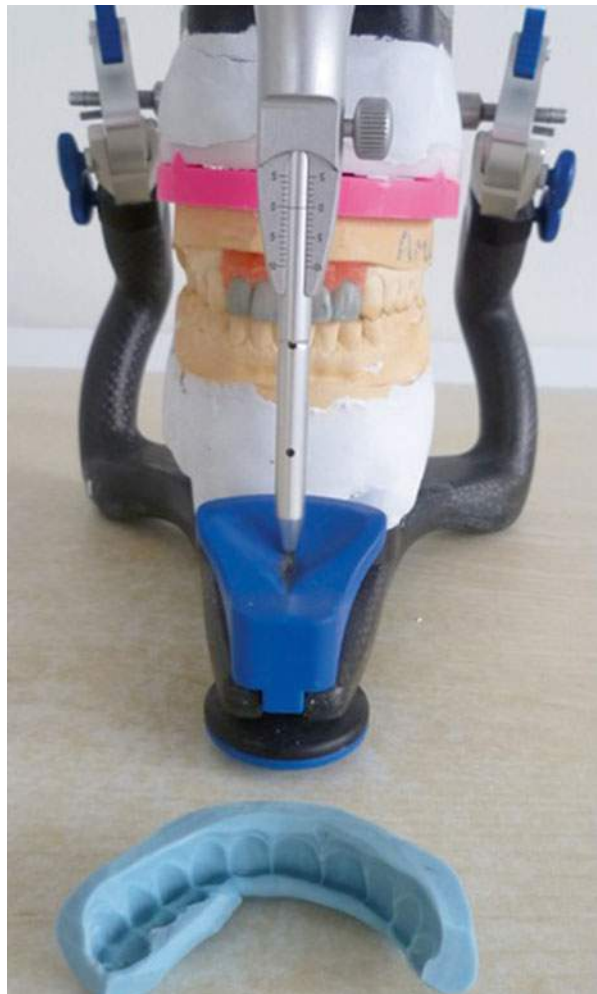

Fig. 4.6 The use of pink wax around the teeth to simulate gingiva on a wax-up model to give an opportunity to patients to see the final result, and laboratory-prepared silicone matrices in accordance with the wax-up

Fig. 4.7 Sometimes it is difficult for the patient to understand the proposed final outcome even with the use of a pink matrix on a plaster model with wax-up

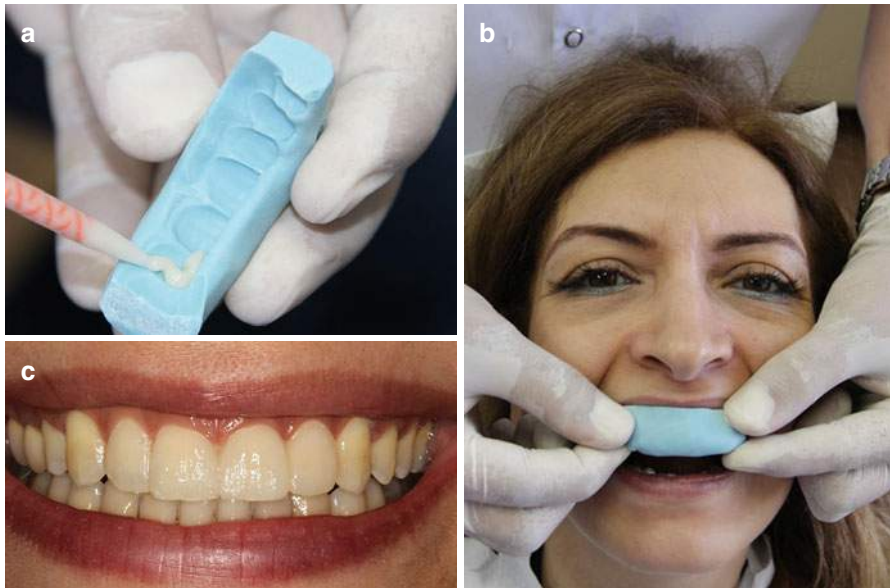
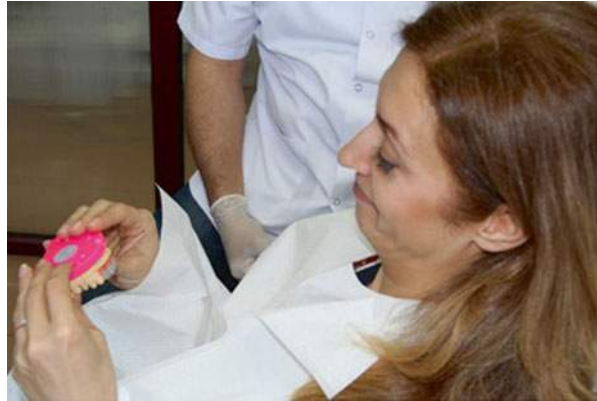
Fig. 4.8 (a) Preparing temporaries for the patient with the help of laboratory silicone matrices, using acrylic. (b) Placing silicone matrices with the acrylic onto the patient's teeth. (c) Prepared temporaries

or on the articulator, it is sometimes difficult for patients to understand the proposed final outcome even with the use of a pink matrix (Fig. 4.7). Therefore, the clinician should also use these wax-up models for the creation of temporary composites intra-orally with the use of acrylic overlays or silicone acetate matrices [1] (Fig. 4.8a–c). Through this provisional restoration, the clinician can determine and test whether the overlays fit with the patient's occlusion, teeth, gingiva, lips, and face; if any negative aspect is detected, appropriate modifications can be carried out as necessary [8].

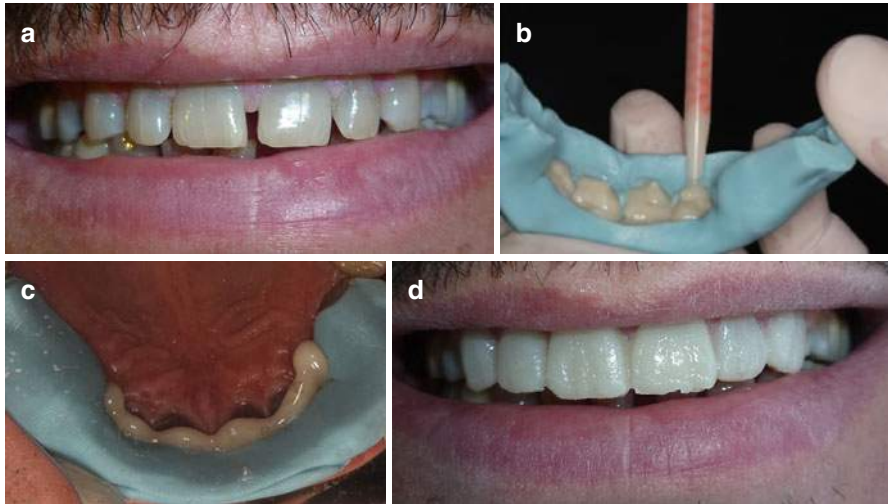
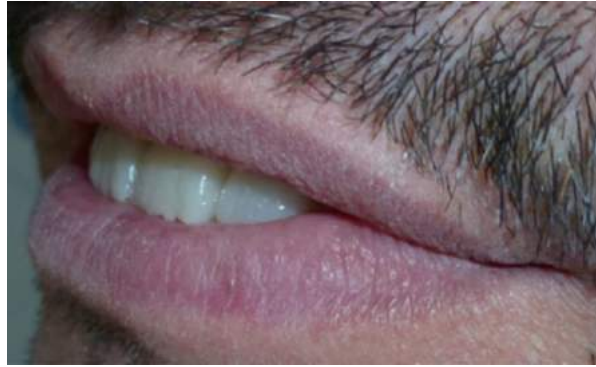
Fig. 4.9 (a) Frontal view of the patient. (b) Filling of the silicone matrices produced from wax-up model with auto-cure temporary filling. (c) Intraoral view of the silicone matrices with overflowing temporary filling. (d) Produced diagnostic mock-up

These provisional restorations are previews of the final restorations whereby both clinician and patient can envision the final restorations in terms of esthetics, function, and harmony with the surrounding structures and smile, though less than optimal. Diagnostic models and radiography are useful to evaluate the current conditions of teeth, but are insufficient for the evaluation of the relationships between soft tissues and teeth. Digital imaging and a direct composite resin mock-up are more beneficial in achieving this goal. Diagnostic mock-up is the clinically equivalent procedure of the diagnostic plaster wax-up model [9, 12]. Direct composite resin mock-ups without incorporation of an adhesive system are simple, creative, and beneficial to both patient and clinician in foreseeing the possible final restorations before proceeding with any definitive restorative treatment [1]. It can also help the clinician to determine the final expected color shade and can serve as a more realistic alternative to diagnostic cast models. However, it is important to use a proper composite resin color matched with the adjacent teeth to avoid any bias, since a patient's perception of shape can be influenced by the color of the material used [9]. Diagnostic mock-up is easy to produce, either directly on the teeth or by obtaining silicon matrices from the wax-up model, filling it with auto-cured temporary filling material, and placing it intraorally [6] (Fig. 4.9a–d). This technique is an advantageous diagnostic tool to anticipate the expected outcome intraorally during a short time in the clinical chair. The proposed restoration is visualized in three dimensions by placing resin composites directly on the teeth intraorally or by filling the obtained silicon or acetate matrices with an auto-cured temporary filling material and placing it onto the teeth. In this way, the consistency of the placed restoration with other teeth, gingiva, lips, and face of the patient is visualized in three dimensions. The use of a mock-up is

Fig. 4.10 Evaluation of the patient with prepared mock-up for correct incisal edge position during pronunciation of “F” sound



useful especially in diastema closure because the proposed restoration can change the patient's appearance and phonation and, hence, the clinician is able to create a harmonious and phonetically relevant final restoration. Creation of the mock-up for diagnostic evaluation is simple. Resin composite material can be placed on the teeth by free-hand stratification without any adhesive application, and after polymerization the clinician can correct the restoration with burs and/or polishing disks to create a harmonious restoration with the teeth, soft tissue, lips, and face. This allows both clinician and patient to see eventual changes and contours of the restoration fit with the lips and face. In addition, phonation of the patient, especially with the “F” and “V” sound, can be tested for the evaluation of correct incisal edge position of the maxillary centrals [9, 13] (Fig. 4.10). Owing to closure of the space between the teeth, potential alteration or change in phonation may be noted by the patient, and adaptation to this new position may take few days; this aspect should also be discussed with the patient [9, 14, 15]. In an alternative procedure, a silicone impression is obtained from the vestibular aspect of the diagnostic wax-up model using polyvinyl siloxane putty material for creation a silicone matrix that is arranged in the patient's gingival architecture by using a scalpel. An auto-cured resin material with the proposed shade is placed into the silicone matrix and then placed directly onto the patient's teeth until the resin polymerizes. Before the full polymerization of the resin material, any excess must be removed with an explorer or hand instrument from the gingival margins before removal of the silicone matrix (Fig. 4.11a, b). If there is any excess after removal of the silicone matrix, this can be removed with a scalpel, or diamond or carbide round burs. This temporary resin material forms a perfect duplicate of the diagnostic wax-up with the selected shade for the definitive restoration (Fig. 4.12) [1, 6]. After these corrections, the patient can see the proposed restoration immediately [6]. These intraoral procedures are reversible, and allow the clinician to verify and modify the proposed result on the teeth in accordance with the esthetic parameters and, importantly, patient feedback [1, 13]. Intraoral conditions such as diastema, worn dentition, and fractured anterior teeth can be effectively managed with this technique for creation of a desired esthetic outcome. Moreover, the desired shade of the restoration can be easily determined at this stage [1]. The effects of a

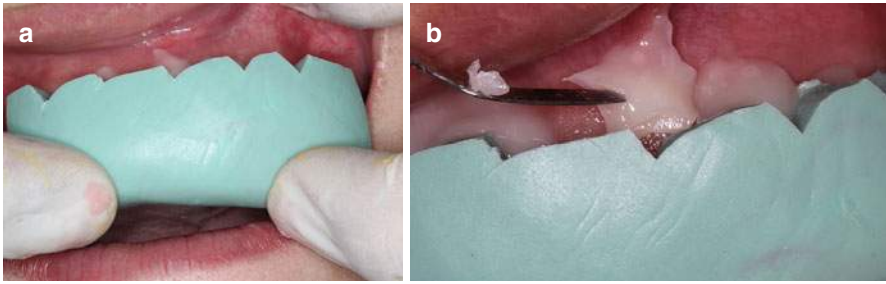
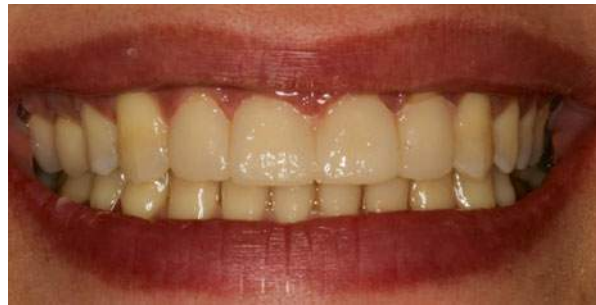

Fig. 4.11 (a) Preparing direct mock-up with auto-cure temporary filling material using polyvinyl siloxane putty, obtained from a wax-up model and arranged within the patient's gingival architecture. (b) Removal of excess material with a hand instrument before full polymerization

Fig. 4.12 Prepared direct mock-up with the temporary filling material using silicone putty in a single visit



diagnostic mock-up on patient expectation, desire, and final restoration outcome cannot be ignored, and can be achieved rapidly and easily at low cost. Mock-up techniques provide an opportunity to correct the designed temporary restoration and verify final optimal restoration, intraoral occlusion analysis, length of the restoration, and relationships with the neighboring teeth and with the gingiva, lips either in rest or at smile, phonation, and harmony with the patient's face. All these parameters can be visualized and experienced by the patient immediately, and it is highly recommended that the clinician gives the mock-up to the patient when leaving the clinic to show friends and family, thus to obtain feedback for the final design of the restoration.

Contemporary digital imaging software can also be an advantageous diagnostic tool for an esthetic restorative treatment. In the treatment of diastema and other conditions, an esthetically pleasing treatment outcome involves modification of the patient's smile. Therefore, a comprehensive diagnosis and evaluation prior to definitive treatment should be done by the clinician, which must be shared with the patient [5]. The use of computer imaging software can be an effective tool for sharing and evaluating the designed restoration with the patient before initiation of a definitive restorative treatment (Fig. 4.13a–c). The patient can see the created restoration in association with the adjacent teeth, lips, and face on the monitor. While this method is undoubtedly useful

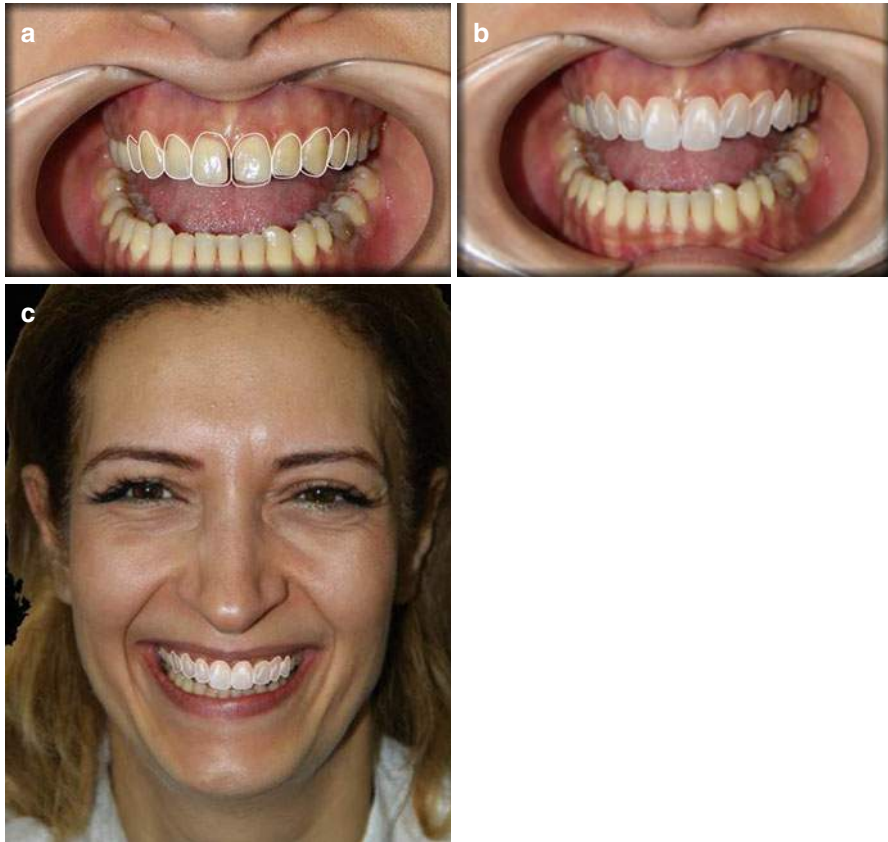

Fig. 4.13 (a–c) Smile analysis of the patient using digital smile design software to share and evaluate the designed restoration with the patient before initiation of the definitive restorative treatment

for showing the desired restoration to the patient on screen, phonetic and occlusal evaluation is limited. For this reason, the clinician also needs to create an acrylic or composite mock-up for phonetic evaluation of the patient when using this digital method.

Almog et al. [2] evaluated the effect of esthetic diagnostic methods on patient acceptance of diastema closure, including before-after pictures of other patients, diagnostic wax-up models, direct composite mock-up, and digital imaging simulation, on 24 patients. They reported that digital imaging simulation was the technique most preferred by patients (54.2 %) followed by direct composite mock-up (33.3 %) and before-after photos of the other patients (12.5 %). None of the patients selected the diagnostic wax-up for acceptance of the treatment plan.

After a comprehensive evaluation of the dental situation of a particular patient with the aforementioned diagnostic methods, the clinician also needs to evaluate the proposed restoration in relation to the patient's lips and face. As the main objective of the esthetic treatment procedure is to create a natural, healthy, functional, and

esthetically pleasing restorations for patients in this complex area, a multidisciplinary approach to comprehensive diagnosis and treatment plan involving periodontology, orthodontics, and restorative dentistry is necessary [5]. Therefore, detailed diagnosis with the diagnostic wax-up and mock-up of the given dental composition should be evaluated in detail in relation to the patient's facial architecture. Although the aforementioned diagnostic tools are efficient in presenting a proposed restoration to the patient regarding the condition of his or her teeth, radiographic examination with a full series of periapical, panoramic, and cephalometric radiographs are necessary for evaluation of the teeth, in addition to skeletal relationships.

It is critically important to understand patients' esthetic expectations and desires as well as occlusion before initiation of the irreversible treatment procedure. It is also important to communicate with the patients on their expectation, and to communicate with the other members of the multidisciplinary treatment team, including the dental technician, for creation of esthetically and functionally pleasing final outcome in diastema closure. Several available techniques are described in this chapter for appropriate diagnosis, esthetic expectations, and potential esthetic and functional evaluation of patients before definitive restorations. These diagnostic evaluation tools can be successfully used to determine patient expectations, satisfaction with the proposed treatment, and education of the patient on the limitations of the proposed restoration in several intraoral situations [1]. Using these techniques facilitates clinicians to communicate with patients regarding the final restoration design, and the limitations of the restorative procedures.

4.1 Diagnostic Setup

A setup on dental models is performed by repositioning the teeth to correct the malocclusion for diagnostic purposes. A diagnostic setup is needed for orthodontic-restorative diastema cases with microdontia or hypodontia to guide the clinicians, both orthodontist and restorative dentist, in treatment planning and progress. Furthermore, it helps to the communication between specialists. The diagnostic setup will provide information about:

- The final position of the teeth
- The number of teeth to be restored
- The position and dimensions of the restorations
- The timing, sequencing, and progress of the treatment

Traditionally, diagnostic setups are prepared on face-bow transferred and articulated dental models by separating and repositioning the teeth (Fig. 4.14a, b). Although simplified techniques have been presented, manual setups are still time consuming, with extra laboratory work [16]. Nowadays, with the development of computer technology, digital setups using software programs are replacing

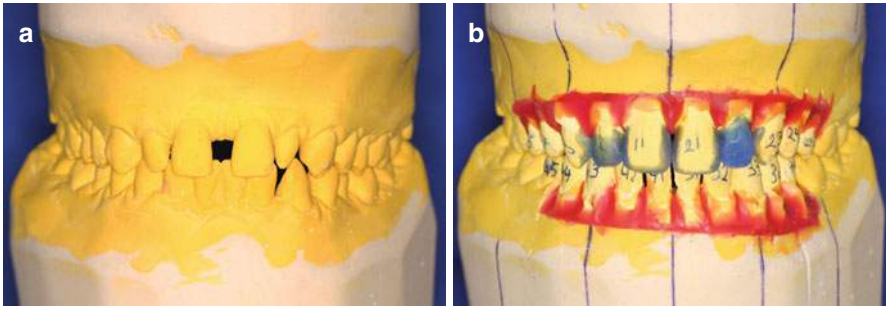


Fig. 4.14 (a) Pretreatment models of a case with bimaxillary diastema due to tooth size discrepancy. (b) Diagnostic setup with wax-up of the undersized teeth

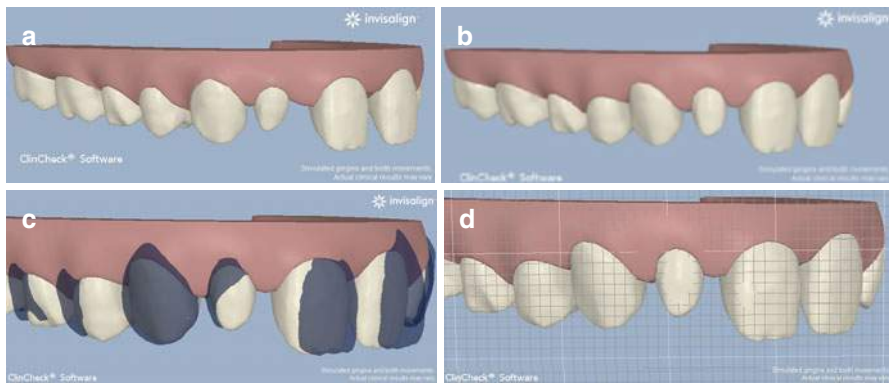


Fig. 4.15 (a) Maxillary digital model of a polydiastema case requiring collaborative treatment. (b) Treatment plan included retraction of the anterior teeth, mesial movement of the posterior teeth to partly close the diastemas, and redistribution of the remnant spaces prior to the restoration of the undersized teeth. (c) Superimposition (dark images show pretreatment positions). (d) Measurement of tooth dimensions and spacing on three-dimensional digital images using grid function (ClinCheck Software images courtesy of Align Technology, Inc.)

manual ones. Digital software programs are very accurate and help to display multiple treatment options in a short time without the need of laboratory work [17]. The scanned dental casts or directly scanned dentition is transferred to the software program for three-dimensional virtual treatment simulation (Fig. 4.15a–d). Treatment options are simulated according to the diagnostic findings, treatment objectives, and patient’s demands. Tooth repositionings can be clearly visualized thanks to superimposition of pretreatment and simulated posttreatment dentition. In addition, the use of different functions of the software allows direct measurement of dimensions of the teeth and the redistributed spaces. Various software programs, available commercially, may have different functions for the same purpose.

References

1. Marzola R, Derbabian K, Donovan TE, Arcidiacono A. The science of communicating the art of esthetic dentistry. Part I: patient-dentist-patient communication. *J Esthet Dent.* 2000;12(3):131–8.
2. Almog D, Sanchez Marin C, Proskin HM, Cohen MJ, Kyrkanides S, Malmstrom H. The effect of esthetic consultation methods on acceptance of diastema-closure treatment plan: a pilot study. *J Am Dent Assoc.* 2004;135(7):875–81.
3. Ahmad I. *Protocols for predictable aesthetic dental restorations.* Oxford, UK: Blackwell Munksgaard; 2006. p. 1–16.
4. Tarantola GJ. *Clinical cases in restorative and reconstructive dentistry.* 1st ed. Ames: Wiley-Blackwell; 2010. p. 5–25.
5. Rifkin R. Facial analysis: a comprehensive approach to treatment planning in aesthetic dentistry. *Pract Periodont Aesthet Dent.* 2000;12(9):865–71.
6. St-Pierre L, Cobb DS. Enhancement of aesthetic treatment planning and communication using a diagnostic mock-up. *Cosmet Dent Engl.* 2012;3:20–4.
7. Magne P, Magne M, Belser U. The diagnostic template: a key element to the comprehensive esthetic treatment concept. *Int J Periodontics Restorative Dent.* 1996;16(6):560–9.
8. Tarantola GJ. *Clinical cases in restorative and reconstructive dentistry.* 1st ed. Ames: Wiley-Blackwell; 2010. p. 37–55.
9. Simon H, Magne P. Clinically based diagnostic wax-up for optimal esthetics: the diagnostic mock-up. *J Calif Dent Assoc.* 2008;36(5):355–62.
10. Bowley JF, Stockstill JW, Attanasio R. A preliminary diagnostic and treatment protocol. *Dent Clin North Am.* 1992;36(3):551–68.
11. Strassler HE. Planning with diagnostic casts for success with direct composite resin bonding. *J Esthet Dent.* 1995;7(1):32–40.
12. Magne P, Magne M. Use of additive waxup and direct intraoral mock-up for enamel preservation with porcelain laminate veneers. *Eur J Esthet Dent.* 2006;1(1):10–9.
13. Gurel G. *The science and art of porcelain laminate veneers.* Ergolding, Germany: Carol Stream: Quintessence Publishing Co; 2003. p. 231–9.
14. Gürel G, Bichacho N. Permanent diagnostic provisional restorations for predictable results when redesigning the smile. *Pract Proced Aesthet Dent.* 2006;18(5):281–6.
15. Gürel G. Porcelain laminate veneers: minimal tooth preparation by design. *Dent Clin North Am.* 2007;51(2):419–31.
16. Kim SH, Park YG. Easy wax set-up technique for orthodontic diagnosis. *J Clin Orthod.* 2000;34:140–4.
17. Schechtman RL. Treatment planning for orthodontic-restorative cases with Sure Smile technology. *J Clin Orthod.* 2014;48:639–49.

Ugur Erdemir, Esra Yildiz, and Taner Yucel

Abstract

Increasing number of patients are demanding mechanically functional, physiologically sound, and esthetically pleasant restorations in recent years. Achieving esthetically and functionally pleasant restorations in harmony with the patient's teeth, gingiva, lips, face, as well as occlusion is the most important aspect in esthetic dentistry. In esthetic dentistry, several combinations of measurable dimension, formulae, and geometric proportions have been proposed. Applying these specific rules, tools, and principles to patient's face as well as mouth for smile design creates a pleasant, esthetic, and natural final appearance.

Creating esthetically pleasant and satisfactory restorations which are in harmony with the patient gingiva, lips, facial contours, and appearance is one of the most important aspects in esthetic dentistry [1, 2]. Achieving well aligned and proportional anterior teeth in harmony with the abovementioned components is essential for creating esthetic and functional restorations. In recent years, an increasing number of patients are demanding mechanically functional, physiologically sound, and esthetically pleasant final restorations [3]. To reach these goals, clinician should pay attention to the patient's expectations in creating sound, biomimetic, and esthetically pleasing restorations. In this process, clinician should consider that personal expectations, desires, perception of attractive smile, and beauty can show individual variety. Furthermore, the occlusion and the anatomical variations of the patient may affect the desired, biomimetic final results [2]. Therefore, to create an optimal,

U. Erdemir, PhD, DDS (✉) • E. Yildiz, PhD, DDS • T. Yucel, PhD, DDS
Operative Dentistry, University of Istanbul Faculty of Dentistry, Istanbul, Turkey
e-mail: uerdemir@hotmail.com

esthetically pleasing, and harmonious final restoration with the patient teeth, lips, and face, the clinician should use several geometric and special references where the biomimetic and attractive smile is of paramount importance [1–3]. Smile design procedures involve applying specific principles, rules and tools on the determination of patient face, lips, gingival condition, and teeth in order to create a pleasant, esthetic, and natural final appearance. In esthetic dentistry, several combination of measurable dimension, formulae, and geometric proportions have been proposed in relation to the creation of an attractive smile that harmonize with the patient teeth, surrounding sound tissues, and facial aspect [2, 4, 5]. Esthetic evaluation should not only be based on these measurable parameters; clinician should also consider the lifestyle as well as personal perception of beauty of a patient during designing an attractive natural smile [4].

In the last three decades, both visual and written media, esthetic trends and fashion have led to increased impact and awareness on the cosmetic dentistry as well as smile esthetic for the patients [4, 6]. Due to development of the dental materials and equipment, patient's esthetic expectation and demands are substantially increased in recent years. Nowadays, patient awareness on the smile as well as facial esthetics is increased due to impact on the patients' well-being, social acceptance, and success at work and daily relations [7]. Therefore, a variety of smile design protocols are available for the clinicians to meet their patients' expectations and demand on the natural esthetics and smile. A beautiful smile is the most important expression and is related to the psychological condition of a person [7]. Creation of a beautiful smile should rely on facial, dentofacial, and dental analysis. Considering all the specific smile parameters, dimensions and lines, clinicians needs to be aware of interindividual variability of the facial and smile characteristics of each patient and hence should design smile individually.

Key Note

For creating natural, functional, and pleasant smile esthetic, clinician should know about the objective analysis protocols that include dimensions, lines, and mathematical ratios of the facial, dentofacial, dentogingival, and dental components.

Smile design is a systematic process that enables to make some changes on the soft as well as hard tissues within the limitation of the anatomical features to create functional, esthetically pleasant, biomimetic restorations for a patient [7]. Creating an esthetically pleasant smile often requires multidisciplinary approaches for the structural integrity and harmony between teeth, gingiva, and lips for facial conformity. Therefore, clinician should be competent on the objective analysis protocols that include dimensions, lines, and mathematical ratios of the facial, dentofacial, dentogingival, and dental components to achieve an esthetic psychological aspect

that includes personality, expectations, and demands for creating natural and pleasant smile [7].

In general, smile design principles are divided into two main parts: micro- and macroesthetics [6]. Microesthetics means form, fine characterization of teeth such as reflection of light, color, and/or transparency that mimic natural teeth as well as relationship between teeth, gingiva, and lips (Fig. 5.1a–d). These anatomic features are unique characteristics and may vary from tooth to tooth, age to age, and person to person. The primary factor of the esthetic and attractive smile is the teeth, and hence, thoroughly understanding of the tooth characteristics, anatomy, and optic features are the key factor for the optimization of the restoration [4]. Macroesthetics addresses the proportions and relationship of the teeth with each other and in harmony with the surrounding structures such as gingiva, lips, and facial characteristics of the patients [6] (Fig. 5.2a–c).

Harmoniously aligned teeth with the surrounding soft tissue as well as face ensures natural and attractive smiles for a patient, and clinician should work in collaboration with the multidisciplinary team members to combine their technical and artistic skills for creating pleasant, biomimetic, and natural restorations (Fig. 5.3a, b).

For these reasons, thorough evaluation and understanding of the various proportions, dimensions, and artistic elements are essentially important to create a balanced, harmonious, and naturally pleasant restoration. Therefore, a detailed, systematic facial, dentofacial, dentogingival, and dental analysis should be done carefully for a successful, pleasant, biomimetic, and natural esthetic outcome [3–5].

Key Note

Smile design process should be managed by multidisciplinary approaches in decision-making process for creation of an individualized patient treatment, and clinician can use a variety of smile design softwares and protocols to achieve most predictable and pleasant final results.

Currently, a variety of smile design software and protocols are available to clinicians for creating most predictable and pleasant final results. Some of these softwares are available for a fee for clinical implication (Digital Smile System, Varese, Italy; Smile Designer Pro, Toronto, Ontario, Canada; Smylist Professional, Budapest, Hungary; Smiletron, Swatar, Malta), and another such as Photoshop software [8] (Adobe system, San Jose, CA, USA) and Keynote (Apple Inc., Cupertino, California, USA) can also be used for determination of the smile design (Figs. 5.4 and 5.5). As previously described, smile design process should be managed by multidisciplinary approaches in decision-making process for an individualized treatment [7]. Smile design requires a series of esthetic principle integration to the treatment procedure

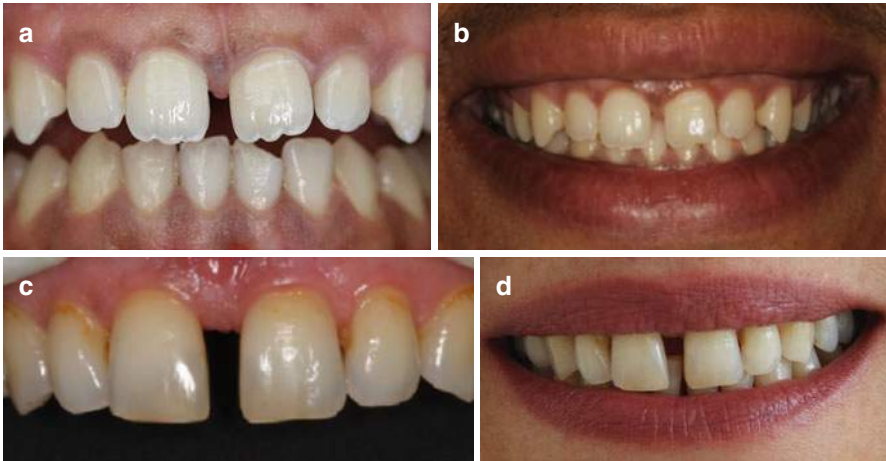

Fig. 5.1 Microesthetic evaluation. (a, b) Surface characteristics of teeth in a 20-year-old patient and their relationship with lips. (c, d) Surface characteristics of teeth in a 50-year-old patient and their relationship with lips

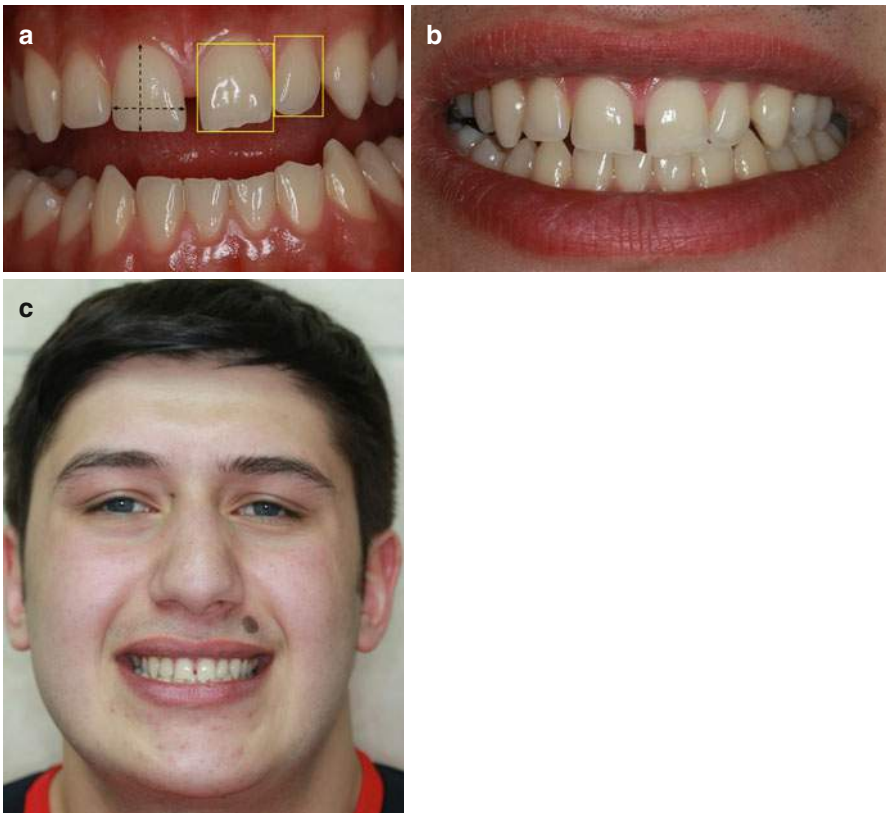

Fig. 5.2 Macroesthetic evaluation. (a) Evaluation of the tooth proportions and relationship of each tooth to other. (b) Evaluation of the harmony between teeth and surrounding structures. (c) Evaluation of the harmony between teeth and facial characteristics

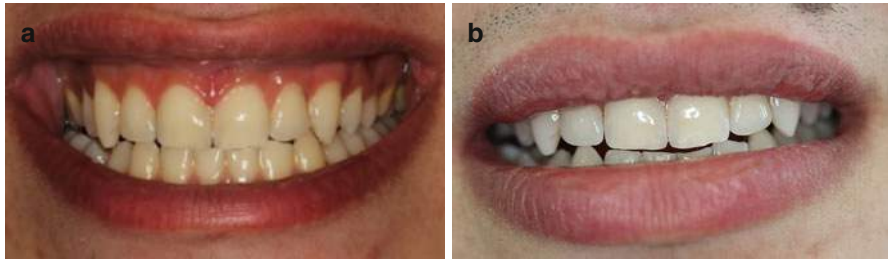


Fig. 5.3 (a) Final restorations (note harmoniously aligned teeth and gingiva), (b) harmonious relationship between the teeth and the lips

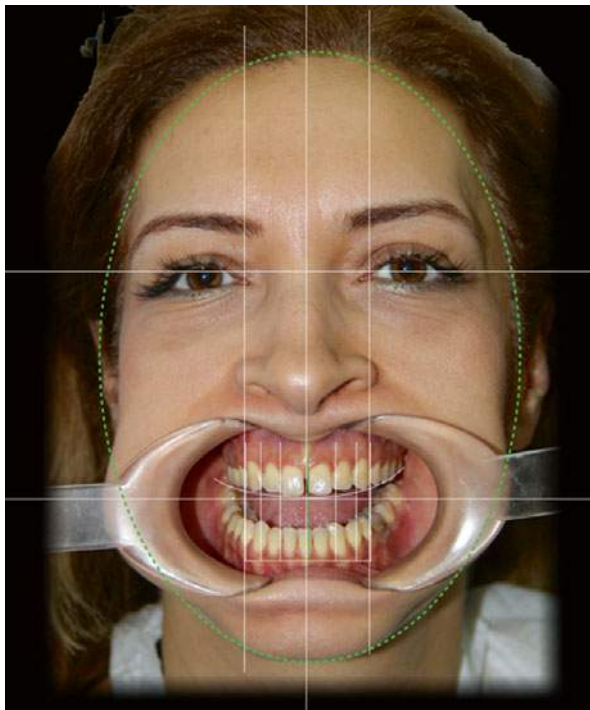


Fig. 5.4 Smile analysis of patient by using Keynote (Apple Inc., Cupertino, California, USA)

for creation of harmonized restorations with the patient's facial, dentofacial, and dental compositions [9]. For clinician who uses one of the previously mentioned smile design software, it is obviously necessary to obtain both facial and dental photographs of the patient from correct angle and distance.

Esthetic digital smile designing protocol requires a series of full frame digital photographs as well as videos of the patient during smiling and speaking for capturing the dynamic phase [3, 7, 9]. If possible, these photographs must be in high

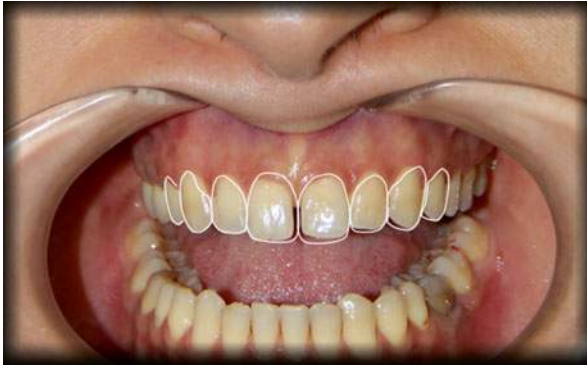

Fig. 5.5 Smile analysis: Determination of the tooth proportions using Keynote (Apple Inc., Cupertino, California, USA)

resolution with a good lighting condition because the photographs are the essential part of the smile analysis of the patient and will be used later for the esthetic analysis within the main principles and guidelines. During capturing of photographs, clinician can also use a tripod which enables stable support for the camera to avoid having any blurry photos. In addition, clinician can also use these photographs for the consultation with the multidisciplinary team member of the restorative procedure for correct analysis of the patient. Posture of the patient is important for obtaining proper and standardized photographs for smile analysis. Therefore, the patient must seat or stand in front of the clinician or photographer in natural head position, and camera must be positioned to focus the head, [10, 11] (Fig. 5.6).

As previously stated, smile design process begins with macroesthetic level in which patient's face and its relation with the smile is evaluated [7, 8]. It should be noted that visual macroesthetic determination must be done at a certain distance more than 1.5 m from the patient [3, 7]. It must be kept in mind that obtaining the facial portrait photographs of the patient's correct positioning of the face is certainly important. By obtaining various facial and profile photographs during static and dynamic smile from different angles (i.e., 45 and/or 90°), clinician can also do macroesthetic assessment of the patient analytically with reference points and lines (Fig. 5.7a–c). Assorted reference points and lines are used for facial analysis in esthetic smile design process as follows: facial thirds, facial midline, bipupillary line, nasolabial angle, and Ricketts E-plane [3, 4, 6, 7, 9, 10]. After capturing correct position of the face, a detailed esthetic smile analysis by marking the face and smile with reference lines must be accomplished for evaluation of the symmetries and/or asymmetries as well as the analytical phase of the smile (Fig. 5.8); these facial references are evaluated for form, balance, and effect on the dental treatment [1, 8]. Capturing 12 o'clock photographs with slightly visible maxillary anterior teeth are also useful for analyzing the symmetries and/or asymmetries on the patient's face (Fig. 5.9). These evaluations help clinician to determine the treatment



Fig. 5.6 Frontal photograph of the patient in natural head position

procedures that may affect the expected esthetic outcome of a case. These analyses can also help clinician to consider a multidisciplinary treatment procedure where restorative treatment may not produce a desired final restoration depending on the complexity of the case [8].

With regard to the microesthetic considerations, fine structures of teeth as well as relationship between teeth, gingival structures and lips must be determined. Clinician must be closer to the patient to obtain proper photographs for evaluation of the smile. Closer distance can help to achieve better visualization and detailed photographs of these structures. During capturing of photographs of the lips, gingival structures, and teeth for smile analysis, clinician must be positioned between 60 and 100 cm away from the patient's face with a correct angle [7]. A variety of guidelines for assessment of the lips, gingiva, and teeth can be used with these analyses frontally, vertically, and horizontally for the assessment of patient's smile characteristics and the relationship between the perioral and intraoral structures [7]. These photographs are essential part of the smile analysis and hence clinician must capture several photographs while lips are closed, half closed, and during smiling (Fig. 5.10a–c). Pronouncing the “m” and “e” sounds of the patients can allow clinician to evaluate the exposure of the maxillary anterior teeth, curvature of the lower lip, and its relation with the maxillary anterior teeth and smile line with regard to the patient's age and sex (Fig. 5.11a, b). In addition, microesthetic analysis of the patient also allows determination of commissural and philtrum height, maxillary incisors position, width of the buccal corridors, dental midline, and

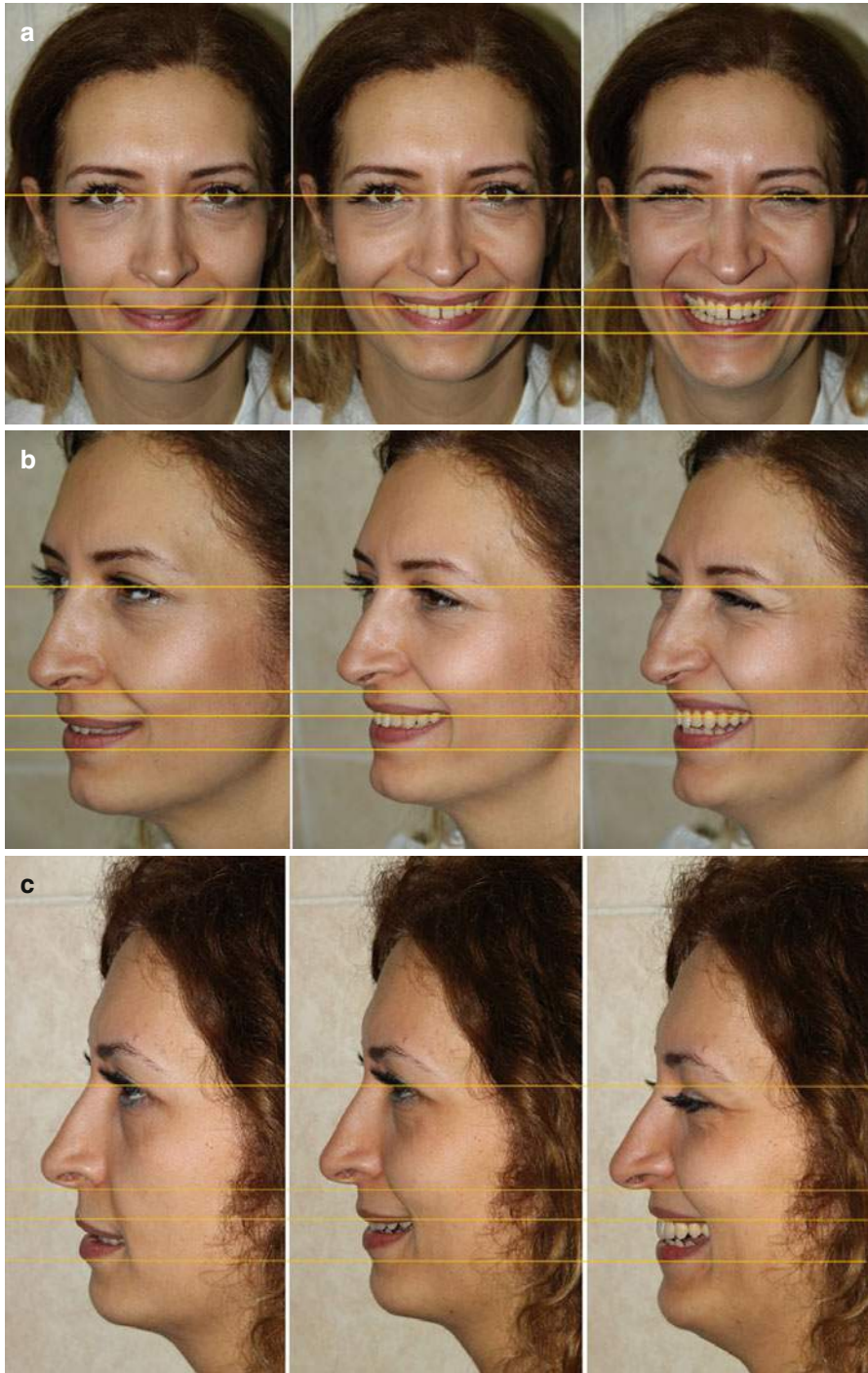

Fig. 5.7 (a–c) Facial frontal and profile photographs of the patient during static and dynamic smile in 45° and 90°

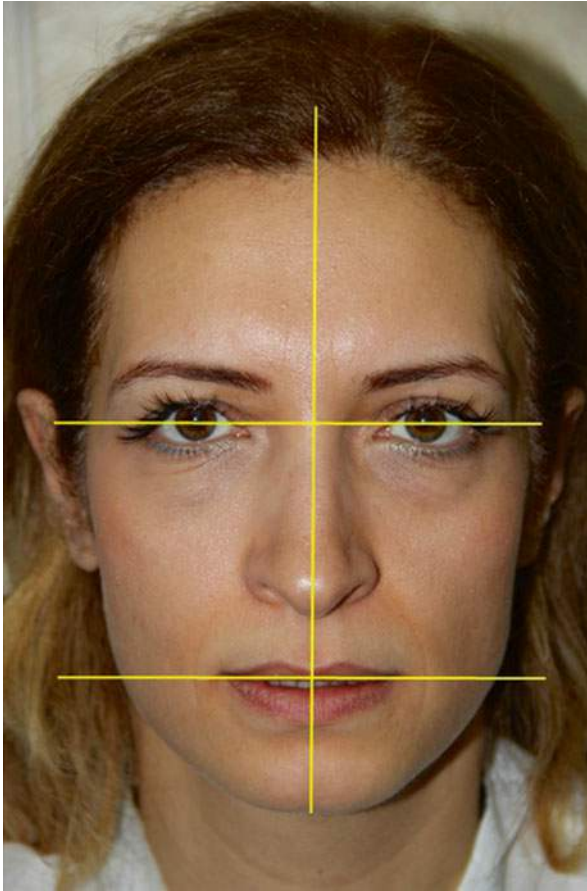


Fig. 5.8 Obtaining natural postural head position photograph with the lips slightly open is important criteria for smile analysis

symmetry of the smile [4, 7]. It should be borne in mind that maxillary central incisors are key structures of the smile analysis procedure. Measuring and analyzing all these references are relevant in smile design process. Incisal edge position of the maxillary central incisors is also very important in esthetic smile design, and different landmarks can be used to analyze the correct position. Clinician should determine the ideal position, and if any deviation is detected during clinical and/or photographic analysis, he or she must decide whether it should be corrected restoratively or by a multidisciplinary approach. After completion of the perioral and intraoral evaluation of the patient, clinician must also evaluate dental and gingival structures in detail for smile analysis. For obtaining correct and proper photographs for this purpose, clinician must come closer to the patient, and focal length of the photograph must be within 20–50 cm according to the camera and lens used. Capturing of the fine photographs with details of the teeth and gingival tissues is

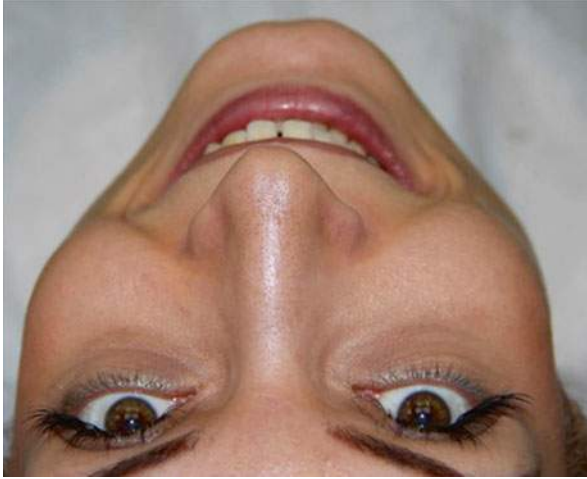

Fig. 5.9 Analyzing the symmetries and/or asymmetries of the patient face for smile analysis at 12 o'clock position with slightly visible maxillary anterior teeth

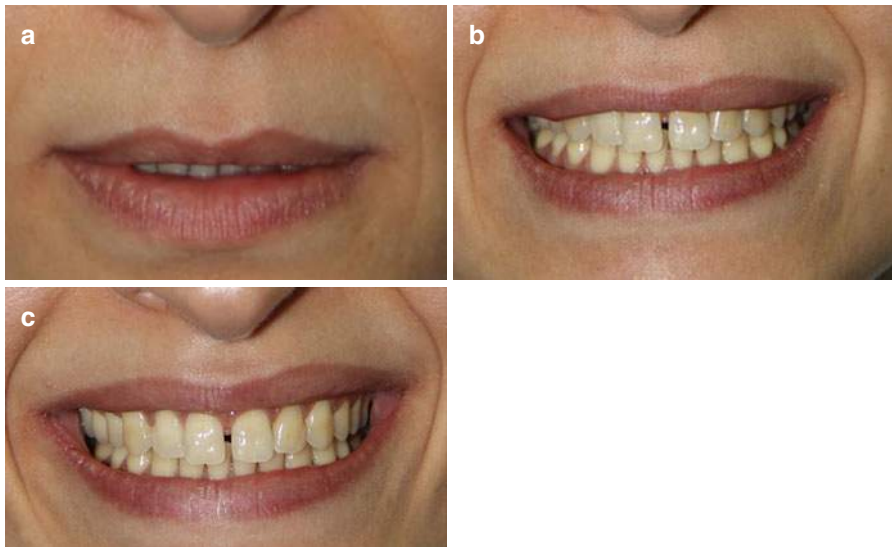

Fig. 5.10 Evaluation of patient for miniesthetic criteria (a) at rest position, (b) during half smiling, and (c) during full smiling

essential parameter for this evaluation. Therefore, in addition to the digital camera and lens, clinician must also use a proper illumination, lip retractors, and intraoral mirrors to achieve detailed study photographs for intraoral examination of the patient (Fig. 5.12a, b). These photographs are necessary for designing smile

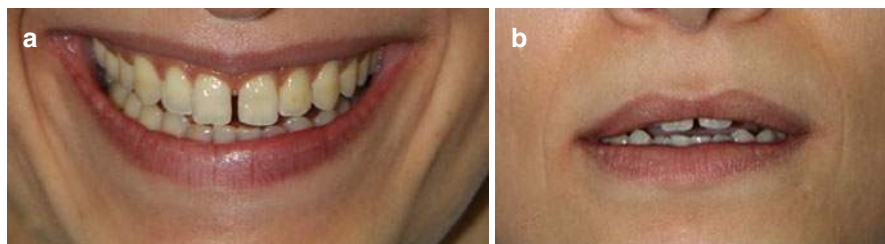


Fig. 5.11 (a) Evaluation of the maxillary anterior teeth display after pronouncing the “e” and (b) “m” sounds (to evaluate the curvature of the lower lip and the relationship between the maxillary anterior teeth and smile line)

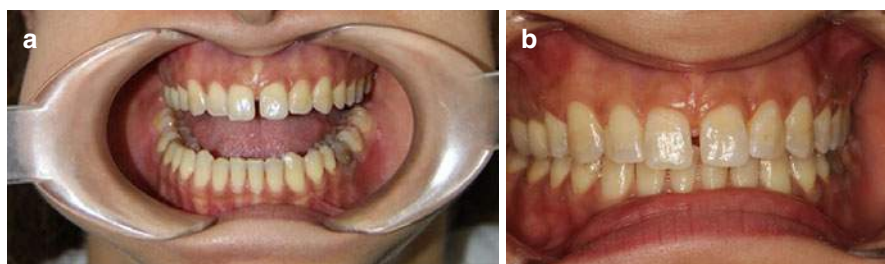


Fig. 5.12 (a, b) The use of lip retractors to obtain intraoral photographs of the patient

analysis as well as future reference of the patient. With these photographs, clinician can magnify the mapping of a tooth, relationship with the adjacent teeth, and perioral structures on computer screen for detailed smile analysis. In smile analysis, gingival structures should also be evaluated for soundness and appearance. Therefore, during this analytical phase, ratio of the upper central incisors which are key structures of the smile analysis, surface characteristics, incisal embrasures, color, golden ratio, contact relations, as well as gingival embrasures, gingival zenith location, and gingival height should be analyzed with reference guidelines. Clinician can also use a caliper or ruler for exact measurements of the teeth as well as gingival structures for an accurate smile design (Fig. 5.13a, b). These detailed measurements can also be used for the communication in the multidisciplinary team (i.e., orthodontist, periodontologist) and dental technician for creation of naturally pleasant final outcome. Clinicians always bear in mind that proper diagnosis, consideration of patient expectations and demands, creation of functional restoration within the limits of the occlusion, and enhancement of esthetic design will help to achieve the most satisfactory final outcome in any of the esthetic restorative treatment procedures or smile design to accomplish pleasant, natural, biomimetic and long lasting restorations.

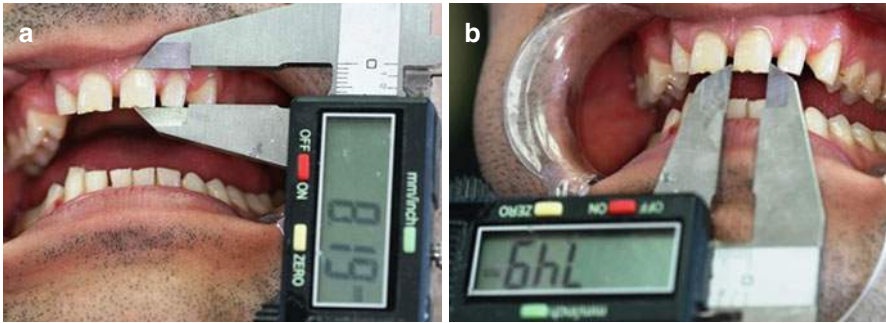


Fig. 5.13 (a, b) The use of digital caliper for exact measurement of tooth dimensions

References

1. Kirtley GE. The art of beautiful smile. *J Cosmet Dent.* 2008;24(3):122–31.
2. Donitza A. Creating the perfect smile: prosthetic considerations and procedures for optimal dentofacial esthetics. *J Calif Dent Assoc.* 2008;36(5):335–40.
3. Calamia JR, Levine JB, Lipp M, Cisneros G, Wolff MS. Smile design and treatment planning with the help of a comprehensive esthetic evaluation form. *Dent Clin North Am.* 2011;55(2):187–209.
4. Gurel G. The science and art of porcelain laminate veneers. Carol Stream: Quintessence Publishing Co. Ltd., Ergolding, Germany; 2003. p. 59–109.
5. Oquendo A, Brea L, David S. Diastema: correction of excessive spaces in the esthetic zone. *Dent Clin North Am.* 2011;55(2):265–81.
6. Wasche M, Hepps R, Geissberger M. Guiding principles of esthetic dentistry. In: *Esthetic dentistry in clinical practice.* 1st ed. Ames: Wiley-Blackwell; 2010. p. 9–17.
7. Koirola S. Smile design Wheel™: a practical approach to smile design. *Cosmet Dent.* 2009;3:24–8.
8. McLaren EA, Culp L. Smile analysis. *J Cosmet Dent.* 2013;29(1):94–108.
9. Davis NC. Smile design. *Dent Clin N Am.* 2007;51(2):299–318.
10. Rifkin R. Facial analysis: a comprehensive approach to treatment planning in aesthetic dentistry. *Pract Periodontics Aesthet Dent.* 2000;12(9):865–71.
11. Viazis AD. A cephalometric analysis based on natural head position. *J Clin Orthod.* 1991;25(3):172–81.

Esra Yildiz, Taner Yucel, Ugur Erdemir,
and Derya Germec Cakan

Abstract

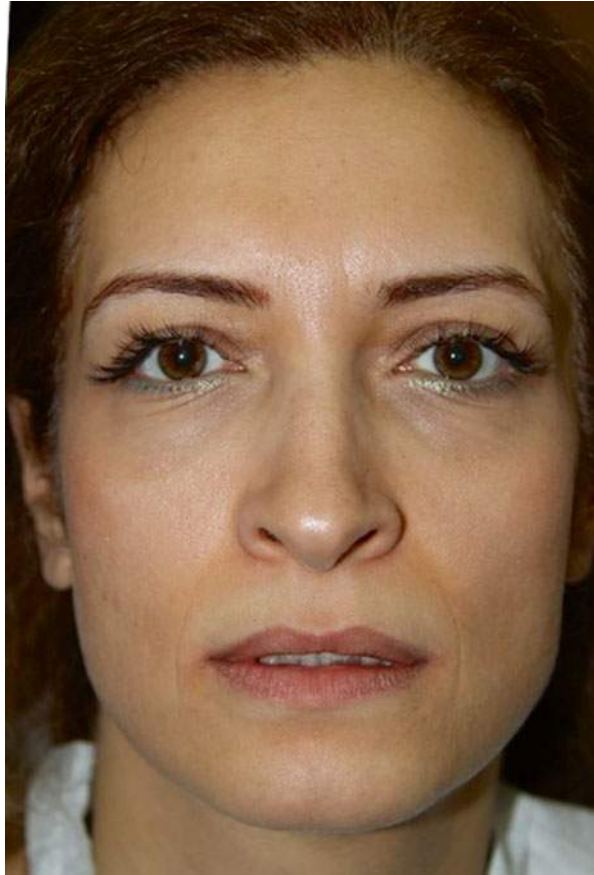In creating a naturally pleasing esthetic smile in smile design procedure, the clinician should use horizontal and vertical lines between anatomical landmarks of the face to produce harmonious form and balance between teeth, gingiva, lips, and face. A variety of essential facial landmarks are used for smile analysis, and these should be examined using guidelines for facial symmetry and proportions. In general, the concept of facial analysis comprises dividing the face horizontally into three equal thirds for optimal balance and pleasing proportions for achievement of a more attractive and harmonious face. In addition to facial evaluation through smile analysis, the clinician should also evaluate the lateral facial profile in collaboration with the orthodontist using cephalometric radiographs for appropriate diagnosis and treatment plan of a case.

Evaluation of a patient by smile analysis should begin at the macro level and progress to the micro level, and includes facial, dentofacial (arch relations and midline relationship with the face), dentolabial (teeth relationship with the lips), dentogingival (teeth relationship with the gingiva), and dental analysis [1–4]. In principle the clinician should have adequate knowledge about the form, characteristics, and color of the teeth and the relationships with the surrounding structure, and must correctly transfer all of these informations to aid in the fabrication of final restorations [5]. In analyzing facial aspects of a patient, obtaining good quality photographs under

E. Yildiz, PhD, DDS (✉) • T. Yucel, PhD, DDS • U. Erdemir, PhD, DDS
Operative Dentistry, University of Istanbul Faculty of Dentistry, Istanbul, Turkey
e-mail: eyildiz1966@hotmail.com

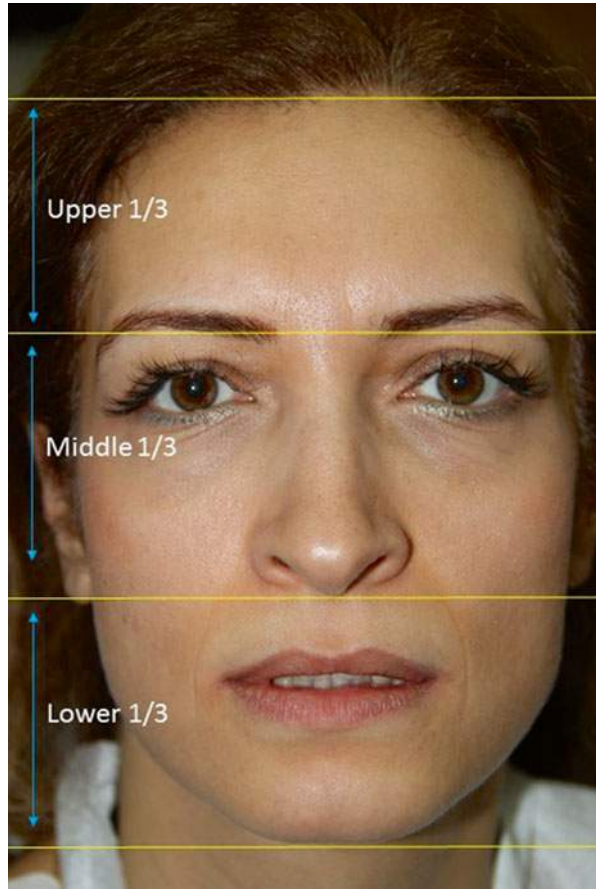
D. Germec Cakan, DDS, PhD
Orthodontics, Yeditepe University, Dental Faculty, Istanbul, Turkey

Fig. 6.1 For evaluation of facial thirds, a photograph of the patient should be captured while the lips are slightly open and the patient is at rest



sufficient illumination at specific distances is mandatory. The most accurate and reliable position for obtaining facial photographs is the natural head position whereby the patient sits or stands in front of the clinician or photographer [6] (see Fig. 5.6). Profile photographs of the patient at 45° and/or 90° are also important (see Fig. 5.7b, c). Smile analysis should begin with facial analysis conducted in accordance with proposed guidelines [5–7]. The clinician should use several horizontal and vertical reference points and lines to create a pleasing, natural smile compatible with the patient's face [2, 3, 6]. Horizontal and vertical lines between anatomical reference points are used to judge form and balance, which may affect the restorative smile design procedure [1, 5, 7, 8]. A variety of essential facial landmarks are examined using guidelines on facial symmetry and proportions [9]. During evaluation of facial thirds for smile analysis, the face should be captured photographically with the lips slightly open and at rest [6] (Fig. 6.1). This position allows optimal facial evaluation for each individual; if maximal occlusal contact occurs while photographing it will show a decrease in the facial height of the patient, resulting in inadequate vertical dimensions for evaluation [5]. In general, the concept of facial analysis includes dividing

Fig. 6.2 Dividing the face horizontally into three equal thirds for optimal balance and pleasing proportions to achieve a more attractive and harmoniously pleasing face, with the lips slightly open with the patient in postural head position. This is especially important for evaluation of the mid- and lower-face heights




the face horizontally into three equal thirds for optimal balance and pleasing proportions to achieve a more attractive and harmoniously pleasing face [1, 4–6] (Fig. 6.2). These imaginary reference lines allow the clinician to correctly evaluate each third of the face in terms of height and proportion [2, 4, 6].

Key Note

Dividing the face horizontally into three equal thirds allows the clinician to correctly evaluate the face in terms of height and proportion for optimal balance and an attractive and harmoniously pleasing face.


These horizontal lines determine the size and proportion of the face from the hairline of the forehead to the eyebrow line, from the eyebrow line to the lower end of the nose, and from the lower end of the nose to the base of the chin [2, 4, 5] (Fig. 6.2). These horizontal thirds should approximately be equal, although in males

Fig. 6.3 Horizontal and vertical reference lines that interfere with the facial-dental compositions for creating a pleasing smile



the third portion running from the lower end of the nose to the base of the chin might be slightly wider than other two parts when no occlusal wear is present [2, 9]. These reference lines allow the clinician to determine any structural changes on the face. In creating a pleasing smile the clinician should also use more horizontal and vertical reference lines that interfere with the facial-dental compositions, such as the interpupillary line, commissure line, lip line, midline, and facial midline [2–4, 6] (Fig. 6.3). All of these reference points are important parameters for facial esthetics, with distinct proportions and relationships with each other [3]. The most commonly used horizontal reference line is the interpupillary line, which runs between the eyes and passes through the center of the pupils [2, 6, 8, 9] (Fig. 6.3). However, it has been reported that this reference line does not correlate when the patient's eyes lie on different planes; hence, a more reliable and repeatable reference is the incisal plane (Fig. 6.4), which is perpendicular to the facial midline and does not related to the interpupillary line [7].

Fig. 6.4 The incisal plane is a more reliable and repeatable reference line that does not depend on the interpupillary line

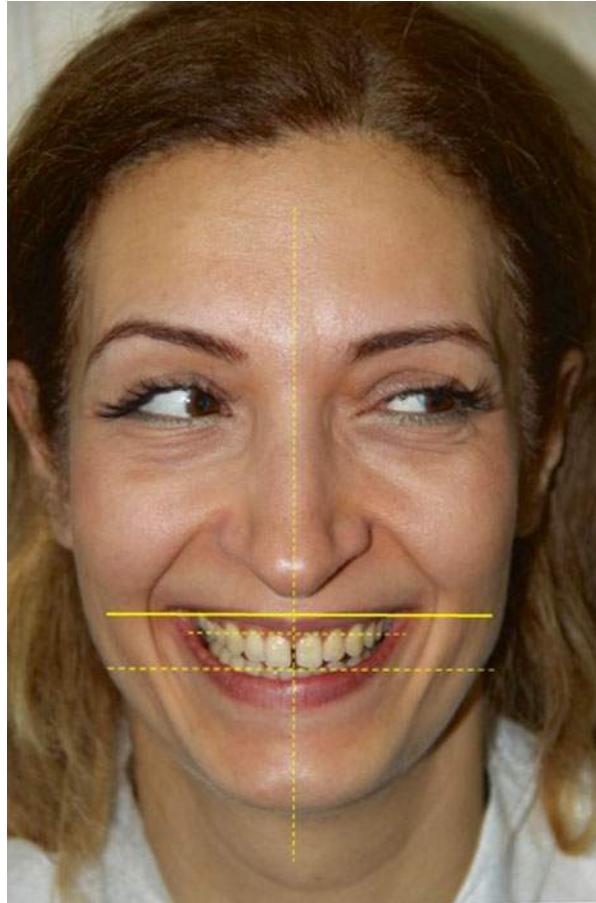


Key Note

The interpupillary line is the most commonly used horizontal reference between pupils of the patient when the patient's eyes lie on the same plane. When the eyes are on a different plane, the incisal plane should be used as reference.

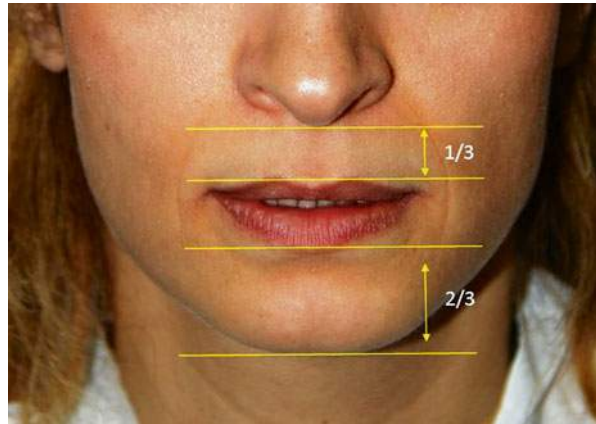
The next reference line, below the interpupillary line, is the commissural line, which passes through the connection corners of the upper and lower lips [2, 8]. This line should be parallel with the patients' occlusal and incisal plane of the teeth and the gingival margins of the upper central incisors [2, 4, 8] (Fig. 6.5). In addition, the Frankfort horizontal plane, which defines the lines between ears (porion) and eyes (orbitale), form the reference transverse plane that should also be parallel to the

Fig. 6.5 For an optimum facial esthetic, the commissural line should be parallel with the patient's occlusal and incisal plane of the teeth and the gingival margins of the upper central incisors



occlusal plane [10]. Facial disproportion and disharmony can easily be identified during examination of a patient by evaluation of the interpupillary line, incisal/occlusal line, and facial midline from the frontal aspect [6]. If any disproportion or disharmony is identified during these evaluations, the clinician should consider correction of the aforementioned facial disharmonies before moving on to correction of the teeth [4, 11]. In addition to the three equal parts of the facial height, the lower part of the face from the tip of the nose to the base of the chin can also be divided into two parts. The tip of the nose to the edge of the upper lip forms one third while the edge of the lower lip to the base of chin forms two thirds [10, 11] (Fig. 6.6). The lower third of the face can have an important effect on the facial esthetic, and the clinician should carefully analyze it not only via perioral but also for full-face evaluation [10]. By analyzing the teeth during the smile of the patient, either natural or wide, the commissural line can be judged as having a high, medium, or low and irregular arch [6].

Fig. 6.6 For a pleasing facial esthetic, the distance from the tip of the nose to the edge of the upper lip should be approximately half that of the lower lip edge to the base of the chin

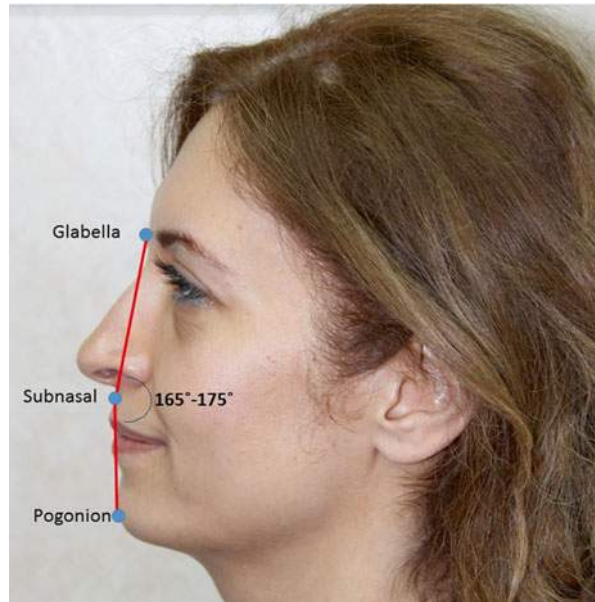


Key Note

Facial evaluation of the patient for smile analysis allows the clinician to determine vertical thirds, upper and lower arch relationships, and lip positions.

In addition to the facial evaluation of the patient for smile analysis, the lateral facial profile must be evaluated. Facial profile evaluation not only determines the vertical thirds, but also allows the clinician to determine the upper and lower arch relationships and the lip position. During this examination the clinician can work in collaboration with the orthodontist for radiographic profile analysis by using lateral cephalometric radiographs [6]. In addition, lateral cephalometric analysis (see below) allows determination of relationships of the bones in the region of face with the teeth and alveolar structures [4]. These radiographs show incisal inclination and maxillary and mandibular relationships [6, 12]. Furthermore they can be useful for analysis of the reference lines and planes to determine disharmonies in the cranio-facial region and establishment of the true horizontal plane [6, 13]. Laterally, the facial profile of a patient can be convex, concave, or straight [6, 11]. These facial profile perspectives are also important in determining tooth size and shape [11, 14]. During examination of the patient in a natural postural head position from the lateral facial perspective, the patients with dental Class I occlusion generally exhibit a convex plane, where the glabella and pogonion reference points are connected with a vertical line [5, 6] (Fig. 6.7). This analysis also allows the clinician to determine lip position and/or disposition and the relationship between eye and cheek [6]. Class I patients normally show a profile angle approximately 165–175° between glabella, base of nose, and pogonion (Fig. 6.7) [6]. Patients with Class II dental and skeletal malocclusion show a greater convex appearance in this facial profile with pogonion point visualized in the distal position, and a decreased profile angle compared to Class I [5]. If a patient has a Class III malocclusion, the pogonion reference point is

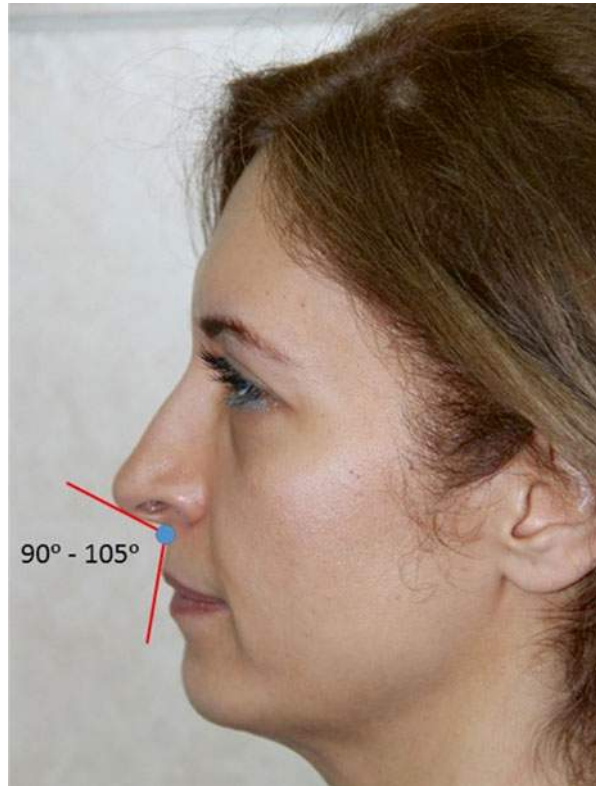
Fig. 6.7 Facial profile evaluation of the patient in natural postural head position, using the glabella, subnasale, and pogonion references. This analysis is useful for determination of lip position and/or disposition, and relationship between eye and cheek



visualized in an anterior position relative to glabella, and this appearance leads to a concave profile and increased profile angle [5, 14].

During facial profile examination, the lip positions must also be evaluated. A variety of measurements can be used for this purpose, such as the important imaginary line called the Ricketts E-plane [2, 5, 6]. This important reference describes the line from the tip of the nose to the chin, and allows the clinician to evaluate upper and lower lip position by measuring the lip distance from reference line [2, 6]. Another important measurement is the nasolabial angle between the nasal and labial lines [2, 5, 6]. The nasal line is tangential to the columella, and passes by the junction of the columella and the upper lip. The labial line is drawn from the base of the nose to the vermilion border of the upper lip. The angle between these two imaginary lines allows the clinician to determine the dental, skeletal, and soft-tissue relationships of the nasolabial unit [5, 6]. Under normal conditions, the ideal nasolabial angle between these two imaginary lines generally ranges between 90° and 105° according to gender [2, 5, 6] (Fig. 6.8). While an ideal nasolabial in men ranges between 90° and 95° , it is 95° – 105° in women [2, 5, 14, 15]. Other imaginary reference lines that can be used for facial profile evaluation are Steiner line and the Burstone line [5, 6, 13, 16, 17] (Fig. 6.9). In a harmonious and balanced profile, the upper and lower lip are in contact with the Steiner's line, which runs through the midpoint of the nose and the tip of the chin [6]. Burstone's imaginary reference line is drawn from the bottom of the nose to the tip of the chin [6]. Upper and lower lips should be positioned ahead preferably 3.5 and 2.2 mm, respectively, from this line [6]. These imaginary reference lines help the clinician form an appropriate diagnosis and treatment plan of each case in terms of ideal position of the both maxillary and mandibular teeth and alveolus [5]. All these

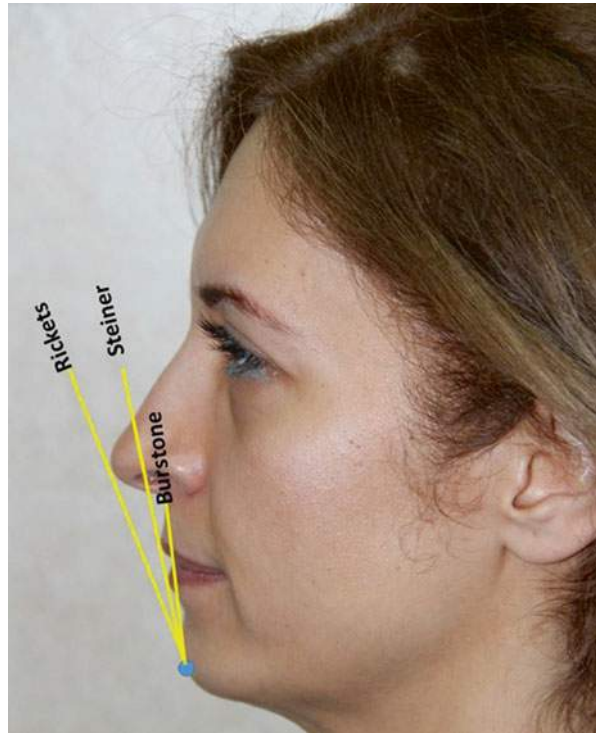
Fig. 6.8 Nasal-labial imaginary lines and constructed angle between these two lines allows determination of skeletal and dental relationships of the patient



imaginary reference lines enable the clinician to determine the alignment of the ideal facial components rapidly and without need of any radiographic assessment [1]. If any anterior or posterior lip position is detected less than ideal in reference to these lines, the patient should be referred for cephalometric analysis for a more appropriate diagnosis and potential correction treatment options for the abnormal situation [5].

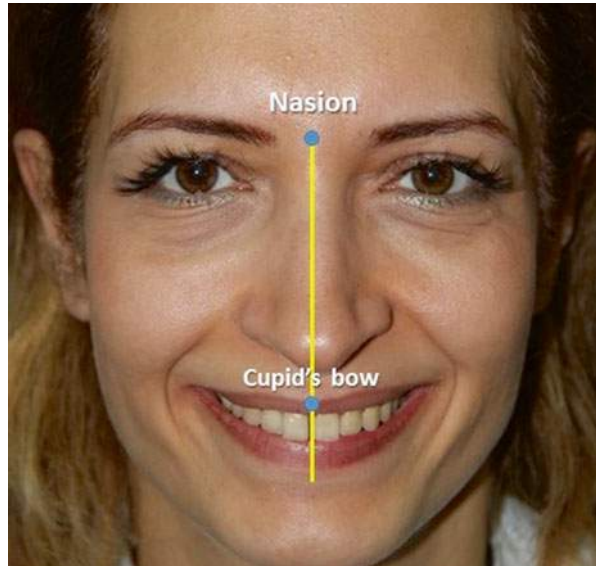
A complete facial analysis must also include vertical analysis whereby bilateral symmetry of the face is examined for smile design. The first analysis should be of facial symmetry, bearing in mind that a small degree of asymmetry is present in most individuals [9, 18]. The symmetry of the face can be analyzed using the facial midline [3–9, 11, 18]. The dental midline refers to an imaginary vertical line that passes through the contacts of the maxillary central incisors [4, 11]. The facial midline refers to a vertical imaginary line drawn from the forehead and/or glabella running to the mid region of the eyebrows, subnasal point, philtrum of the upper lip (mid region of the lip or Cupid's bow), and finally the mid region of the chin (Fig. 6.3) [3, 4, 9]. In esthetic evaluation of a patient the maxillary central incisors are the most important baseline points, and must be positioned in the center of the face [7]. However, confusion exists regarding the correct location of the facial midline [7]. Certain facial anatomical landmarks such as the interpupillary plane, nose,

Fig. 6.9 Evaluation of lip position for facial profile analysis according to the Ricketts, Steiner, and Burstone imaginary reference lines, which help in appropriate diagnosis and treatment planning in terms of ideal position of the both maxillary and mandibular teeth and alveolus



and chin are important in photographic analysis regarding location of the midline on the face [4, 7]. Ideally, the facial midline should be located in the center of the face [3]. It has been reported that both eyes and pupils can differ slightly and, due to the genetic structure of the nose or chin, can deviate from the center of the face, thus undermining these landmarks as a reference point for facial midline accuracy [4, 7]. Therefore, most accurate anatomical facial midline landmark runs from the nasion, located between the eyebrows, to the philtrum of the lip (located in the middle of the upper lip, also known as Cupid's bow) [4, 7, 11, 18] (Fig. 6.10). When an imaginary line is drawn between these two anatomical reference points, it allows the clinician to localize and most accurately position the facial midline and its direction [7]. Cupid's bow is at the center of the philtrum and matches with the upper central papilla, which is directly over the dental midline [4]. In addition, incisor embrasures of the upper centrals should be located in the middle of the maxillae and must be perpendicular to the incisal plane [19]. If Cupid's bow and upper central papilla do match with each other and the midline is positioned incorrectly, the problem is incisal inclination of the teeth [11]. If these two structures do not match with each other, deviation of the midline is suspected [11]. Some circumstances such as surgical operations on lip and cleft-lip cases can affect the correct location of the facial midline [4, 9]. In general, the dental midline is parallel to the facial midline and should be perpendicular to the incisal/occlusal plane and commissural line (Fig. 6.5) [3, 4,

Fig. 6.10 Determination of the facial midline by marking the nasion and Cupid's bow as reference points



7, 11]. Minor irregularity between the facial and dental midline are acceptable by both the observer and the patient whenever these two imaginary lines are parallel with each other [4, 5, 7, 11, 20]. If these two lines do not coincide or parallel with each other and the junction of the maxillary central incisors shows an angle or deviation, this is referred as a canted dental midline [7]. A canted midline would be more noticeable and attract attention of observers directly to the patient's mouth, and is therefore perceived as a less acceptable situation [7, 11]. It has been previously reported that whenever the dental midline was parallel with the facial midline, discrepancies of the dental midline approximately 4 mm were not perceived and noted as unesthetic by observers and did not compromise the esthetic result [21]. The clinician should always remember that: the facial midline should be located parallel with the long axis of the face; it must be perpendicular to the interpupillary line (if the eyes are symmetric) and the incisal/occlusal plane; and the dental midline should be positioned parallel to, and located as close as possible to, the facial midline [11, 18]. It has been reported that whenever upper and lower arch midline possibly correspond with each other [18], in most cases the midline did not coincide [11]. However, owing to slight visibility of the mandibular teeth compared with maxillary teeth, this discrepancy does not create an unesthetic situation for the patients [3]. In addition, with narrower and uniform size of the mandibular teeth it is difficult for observers to visualize midline contact of the mandibular teeth [3, 22]. For this reason, the clinician should always use the facial or maxillary dental midline as a reference line for smile analysis, and should not use the mandibular midline as a reference point for establishing any restoration [3, 11]. Midline corrections can be performed with restorative treatment when the symmetry of the maxillary central incisors and the correct intertooth position are presents [5]. If there is no need for

any restorative treatment for the teeth and there is a major discrepancy or canted midline, the ideal treatment would be the orthodontic [5].

To establish a correctly positioned midline for a patient and transfer these references correctly to the laboratory, the clinician can use a face bow transfer and stick bite [11, 18]. Both midline transfer techniques allow the clinician to transfer the acquired reference points correctly to the dental technician in addition to useful information regarding the laboratory communications [11].

6.1 Cephalometric Analysis

Cephalometric analysis is an essential step in the diagnosis and treatment planning in orthodontics. Measurements, made on lateral cephalometric radiographs and compared with the norms derived from the normal subjects, are used to understand the underlying basis of a malocclusion regarding components of the face on the horizontal and vertical planes. The objectives of cephalometric analysis for diagnostic purposes are to evaluate the sagittal relationship of the maxilla and the mandible in relation to the cranial base and each other, the vertical growth pattern, dental relationships, and soft-tissue facial profile. In orthodontic practice a wide variety of landmarks, reference lines, and cephalometric measurements are employed; however, this chapter focuses only on those ones of relevance to the diagnosis and treatment planning in a diastema case subject to orthodontics or an interdisciplinary approach (Fig. 6.11).

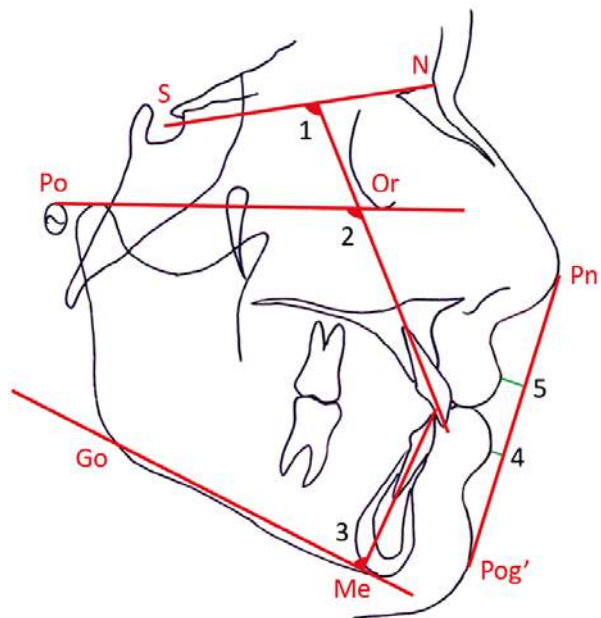


Fig. 6.11 Cephalometric measurements

6.1.1 Measurements Related to the Upper and Lower Incisors

Cephalometric evaluation of the incisor position and its relation to the skeletal basis is very important not only from the diagnostic but also from the therapeutic perspective. The position and axial inclination of the maxillary and mandibular incisors determine the treatment modality. When the incisors are overproclined on the alveolar basis (e.g., bimaxillary protrusion), orthodontic retraction of the anterior teeth to their correct position and inclination is indicated to close the diastema. If the incisors are retroclined or normally inclined, alternatives other than incisor retraction such as mesialization of the posterior teeth should be preferred, at least to maintain incisors' inclinations and positions. Cephalometric measurements related to the upper and lower incisors are:

1. Upper incisor-SN: Angle between the long axis of upper incisor and anterior cranial base (Norm: $103^\circ \pm 5^\circ$) [23]. Cranial base is called SN line passing through S (Sella: Center of the pituitary fossa of the sphenoid bone) and N (Nasion: most anterior point of the frontonasal suture in the midsagittal plane). The long axis of the upper incisor is the line running through tip and root apex of the maxillary central incisor.
2. Upper incisor to Frankfort horizontal (U1-FH): Angle between the long axis of upper incisor and line passing from Frankfort horizontal plane (plane running through porion and orbitale) (Norm: $112^\circ \pm 5^\circ$) [23]. Porion (Po) is the most superior point of the external auditory meatus, and orbitale (Or) is the lowest point in the inferior margin of the orbit.
3. Incisor mandibular plane angle (IMPA): Angle between the long axis of lower incisor and mandibular plane (Mean norm: $90^\circ \pm 5^\circ$) [24]. Mandibular plane is constructed between gonion (Go: Most convex point along the inferior border of the ramus) and menton (Me: Most inferior point of the symphysis).

Increased measurements show labial inclination, whereas decreased measurements indicate lingual inclination of the incisors.

6.1.2 Measurements Related to the Lips

The lip position is another determinant of the treatment planning because there is a close relationship between the incisors and the lips. Anteroposterior movement of the incisors leads to the positional changes in the lip to varying degrees [25–27]. Over-retraction of the incisors causes retrusion of the lips, and therefore may create dished-in profiles and detrimental, aging-like effects on the face of the patients. Thus, the clinician should always assess the lip position, thickness, and overall facial profile. When the upper and lower lips are prominent and thick, the retraction of the incisors to close the diastema will also normalize

the lip positions. However, if the lips are retruded and thin and the facial profile is straight or concave, retraction of the incisors and retrusion of the lips are contraindicated. Cephalometric measurements related to the lips are:

4. Lower lip-E plane: The distance between the most anterior point on the curve of the lower lip and esthetic plane. Esthetic plane is the line passing through pronasale (Pn: tip of the nose) and soft-tissue pogonion (Pog': most anterior point of the soft-tissue chin). Lower lip becomes more retrusive as a function of age. The norm is 0 ± 2 mm in children, -3 ± 2 mm in adolescents, and -4 ± 3 mm in adults [28].
5. Upper lip-E plane: The distance between the most anterior point on the curve of the upper lip and esthetic plane. Ideally, the upper lip is 2 mm behind the lower lip [28].

When the lip–esthetic plane distance is increased, the lip is considered retrusive and retraction of the anterior teeth should be avoided.

References

1. McLaren EA, Culp L. Smile analysis. *J Cosmet Dent.* 2013;29(1):94–108.
2. Calamia JR, Levine JB, Lipp M, Cisneros G, Wolff MS. Smile design and treatment planning with the help of a comprehensive esthetic evaluation form. *Dent Clin N Am.* 2011;55(2):187–209.
3. Gurel G. The science and art of porcelain laminate veneers. Ergolding, Germany: Carol Stream: Quintessence Publishing Co. Ltd; 2003. p. 59–109.
4. Davis NC. Smile design. *Dent Clin N Am.* 2007;51(2):299–318.
5. McLaren EA, Rifkin R. Macroesthetics: facial and dentofacial analysis. *J Calif Dent Assoc.* 2002;30(11):839–46.
6. Rifkin R. Facial analysis: a comprehensive approach to treatment planning in aesthetic dentistry. *Pract Periodontics Aesthet Dent.* 2000;12(9):865–71.
7. Morley J, Eubank J. Macroesthetic elements of smile design. *J Am Dent Assoc.* 2001;132(1):39–45.
8. Kirtley GE. The art of a beautiful smile. *J Cosmet Dent.* 2008;24(3):122–31.
9. Naini FB, Gill DS. Facial aesthetics: 2. Clinical assessment. *Dent Update.* 2008;35(3):159–70.
10. de Lima Lucas B, Junior RB, Gonçalves LC, Gavião MBD, Gomes VL. Research and clinical applications of facial analysis in dentistry. In: Mandeep Viridi, editor. Oral health care – prosthodontics, periodontology, biology, research and systemic conditions. InTech. ISBN 978-953-51-0040-9. doi: 10.5772/34702. Available from: <http://www.intechopen.com/books/oral-health-care-prosthodontics-periodontology-biology-research-and-systemic-conditions/research-and-clinical-applications-of-facial-analysis-in-dentistry>.
11. Bhuvaneshwaran M. Principles of smile design. *J Conserv Dent.* 2010;13(4):225–32.
12. Gomes VL, Gonçalves LC, Correia CL, Lucas BL, Carvalho PM. Vertical dimension of the face analyzed by digital photographs. *Eur J Esthet Dent.* 2008;3(4):362–70.
13. Viazis AD. A new measurement of profile esthetics. *J Clin Orthod.* 1991;25(1):15–20.
14. Arnett GW, Bergman RT. Facial keys to orthodontic diagnosis and treatment planning – part II. *Am J Orthod Dentofacial Orthop.* 1993;103(5):395–411.
15. Levine JB. Esthetic diagnosis. In: Current concepts in cosmetic dentistry. Chicago: Quintessence Publishing; 1994. p. 9–17.

16. Burstone CJ. Lip posture and its significance in treatment planning. *Am J Orthod.* 1967;53(4):262–84.
17. Saxby PJ, Freer TJ. Dentoskeletal determinants of soft tissue morphology. *Angle Orthod.* 1985;55(2):147–54.
18. Washe M, Hepps R, Geissberger M. Guiding principles of esthetic dentistry. In: Su S, editor. *Esthetic dentistry in clinical practice*. 1st ed. Ames: Wiley-Blackwell; 2010. p. 9–17.
19. Hoopingarner CR. Simplified smile design: everyday predictability – part I. *J Laser Dent.* 2010;18(1):19–23.
20. Latta Jr GH. The midline and its relation to anatomic landmarks in the edentulous patient. *J Prosthet Dent.* 1988;59(6):681–3.
21. Kokich Jr VO, Kiyak HA, Shapiro PA. Comparing the perception of dentists and lay people to altered dental esthetics. *J Esthet Dent.* 1999;11(6):311–24.
22. Johnston CD, Burden DJ, Stevenson MR. The influence of dental to facial midline discrepancies on dental attractiveness ratings. *Eur J Orthod.* 1999;21(5):517–22.
23. Reidel RR. The relation of maxillary structures to cranium in malocclusion and in normal occlusion. *Angle Orthod.* 1952;22:142–5.
24. Tweed CH. The Frankfort-mandibular incisor angle (FMIA) in orthodontic diagnosis, treatment planning and prognosis. *Angle Orthod.* 1954;24:121–69.
25. Rudee DA. Proportional profile changes concurrent with orthodontic therapy. *Am J Orthod.* 1964;50:421–34.
26. Lo FD, Hunter WS. Changes in nasolabial angle related maxillary incisor retraction. *Am J Orthod.* 1982;82:384–91.
27. Ramos AL, Sakima MT, Pinto Ados S, Bowman SJ. Upper lip changes correlated to maxillary incisor retraction – a metallic implant study. *Angle Orthod.* 2005;75:499–505.
28. Ricketts RM. Perspectives in the clinical application of cephalometrics. *Angle Orthod.* 1981;51:115–50.

Taner Yucel, Esra Yildiz, and Ugur Erdemir

Abstract

Evaluation of the lips during the smile is important in dental-facial analysis, as the lips frame the mouth. The upper lip is especially important and has a significant effect on the esthetic treatment plan and smile design process, as it reveals the number of visible teeth and gingiva when the patient's lips are at rest, and while smiling and speaking. Evaluation of the lips ideally should be performed while they are at rest and while smiling for the correct determination of the ideal maxillary incisal edge position. Maxillary central incisors are the key element in smile analysis; hence, proper determination of the incisal edge position provides reference points for evaluation of tooth proportions, gingival level, and gingival structure, and their inter-relationships.

After a detailed and comprehensive facial evaluation of the patient for smile analysis, the next step is evaluation of the lips and their relationships both with each other and the face, an important aspect of dental-facial evaluation. Lips are important for the smile, as they frame of the mouth and influence the borderline of the smile design [1]. The upper lip is especially important and has a significant effect on the esthetic treatment plan and smile design process, as it reveals the visible number of teeth and gingiva while a patient's mouth is at rest, smiling, and speaking [2] (Fig. 7.1a, b). Therefore, ideally this evaluation process should begin with the static lip position at rest, then while smiling, with determination of the ideal maxillary incisal edge position during lip movement [3] (Fig. 7.1a, b). Evaluation of the incisor edge position of maxillary centrals is the most important criterion for smile analysis which, if determined properly,

T. Yucel, PhD, DDS (✉) • E. Yildiz, PhD, DDS • U. Erdemir, PhD, DDS
Operative Dentistry, University of Istanbul Faculty of Dentistry, Istanbul, Turkey
e-mail: t_yucel@superonline.com

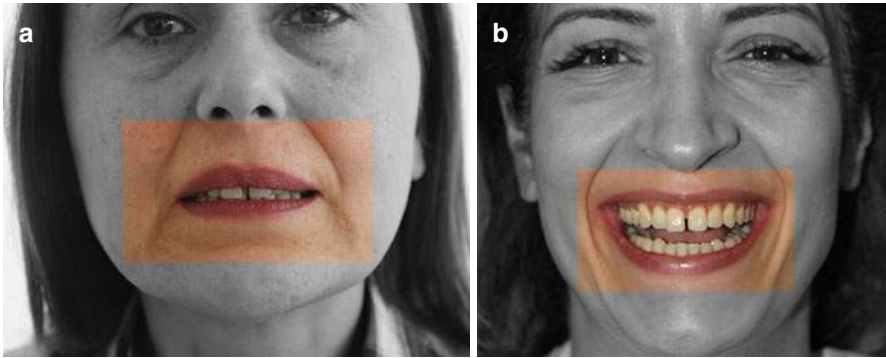


Fig. 7.1 (a, b) Lips are important for the smile design as they frame of the mouth. Upper lip is especially important in the smile design process, as it reveals the visible amount of teeth and gingiva while the lips are at rest and smiling

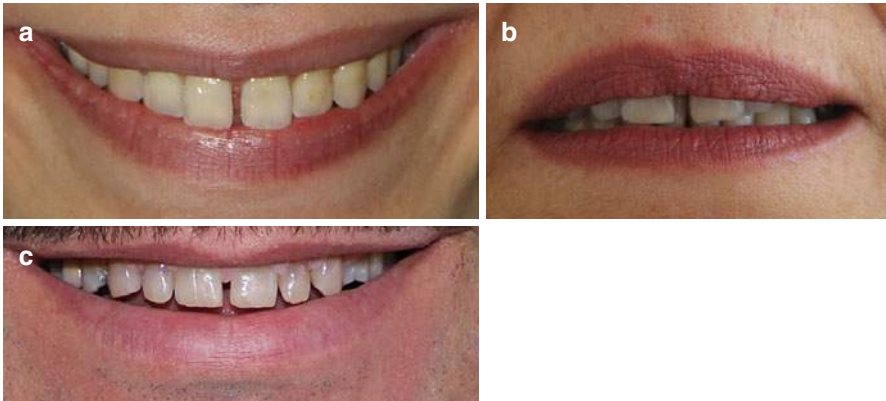


Fig. 7.2 (a–c) Evaluating the incisal edge position at rest and smiling is important for further oral esthetics

serves as a reference point for further evaluations such as appropriate tooth proportions, level of gingival structure, and their inter-relationship [4, 5] (Fig. 7.2a–c). For a suitable analysis of the aforementioned criteria, lip length should be measured. Lip length runs from the subnasale to the border of the upper lip, and should be for male patients around 22 ± 2 mm and for females around 20 ± 2 mm [6, 7] (Fig. 7.3). Lip thickness, which can be measured using cephalometry, increases from childhood to adolescence and then decreases according to age [6, 8]. However, during evaluation of these criteria for smile analysis the clinician should consider both patient age and tooth wear, as they affect the tooth proportions and the visibility of tooth structure at rest, owing to shortening of the gingivo-incisal length and the loss of lip mobility over time [2, 5] (Fig. 7.4a, b). Lip mobility and morphology should be carefully determined during clinical examination [1]. The position of the teeth on the arch, alveolar structures,

Fig. 7.3 Lip length can differ depending of gender, measuring for male patients around 22 ± 2 mm and for females around 20 ± 2 mm

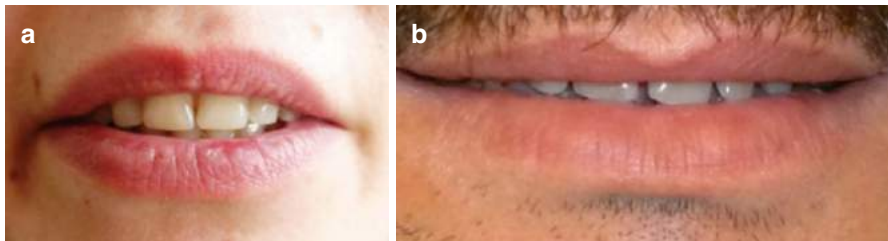
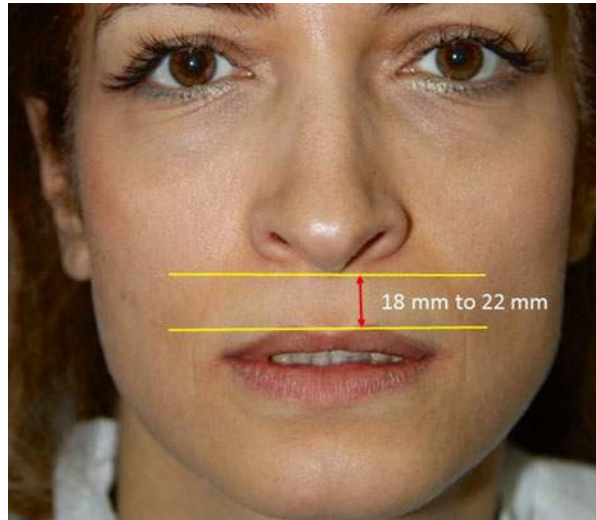


Fig. 7.4 Patients' age and tooth wear can affect the visibility of tooth structure at rest. (a) Visibility of tooth structure at rest for a 20-year-old patient. (b) Visibility of tooth structures at rest for a 50-year-old patient

and relationship between the upper and lower arch all effect the contour of the lips [1]. Increased overjet whereby diastema can be seen, deep bite, and occlusions of class I, II, and III can influence the shape of the lips. In general the upper lip is wider than the lower lip and, because of overlap of the upper arch on the lower one, the upper lip is usually longer than the lower lip when the teeth are properly aligned [1] (Fig. 7.5). Therefore, the lower lip is found to be in a recessed position under the upper lip when the arches and teeth are correctly aligned [1]. During evaluation for smile analysis, the lip morphology, involving width, volume, and symmetry of the lips, should be carefully evaluated. Width of the lips is related to width of the smile, and lip volume can be categorized as full, average, or thin [1]. The clinician should record all of these parameters for smile analysis and future controls. Upper and lower lip should carefully evaluated independently for both symmetry and volume. In smile analysis the lips should be symmetrically located on the left and right sides of the midline, and should have approximately the same degree of volume [1]. If there is any asymmetry or differences in volume and there is no dental treatment option, the patient should be referred to a

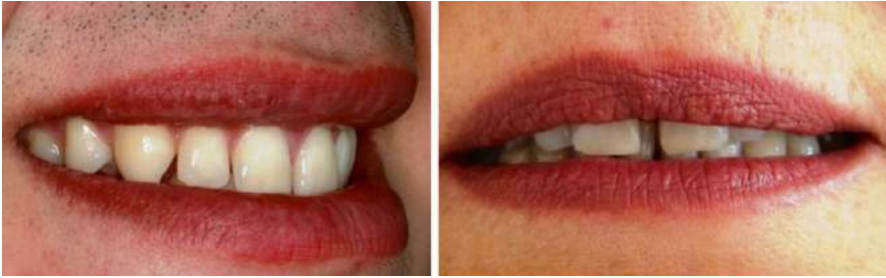

Fig. 7.5 In general the upper lip is wider and longer than the lower lip where the teeth are properly aligned compared with the lower lip

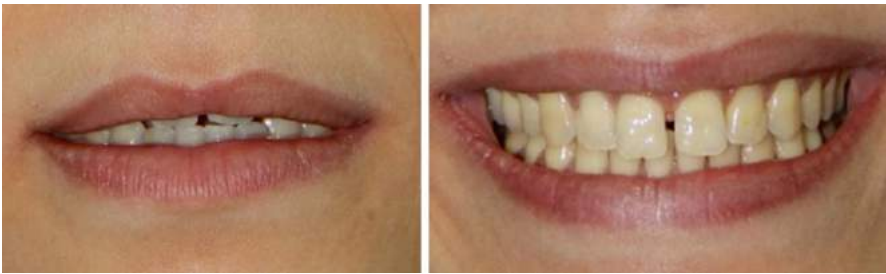

Fig. 7.6 Lip mobility or movement of the upper lip is an important determinant for exposure of the teeth and gingival structures

specialist for detailed evaluation of etiology and treatment options for the correction of the abnormality. Lip volume can demonstrate differences among patients of differing ethnicity, and any deficiency in volume can result in a short lip [6]. Therefore, it is important to evaluate the lip morphology and length for smile analysis; in the event of abnormality other than the age-related changes, various treatment options should be considered before proceeding to restorative procedure [6]. Lip positions, especially the upper lip position, are important in evaluation during static (at rest) and dynamic (smiling) positions. Lip contacts and mobility are also carefully evaluated when smiling and at rest [1]. Lip mobility or movement of the upper lip is an important determinant of exposure of teeth and gingival structures in analysis of the smile (Fig. 7.6) [1, 9]. Under normal smile conditions the average lip mobility should be around 7–8 mm [10]. This evaluation helps clinician to determine the incisal edge position and the need for crown lengthening or gingival contouring before initiation of any restorative treatment [9].

7.1 Incisal Edge Position

Incisal edge position refers to the visible tooth structure when the lips are at rest (Figs. 7.2b and 7.4a, b) [1, 5], and varies depending on age and sex [1, 2, 4, 5, 9, 10]. Besides age and gender of the patient, evaluation of the upper lip length and

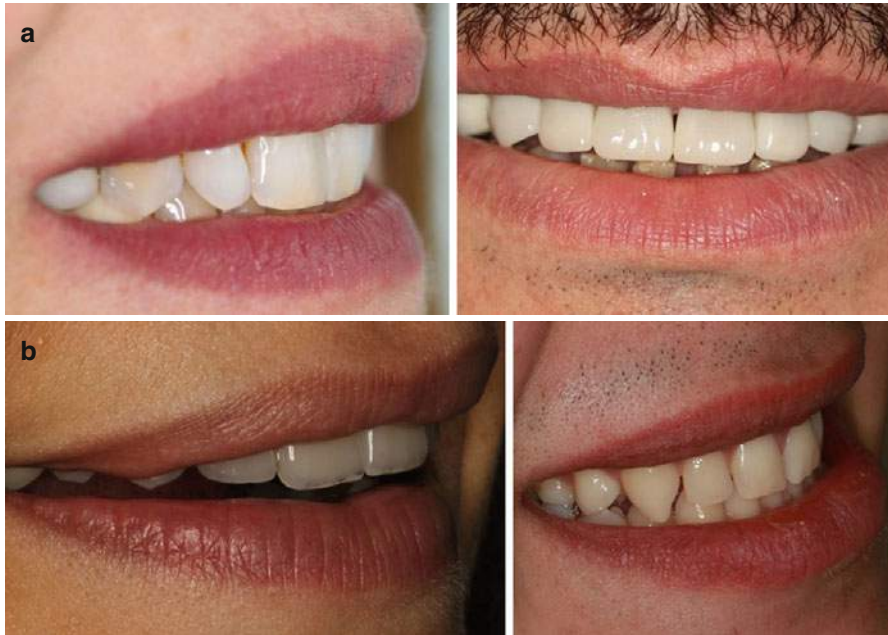

Fig. 7.7 For creation of an ideal smile, incisal tip of the maxillary canines (a) should slightly touch the lower lip or (b) come fairly close to the lower lip during smiling

curvature help to determine the incisal edge length [5]. There are conflicting reports in the literature regarding the incisal edge position of the maxillary centrals [1–5, 9–11], although most authors report that an average visible tooth structure of 2–4 mm when the lips are at rest is esthetically pleasing [2, 3, 10–13]. In younger patients (Fig. 7.4a) the visible tooth structure tends to be more extensive than in older patients (Figs. 7.2b and 7.4b), and it has been reported that this can vary depending on ethnicity [6, 13, 14]. While a younger female patient around 20 years of age displays 3–5 mm of maxillary incisal edge at rest with no visible mandibular teeth [5], a male patient of the same age can display 1–2 mm less incisal edge [14]. In addition, aging leads to a diminution in muscle tonus and occurrence of tooth wear, and the visible maxillary incisal edge decreases; for instance, a 45–50-year-old male patient may not show any maxillary incisal edge at rest, whereas a woman of the same age may display a slight amount [13, 14] (approximately 1–1.5 mm) [2] while the amount of mandibular incisal display increases [1, 5, 13]. Therefore, in creating an esthetically pleasing and youthful smile, the amount of maxillary central incisal edge on display is an important factor in smile design procedure [1]. Another important guide for evaluation of incisal edge position of the maxillary anterior teeth and creation of an ideal smile is that while smiling, the incisal tips of the maxillary canines should slightly touch (Fig. 7.7a) or come fairly close to the lower lip (Fig. 7.7b), and in the same position the maxillary incisors should be approximately 2–3 mm away from touching the lower lip [10, 12, 15]. However, curvature of the

Fig. 7.8 Patient exhibiting less than 3–4 mm maxillary incisal edge display at rest (Fig. 7.4b), and incisal lengthening by adding temporary acrylic resin in to the incisal edge of the teeth using silicone matrices prepared form diagnostic wax-up model

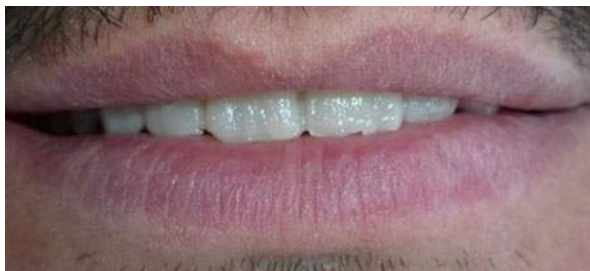
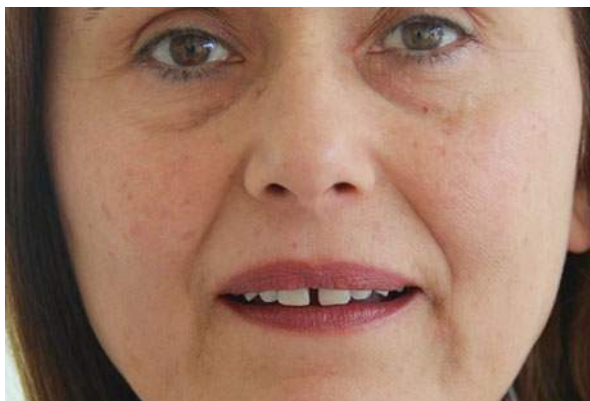
Fig. 7.9 After repeatedly saying the letter “M” and then keeping the lips at rest allows the clinician to determine the incisal edge position of the maxillary central teeth

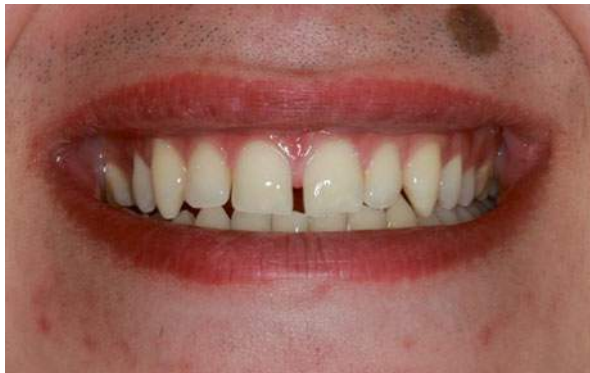

lower lip can affect the achievement of this ideal smile position [10, 15]. During smiling, maxillary premolars normally are displayed in the frame of the lips, and in some patients with longer lips the first molars can also be displayed.

If during clinical examination insufficient or too much tooth display is observed during smiling, the clinician must determine the tooth length and position. If maxillary incisal edge display at rest position is less than 3–4 mm (Fig. 7.4b), lengthening of incisal edge of the teeth by composite addition should be considered [10, 12]. Clinician can observe the changes on the patient's face and communicate with the patient on the proposed changes by using temporary resins for this purpose (Fig. 7.8) [10]. If maxillary incisal edge display is normal (3–4 mm) at rest and the length of the crowns are visualized as too short, the clinician must consider a crown-lengthening procedure to achieve normal tooth length [10]. Before the crown-lengthening procedure, proposed changes on the gingival tissue and teeth can be shown to the patient by adding composite resin over the current gingival margin.

To help determine the correct incisal edge position at rest, the clinician can use phonetic guidelines by repeating several letters [1, 2, 4, 5]. While sitting in the postural head or upright position the patient is asked repeatedly pronounce the letter “M” and keep the lips relaxed, whereby the clinician can determine the incisal edge position of the maxillary central teeth at this resting position (Fig. 7.9) [2, 3, 5, 11]. After this repeated pronunciation is interrupted, the upper and lower lips return easily to the relaxed position for assessment [5]. In this position the clinician can

Fig. 7.10 Pronunciation of extended “E” sound, such as saying “cheese,” allows the clinician to evaluate the incisal edge position of the maxillary anteriors and the incisal line



examine the amount of visible maxillary and mandibular teeth at the incisal edge, which can differ according to the age of the patient [11]. By this phonetic examination the clinician may consider crown lengthening either apically or incisal, according to the visible tooth structure at rest, while preserving the width-to-length ratio and paying attention to occlusion [2]. As previously described, the amount of maxillary incisal display depends on the age of patient, tooth wear, and upper lip length, and varies from patient to patient [1, 5, 6, 13, 14].

Another important phonetic examination in smile analysis is the use of the “E” sound [4, 5, 11, 16]. Pronunciation of “E” by the patient shows widest smile (Fig. 7.10), which allows evaluation of the incisal edge position of the maxillary anteriors and the incisal line [4, 5, 11, 16]. By having patient say “E” without interruption, e.g., “eeeeee” [5] or “cheeeese,” the clinician can examine the incisal edge in this maximum extension position of the lips [11]. Maxillary central incisor edge should come close to the upper border of the lower lip during this examination [16]. For an esthetically pleasing smile, the incisal edge of the maxillary teeth should be positioned halfway between the upper and lower lip during uninterrupted pronunciation of “E” (Fig. 7.11) [4, 5, 11]. Loss of muscle tonus caused by aging and tooth wear can affect the visibility of the teeth during the pronunciation of the extended “E” sound, and results in less or no incisal edge display [13, 14, 16].

“F” and “V” sounds are also important in determining the maxillary central incisal edge [2, 4, 5, 16]. When the patient correctly pronounces the “F” and “V” sounds, the incisal edge of the maxillary anterior teeth should come in slight contact with the wet-dry line or vermilion border of the lower lip (Fig. 7.12a, b) [2, 4, 5, 16]. By having the patient produce these sounds, the maxillary anterior teeth lightly press on the lower lip and partially block the air passage [5], thus helping to correctly determine the labiolingual position and length of the maxillary anterior teeth [4, 5]. In another approach, correct labiolingual positioning of the maxillary anterior teeth by placing the incisal edges on the wet-dry border of the lower lip allows the patient to correctly pronounce “F” and “V” [5, 17].

Pronunciation of the “S” sound is also an important parameter in determining the incisal edge of the maxillary centrals and the correct vertical height

Fig. 7.11 Positioning the incisal edge of the maxillary teeth halfway between the upper and lower lip during uninterrupted pronunciation of the letter “E” creates an esthetically pleasing smile

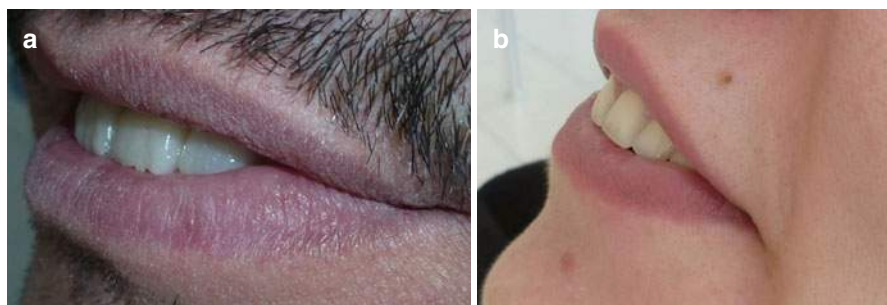
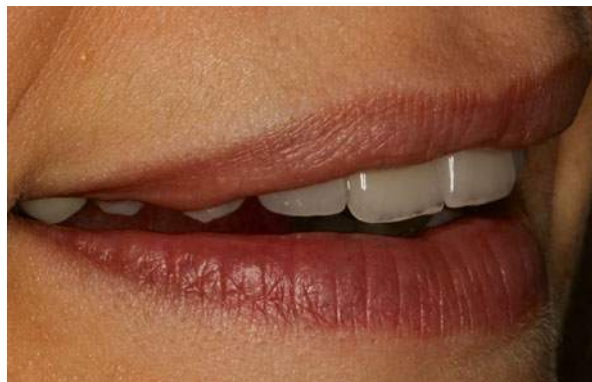
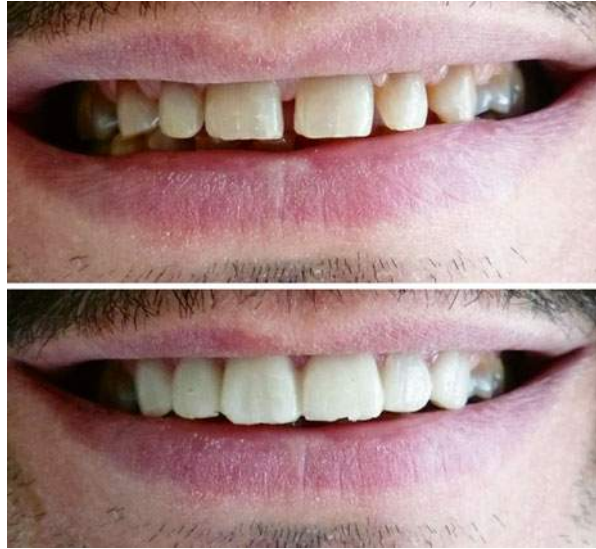
Fig. 7.12 Phonetic evaluation of the patient during pronunciation of the “F” sound for determination of incisal edge of the maxillary centrals. (a) Phonetic evaluation with the temporaries. (b) Phonetic evaluation without temporaries

dimensions [4, 5, 16]. During pronunciation of the “S” sound the mandibular central incisors are positioned 1 mm behind and 1 mm below the maxillary incisal edge, the teeth being slightly in contact (interocclusal position) (Fig. 7.13) [4, 5]. Correct incisal edge position is important, as it is related to the inclination of the maxillary anterior teeth, labial and lingual contours, anterior guidance, and tooth display [4]. Inclination of the maxillary anterior teeth greatly affects the labial and lingual contours, anterior guidance, and incisal edge position. As a result, all these factors have important roles in the esthetic and functional aspects of the final restorations [4]. These clinical guidelines are subjective, and should be used as basic principles to determine appropriate incisal edge positioning of a particular patient [3]. For correct evaluation of the case and a natural, functional, and esthetically pleasing outcome, the clinician also should use composite mock-ups, provisional composite or acrylic restorations, diagnostic wax set-ups, and digital imaging in communication with the patient, multidisciplinary team members, and dental technicians. Composite mock-ups and provisional restorations can be helpful in determining the correct incisal edge position for the final restorations.

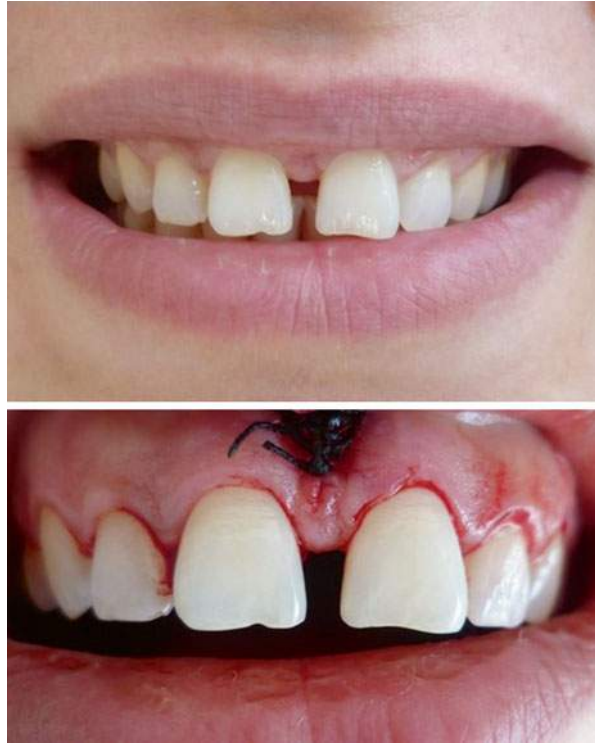Fig. 7.13 Evaluation of the patient during pronunciation of the “S” sound with and without temporaries for determination of incisal edge of the maxillary centrals



7.2 Incisal Display

Position and size of the teeth, lip length, and lip mobility are the most important factors affecting maxillary incisal display [12]. As previously described, lip length differs according to gender and the reference measure from subnasale to the border of the upper lip (Fig. 7.3), and can be measured as between 18 and 24 mm [6, 7, 10, 12]. Under normal smile conditions the average lip mobility has been reported at around 7–8 mm [10, 12]. At rest, the maxillary incisor display should be between 2 and 4 mm, and while smiling all of the maxillary anterior teeth and premolars should be displayed with approximately 1–2 mm gingival exposure [10, 12, 18]. Kokich et al. [19] reported that a smile can be considered esthetically pleasing when there is 2 mm of gingival exposure in a full smiling condition (Fig. 7.10). McLaren and Cao have also reported that up to 3 mm of gingival exposure can be considered esthetic when there is slightly more than 8 mm of lip movement during full smiling [12]. In certain situations the clinician should consider correction of the incisal display by a crown-lengthening procedure, either apically or incisal. Sometimes a patient can have a normal incisal display between 2 and 4 mm at rest but with teeth shorter than normal; in this case surgical crown lengthening apically should be considered to obtain correct tooth proportions (Fig. 7.14) [10, 12]. Before initiation of a surgical operation for crown lengthening, the clinician can add resin composite on the tooth surface and the gingiva beyond the current gingival margin to evaluate correct tooth proportions and demonstrate the esthetic appearance to the patient (Fig. 7.15a–c). This extended resin composite beyond the current gingival margin can also help to evaluate the appropriate gingivectomy by drawing the resin composite border. Before any surgical crown lengthening it is important to consider the

Fig. 7.14 Patient exhibiting enlarged labial frenum with the short clinical crown. Surgical frenectomy and apical crown-lengthening procedure to obtain correct tooth proportions



crown-root ratio and the possibility of root dentin exposure [12]. Dentinal exposure is especially important for the bonded porcelain laminate veneers, as it can greatly affect the bond strength of the restoration and cause microleakage. If the surgical crown lengthening might lead to dentinal exposure, orthodontic correction of the situation should be considered [12]. If incisal display is less than 3–4 mm at rest and the maxillary anterior teeth need to be lengthened, the clinician should consider crown lengthening incisally by adding resin composite to the incisal edge of the teeth (Fig. 7.13) to show the current esthetic appearance to the patient [10]. If there is 3–4 mm or more gingival display during normal smiling, which can be termed a “gummy smile,” periodontal and/or orthognathic surgery is usually required to achieve a satisfactory result [4].

7.3 Smile Line

The smile line is another important parameter in creating an attractive and pleasing smile. The smile line refers to an imaginary line drawn on the incisal edges of the maxillary anterior teeth, and ideally this line should follow or match the convex curvature of the lower lip during smiling (Fig. 7.16) [1, 2, 4, 5, 10, 12]. Another landmark for the smile is that the maxillary centrals should be aligned

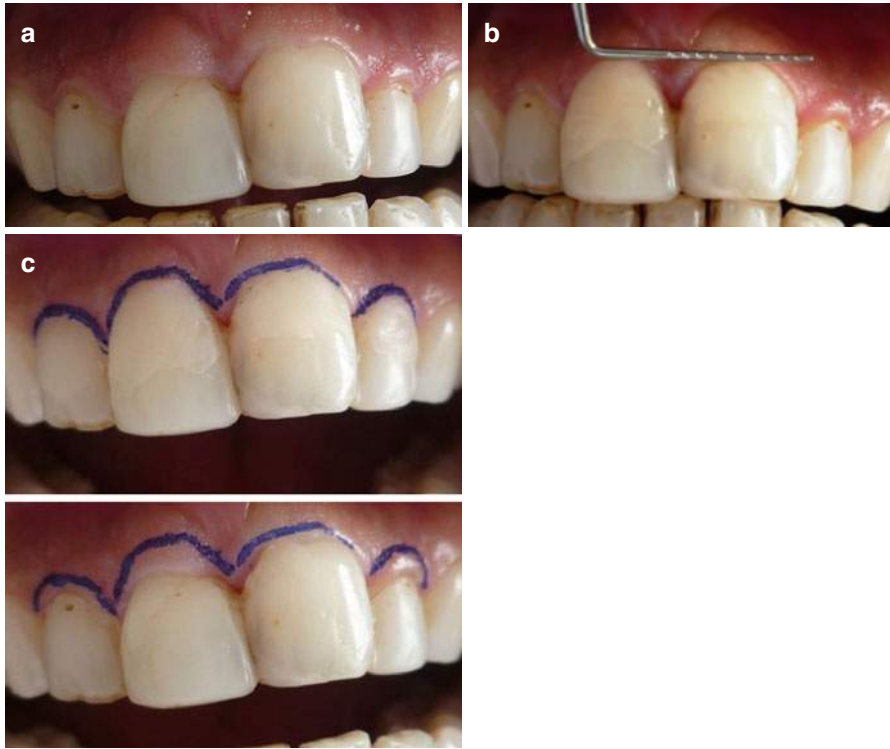


Fig. 7.15 Crown-lengthening procedure by adding composite resin on the gingiva beyond the current gingival margin. (a) Current situation. (b) Adding composite resin beyond the gingival margin. (c) Drawing of the composite resin border for correct gingivectomy

Fig. 7.16 The smile line refers to an imaginary line drawn on incisal edges of the maxillary anterior teeth (*blue line*), and ideally this imaginary line should follow or match the convex curvature of the lower lip (*red line*) during smiling

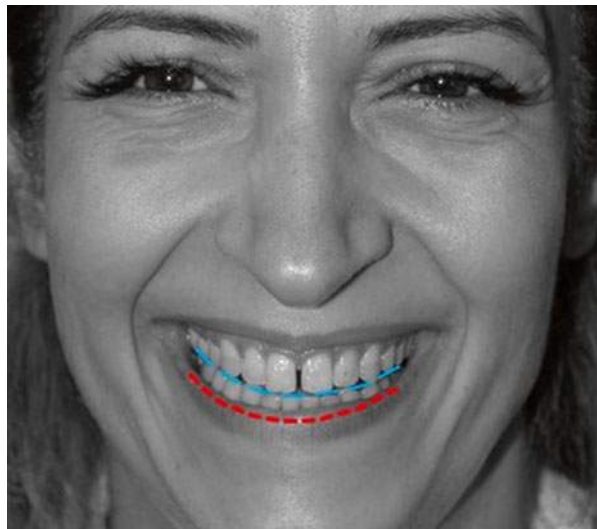


Fig. 7.17 Maxillary centrals should be aligned with or appear at least slightly longer than the canines along the incisal plane on the arch

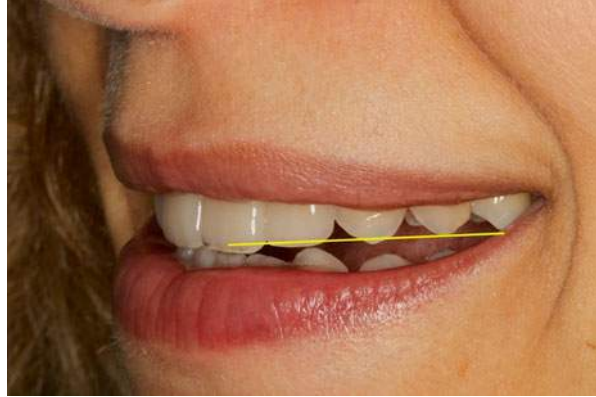
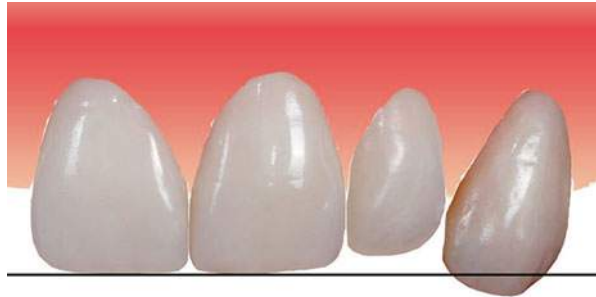
Fig. 7.18 Schematic illustration of “reverse smile line” whereby the edges of the maxillary canines and premolars appear longer than the centrals



with or at least appear slightly longer than the canines and premolars along the incisal plane on the arch (Fig. 7.17) [1, 4]. In some patients the reverse can be found and is known as the “reverse smile line” whereby the edges of the maxillary canines and premolars appear longer than the centrals (Fig. 7.18), creating disharmony on the maxillary incisal edges, and does not follow the curvature of the lower lip, creating an unesthetic and non-pleasing smile [1, 2, 4]. An imaginary line drawn on the incisal edge of the maxillary anterior teeth should be parallel with the line drawn between the pupils of the eyes where the eyes of the patients are on the same plane [1]. If the interpupillary line is not on the same plane, to achieve a reliable and repeatable position, facial midline which is perpendicular to the incisal edge plane of the maxillary anterior teeth should be the reference line [1, 11]. Once the guidance of the smile line is determined by the clinician, the curve or shape can be correctly designed [1, 11].

Small deviations in the smile line can be treated effectively by esthetic restorative treatments [10, 12]. If tooth form and length are ideal but discrepancies are observed in tooth display and smile line, the ideal treatment option would be orthodontic treatment to correct the situation instead of esthetic restorative procedures [10, 12].

7.4 Buccal Corridor

Another esthetic consideration in smile design when evaluating the patient is the “buccal corridor” or “negative space” where lips and teeth play an important role [1, 2, 4, 10, 12, 18]. This negative, dark space forms bilaterally (Fig. 7.19) between the commissures of the lips (corners of the mouth) and the buccal surface of the maxillary posterior teeth (generally premolars and molars) while the patient is smiling [1, 2, 4, 18]. During a broad smile, narrow arch form and wide lip extension create this negative space on the maxillary posterior area, and can cause a shadow-like appearance in this region [1, 2, 4, 12]. However, patients with a wider arch form and narrower lip extension can create less or minimal negative space (Fig. 7.20) on the maxillary posterior area [2, 12], reportedly an esthetically pleasing appearance [20]. In the same situation, a broad smile with no negative space can also be formed but perceived as “fake” [12, 15]. It has been reported that the buccal corridor does not have a direct impact on the overall esthetic evaluation of a smile and, hence, filling of the buccal surface by increasing the maxillary posterior teeth contours with restorative materials or restorations should be decided by the clinician according to each individual case [2, 12, 21]. In creating a pleasing natural smile the position of the maxillary canine teeth is also important, as they are located on the corner of the arch and support the lip [5]. In addition, canines are also an important influence on the size and characteristics of the buccal corridor during the smile, and the position

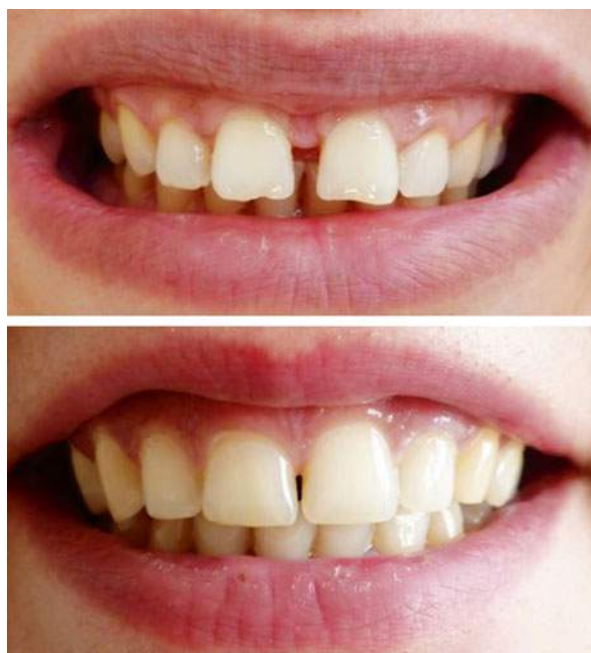
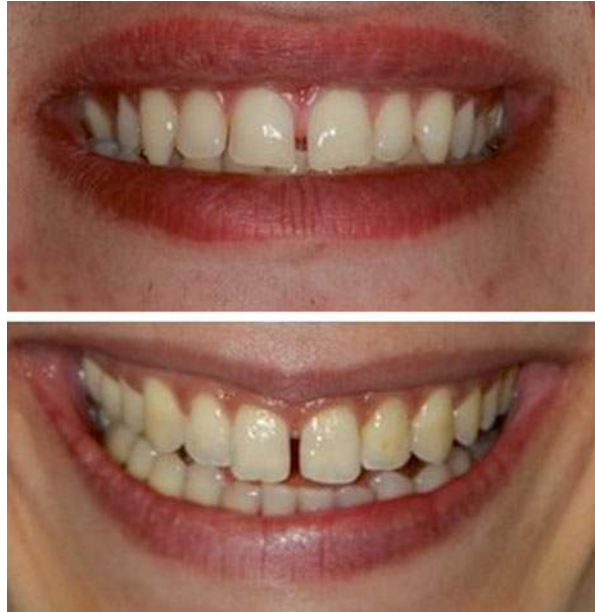
Fig. 7.19 Examples of the buccal corridor deficiency. Shadow appearance of the teeth distal to the canines while the patient is smiling

Fig. 7.20 Patients with less or minimal negative space on the maxillary posterior area



and size of these teeth directly affect the buccal corridor [5]. Increasing the posterior maxillary teeth contours should be fulfilled to a reasonable amount because overcontouring the buccal surface can increase plaque accumulation and potentiate gingival health problems [10, 12]. If increasing the buccal surface of the maxillary teeth by restorations will lead to an esthetically unpleasant outcome, orthodontic treatment should be considered [12]. The buccal corridor or negative space should not be completely eliminated; it is essential for the clinician to create a full and symmetric negative space for an esthetic smile [1].

Appearance of the buccal corridor is influenced by several factors, such as broad smile and maxillary arch, facial muscular tonicity, position of the maxillary premolars on the arch, protrusion of the maxillary canines on the arch, and discrepancies between the value of premolars and anterior teeth [1, 4].

After a detailed dentolabial analysis is accomplished, the clinician must evaluate gingival soft tissue and tooth relationships, another important parameter in framing the teeth. In an esthetically pleasing smile, proper gingival relationships with the teeth and inter-relationships of all these factors with the lips are critical esthetic elements to be determined [10], as gingival architecture may vary among patients [9]. Patients with a high lip mobility can display an excessive amount of gingival structure during smiling [2], and a high lip line, gingival symmetry, and contours are important evaluation criteria for determination of tooth length and proportions [10, 12]. In an esthetically pleasing smile, gingival contours of the maxillary teeth should be symmetric and the marginal gingival line should be relatively parallel with the horizontal reference line that extends from bicuspid to contralateral bicuspid [1, 4, 10, 12]. In addition, the marginal gingival level of the anterior teeth should be

Fig. 7.21 Marginal gingival level of the anterior teeth should be symmetrically located on both sides of the midline, and the laterals should be positioned incisally slightly below that of the horizontal line for esthetic perception

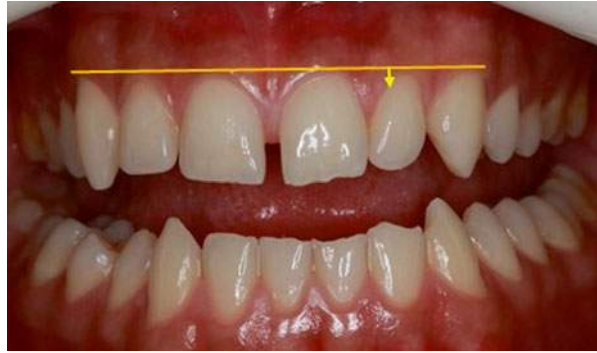


Fig. 7.22 Patient showing maxillary lateral incisors relatively on the same gingival level as the centrals can also be acceptable

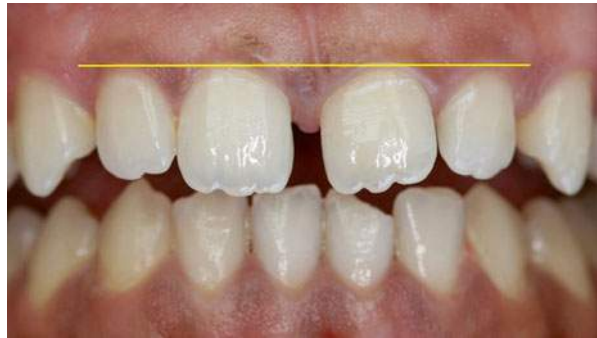
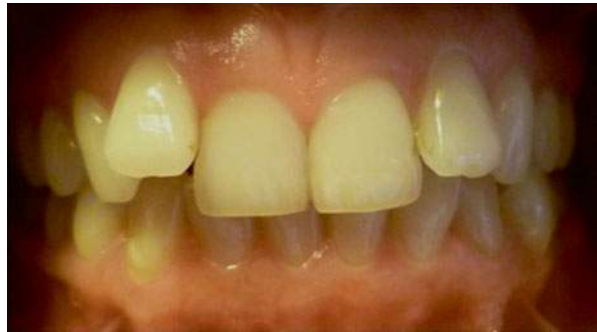
Fig. 7.23 An example of the more apically positioned maxillary laterals compared with centrals and canines, which creates an unattractive smile



symmetrically located on both sides of the midline [10, 12]. Ideally the laterals should be positioned incisally and/or slightly below that of the horizontal line for esthetic perception (Fig. 7.21) [1, 4, 10, 12]. It is also reported as acceptable, but not ideal, when the laterals are on the same gingival level as the maxillary centrals (Fig. 7.22) [1, 4]. However, when the laterals are positioned more apically than centrals and canines, the smile is considered unattractive (Fig. 7.23) [1]. It has been reported that when horizontal gingival symmetry is maintained, positioning of the lateral incisors slightly apically (0.5 mm) and 1 mm incisal relative to the maxillary

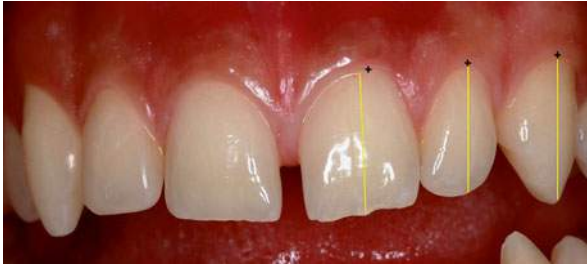

Fig. 7.24 The gingival zenith point is the most apical point of the clinical crown along the long axis of the tooth at the cervical margin. Zenith point for the maxillary central incisors is generally located 1-mm distal to the midline (*plus sign*) or long axis of the tooth, and for the lateral incisors and canine at the midline (*yellow lines*)

centrals and canines are generally perceived as esthetic [10, 12]. Achieving gingival symmetry in the treatment of diastema closure and in any esthetic restorative treatment is important for creation of a pleasing smile. Within this context, gingival zenith points are an important consideration in diastema closure. The gingival zenith point is the most apical point of the clinical crown along the long axis of the tooth at the cervical margin [1, 4, 5, 22]. Its shape and position is determined by the root form anatomy, tooth contour, tooth position on the arch, the cemento-enamel junction, the osseous crest, and health of the gingival attachment [5, 22]. Literature has reported that under normal anatomic conditions, the location of the zenith point for the maxillary central incisors is 1 mm distal to the midline or long axis of the tooth and is located at the midline for the lateral incisors and canine (Fig. 7.24) [1, 4, 5, 22, 23]. Creation of a natural esthetic restoration and establishing the properly located zenith point in diastema correction is a crucial step [4, 5]. During diastema correction with porcelain laminate veneers, if the zenith points of the teeth are not moved properly to the mesial direction from their originally existing positions, the final restorations will be perceived as mesially tilted on the arch (Fig. 7.25) [5]. In addition, it is important to provide bodily movement illusion toward the midline to reduce an exaggerated triangular form of the teeth [4, 5].

Before initiation of any restorative treatment, gingival structures must be healthy in color and contour, and the texture of the gingiva should appear normal for long-term success and esthetic outcome of the final restoration [1, 4]. The relationship between the teeth and the surrounding soft tissue, the lip and face of the patient is of paramount importance in esthetic restorative procedures [1, 4, 12]. The appearance of healthy gingival structure must be pale pink in color [1, 4, 12] (Fig. 7.26) and must show 3 mm depth of free gingiva above the alveolar crestal bone [1, 4], papillary contours should fill interdental spaces fully, and create interdental gingival embrasures without creation of a black triangle [1, 4]. Gingival contours of the maxillary anterior teeth from the facial point of view should follow a scalloped appearance (Fig. 7.26), and the tip of the interdental papilla should be located between 4 and 5 mm from the crest of the gingiva [4, 10, 12]. Ideally the volume of the interdental papilla formation should be between 40 and 50 % of the length of the

Fig. 7.25 (a) If the zenith points of the teeth are not moved properly toward the mesial direction from their originally existing positions, (b) the final restorations will be perceived as mesially tilted on the arch

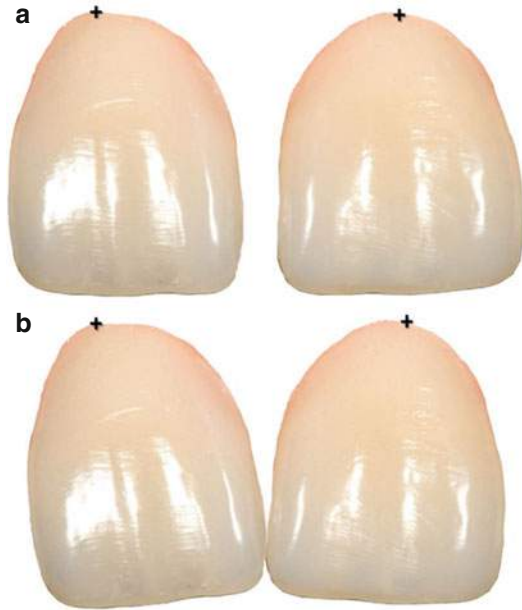
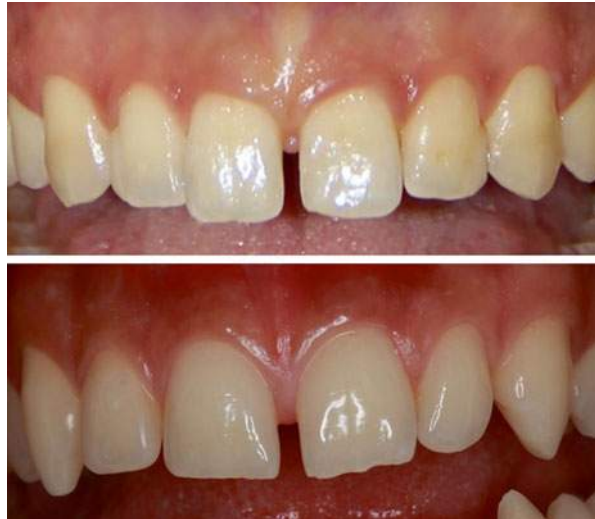

Fig. 7.26 Appearance of healthy gingival structure must be pale pink in color, not exhibiting any inflammation



maxillary anterior teeth and should fully fill the gingival embrasures (Fig. 7.27) [10, 12]. If any of these situations does not exist, correction of the gingival structures can be accomplished by periodontal and/or orthodontic treatment procedures [10, 12, 22]. Periodontally, gingival structures can be corrected by periodontal surgery to achieve ideal position, either by crown-lengthening procedures or gingival grafting and/or repositioning of coronal soft tissue [22]. Gingival structures, bone

Fig. 7.27 Ideally the volume of the interdental papilla formation should be between 40 and 50 % of the length of the maxillary anterior teeth

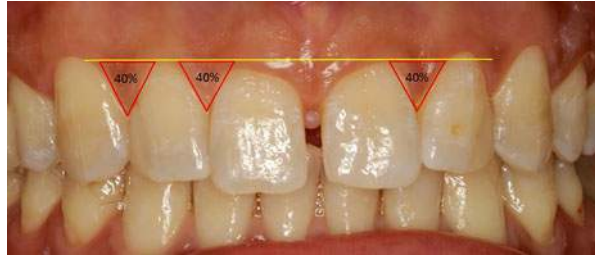
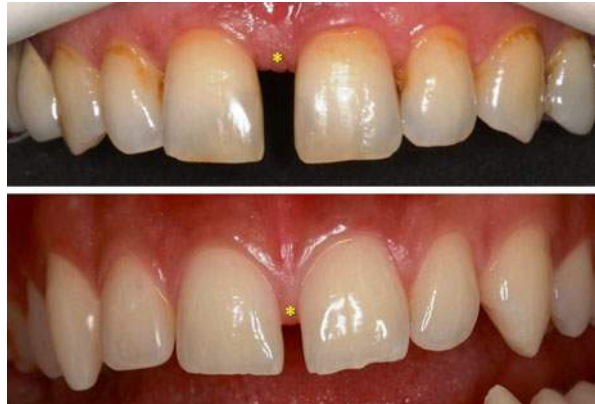
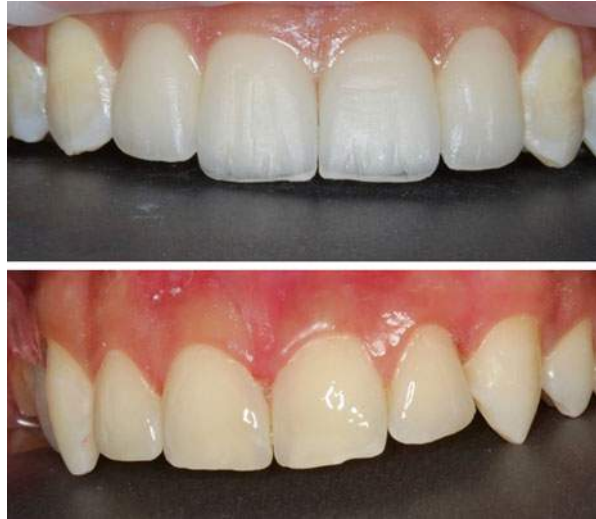Fig. 7.28 Presence of diastema is one of the major causes of the absence of interdental papilla formation



and teeth can also be corrected and repositioned to achieve proposed soft-tissue and teeth relationships by orthodontic treatment [10, 12, 22]. Orthodontic treatment can successfully alter the soft-tissue level by intrusion or extrusion therapies [22], and also successfully reposition the teeth and crestal bone [10, 12], with non-surgical treatment benefiting patients in whom possible exposure of root dentin is eliminated [22]. In the presence of diastema, blunt ended papilla formation can be generally seen between teeth instead of a pointed triangle form; hence, it has been reported that diastema is one of the major causes of the absence of interdental papilla formation (Fig. 7.28) [4, 22]. Therefore, it is of paramount importance in diastema cases to create a balanced and esthetically natural pleasing appearance between soft (gingiva) and hard tissues (teeth) [22]. In diastema cases, closure of spaces between teeth must be accomplished without leaving excessively wide spaces called black triangles, which lead to an unesthetic appearance [22, 24]. To avoid the creation of black triangles, the clinician should design correct contact points and locations of the teeth for the restorative treatment (Fig. 7.29) [22]. This can also be corrected orthodontically without a restorative treatment procedure. Determination of the correct location for the contact point and measurement of the distance between crestal bone and gingival margin can be helpful [22, 24]. It has been previously reported that if the distance from the most apical contact point of the restoration to the crest

Fig. 7.29 To avoid creation of black triangles in the case of diastema, the clinician should design correct contact points and locations of the teeth for restorative treatment procedures



of the bone is approximately 5 mm, the papilla will fill the embrasure nearly 100 % of the time [4, 22, 25]. If the distance is 6 mm, the papilla will fill the gingival embrasure about 55 % of the time (see Chapter 9) [22, 25].

References

1. Davis NC. Smile design. *Dent Clin N Am.* 2007;51(2):299–318.
2. Wasche M, Hepps R, Geissberger M. Guiding principles of esthetic dentistry. In: *Esthetic dentistry in clinical practice*. 1st ed. Ames: Wiley-Blackwell; 2010. p. 9–17.
3. McLaren EA, Culp L. Smile analysis. *J Cosmet Dent.* 2013;29(1):94–108.
4. Bhuvaneshwaran M. Principles of smile design. *J Conserv Dent.* 2010;13(4):225–32.
5. Gurel G. *The science and art of porcelain laminate veneers*. Ergolding, Germany: Carol Stream: Quintessence Publishing Co. Ltd; 2003. p. 59–109.
6. Panossian AJ, Block MS. Evaluation of the smile: facial and dental considerations. *J Oral Maxillofac Surg.* 2010;68(3):547–54.
7. Rifkin R. Facial analysis: a comprehensive approach to treatment planning in aesthetic dentistry. *Pract Periodontics Aesthet Dent.* 2000;12(9):865–71.
8. Mamandras AH. Linear changes of the maxillary and mandibular lips. *Am J Orthod Dentofacial Orthop.* 1988;94(5):405–10.
9. Kirtley GE. The art of a beautiful smile. *J Cosmet Dent.* 2008;24(3):122–31.
10. McLaren EA, Rifkin R. Macroesthetics: facial and dentofacial analysis. *J Calif Dent Assoc.* 2002;30(11):839–46.
11. Morley J, Eubank J. Macroesthetic elements of smile design. *J Am Dent Assoc.* 2001; 132(1):39–45.
12. McLaren EA, Cao PT. Smile analysis and esthetic design: “in the zone”. *Inside Dent.* 2009; 5(7):46–8.
13. Vig RG, Brundo GC. The kinetics of anterior tooth display. *J Prosthet Dent.* 1978;39(5): 502–4.

14. Hoopingarner CR. Simplified smile design: everyday predictability – part I. *J Laser Dent.* 2010;18(1):19–23.
15. Sarver DM. The importance of incisor positioning in the esthetic smile: the smile arc. *Am J Orthod Dentofacial Orthop.* 2001;120(2):98–111.
16. Calamia JR, Levine JB, Lipp M, Cisneros G, Wolff MS. Smile design and treatment planning with the help of a comprehensive esthetic evaluation form. *Dent Clin N Am.* 2011;55(2):187–209.
17. Heinlein WD. Anterior teeth: esthetics and function. *J Prosthet Dent.* 1980;44(4):389–93.
18. Naini FB, Gill DS. Facial aesthetics: 2. Clinical assessment. *Dent Update.* 2008;35(3):159–70.
19. Kokich Jr VO, Kiyak HA, Shapiro PA. Comparing the perception of dentists and lay people to altered dental esthetics. *J Esthet Dent.* 1999;11(6):311–24.
20. Moore T, Southard KA, Casco JS, Qian F, Southard TE. Buccal corridors and smile esthetics. *Am J Orthod Dentofacial Orthop.* 2005;127(2):208–13.
21. Ritter DE, Gandini LG, Pinto Ados S, Locks A. Esthetic influence of negative space in the buccal corridor during smiling. *Angle Orthod.* 2006;76(2):198–203.
22. Oquendo A, Brea L, David S. Diastema: correction of excessive spaces in the esthetic zone. *Dent Clin N Am.* 2011;55(2):265–81.
23. Chu SJ, Tan JH, Stappert CF, Tarnow DP. Gingival zenith positions and levels of the maxillary anterior dentition. *J Esthet Restor Dent.* 2009;21(2):113–20.
24. De Araujo EM, Fortkamp Jr S, Baratieri LN. Closure of diastema and gingival recontouring using direct adhesive restorations: a case report. *J Esthet Restor Dent.* 2009;21(4):229–40.
25. Tarnow D, Cho SC. The interdental papillae. In: Tarnow D, Chu S, Kim J, editors. *Aesthetic restorative dentistry principles and practice.* Mahwah: Montage Media; 2008. p. 367–81.

Ugur Erdemir, Taner Yucel, Esra Yildiz,
Derya Germec Cakan, and Korkmaz Sayinsu

Abstract

Dental composition is an important factor for an esthetically pleasant smile as well as to achieve harmony with the patient gingiva, lips, and face in diastema cases. Teeth size, shape, and proportions greatly affect the esthetic concept and smile. Due to altered tooth size, proportions, and sometimes morphology, median or polydiastemas may cause anterior esthetic concerns for the patients, and the creation of naturally pleasant and stable restoration generally requires a multidisciplinary treatment approach in these kinds of tooth size discrepancies. Therefore, the clinician needs to evaluate the tooth size, form, and intra and/or intertooth proportions as well as occlusion in addition to the previous clinical examinations to achieve a natural and an esthetic final outcome.

Achieving esthetically pleasant restorations in harmony with the patient face, lips, gingiva, and occlusion is important for a natural smile and appearance. The dental composition is a determinant factor for smile design and an esthetic concept especially in diastema cases as they relate more specifically to the size, form, proportions, and position of the teeth on the arch. As in many esthetic restorative reconstruction procedures, creating ideal tooth shape, size and proportion harmonizing with the facial characteristics is without a doubt an important goal in diastema correction.

U. Erdemir, PhD, DDS (✉) • T. Yucel, PhD, DDS • E. Yildiz, PhD, DDS
Operative Dentistry, University of Istanbul Faculty of Dentistry, Istanbul, Turkey
e-mail: uerdemir@hotmail.com

D. Germec Cakan, DDS, PhD
Orthodontics, Yeditepe University, Dental Faculty, Istanbul, Turkey

K. Sayinsu, DDS, PhD
Orthodontics, Private Practice, Istanbul, Turkey

Fig. 8.1 Maxillary central incisors are the key element as they are the dominant teeth in the smile

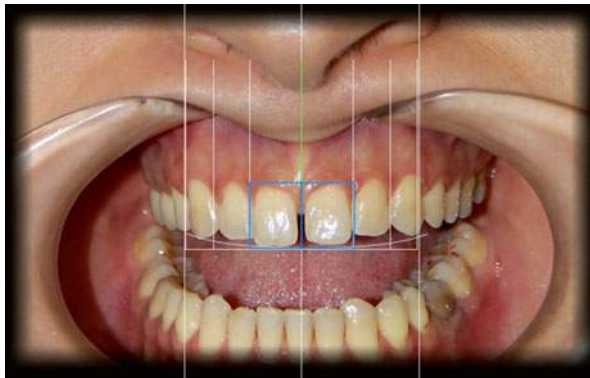
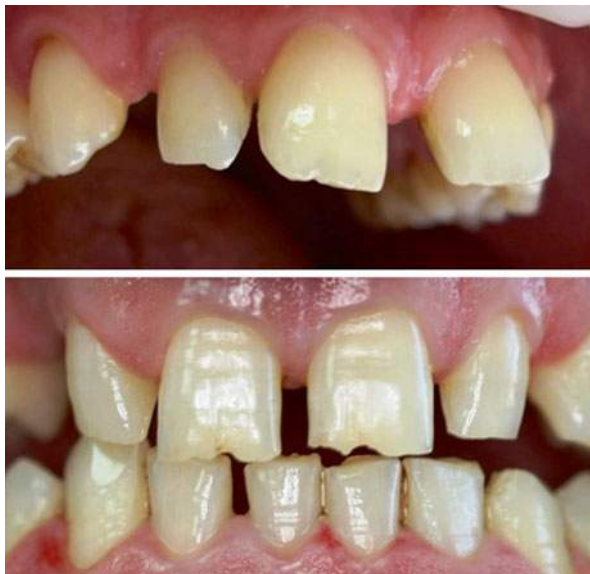

Fig. 8.2 Median or polydiastemas may cause anterior esthetic concerns for the patients due to altered tooth size, proportions, and sometimes morphology



Therefore, size, shape, and proportion of the maxillary anterior teeth are the most important factors for the creation of a functional, esthetic and pleasing final restoration [1]. In creating an esthetically natural and pleasant smile, maxillary central teeth are the key element as they are the dominant teeth in the smile, and they must present proper tooth size, form, and shape not only for esthetics but also for the function and phonetics (Fig. 8.1) [1, 2]. Due to altered tooth size, proportions, and sometimes morphology, median or polydiastemas (Fig. 8.2) may cause anterior esthetic concerns for the patients [3]. Treatment of these kinds of tooth size discrepancies is often complicated for the clinicians, and hence creation of a naturally pleasant and stable final restoration generally requires a multidisciplinary treatment approach by the orthodontist, periodontologist, and restorative dentist [3]. During the creation of the

most pleasing restoration, the clinician should evaluate the tooth size, form, and intra and/or intertooth proportions as well as occlusion in addition to the previous clinical examinations.

8.1 Tooth Size

Before initiation of any esthetic restorative treatment procedure, the clinician should determine interdental spacing and tooth size by using an appropriate instrument such as a caliper (Fig. 8.3). Maxillary central incisors are the most dominant teeth in an esthetic restorative treatment procedure, therefore, the clinician can primarily begin with the measurement of these teeth to correct median and/or polydiastemas. In addition, a detailed analysis can be performed by the orthodontist using “Bolton analysis,” which compares the overall tooth measurements in one arch relative to the other (please see below) [3].

Creating an ideal single tooth proportion is essential in diastema correction since imbalance in the restored tooth proportion may occur after diastema closure [4].

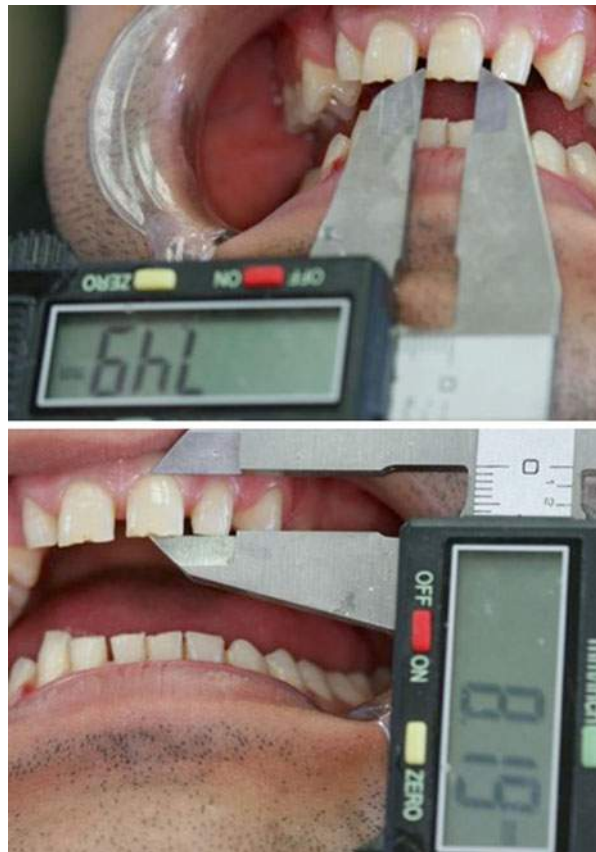

Fig. 8.3 Determination of maxillary central incisor size using a digital caliper

Fig. 8.4 To create an esthetically pleasing and natural final outcome, width to length tooth ratio for maxillary central incisor should be 80 % within the acceptable esthetic range of 75–85 %

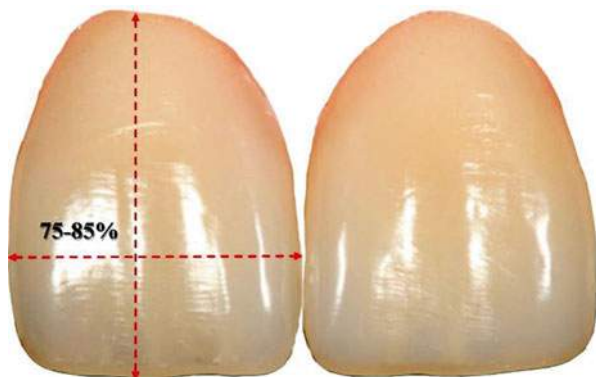
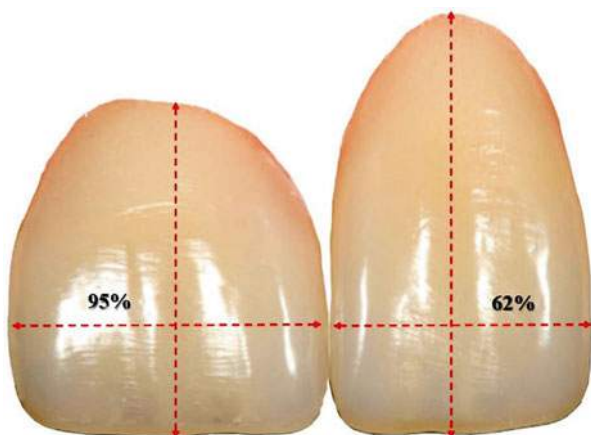


Fig. 8.5 Changes in width-length ratio can be seen frequently in diastema closure, and increasing or decreasing these proportions would produce square or rectangular form for a single tooth and would create an unaesthetic appearance



Single tooth proportion is defined by the ratio of width to length of a tooth. A pleasing and natural width to length tooth ratio is therefore important for creating an esthetically pleasing final outcome in diastema closure. It has been reported previously that a pleasing tooth proportion for maxillary central incisor should be 80 % within the acceptable esthetic range of 75–85 % (Fig. 8.4) [2, 4]. Increasing or decreasing these proportions would produce square or rectangular form (Fig. 8.5) for a single tooth and would create an unaesthetic appearance. Changes in width-length ratio can be seen frequently in diastema closure especially in direct technique and affect the proportion, size, and shape of a single tooth appearance and consequently affect the overall esthetic outcome of the final restoration. There have been different reports regarding the length of the maxillary central incisors in the literature. In previously published literature, it has been reported that the length of the maxillary central incisors measured from the gingival margin to the incisal edge should be approximately 10.5–11.0 mm for an esthetic appearance (Fig. 8.6) [5–7]. In another report, it has been stated that the average length of the maxillary central should be

Fig. 8.6 Length of the maxillary central incisors measured from the gingival margin to the incisal edge should be approximately 10.5 to 11.0 mm, and ideal mesiodistal width should be between 8 and 8.5 mm for an esthetic appearance

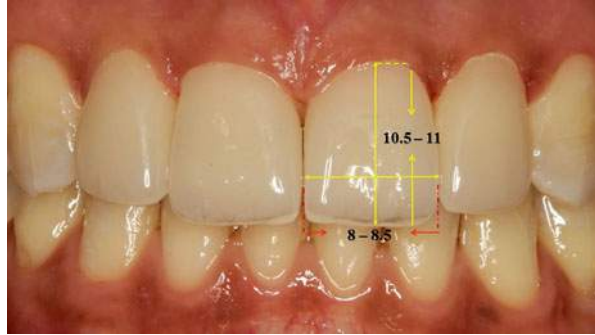
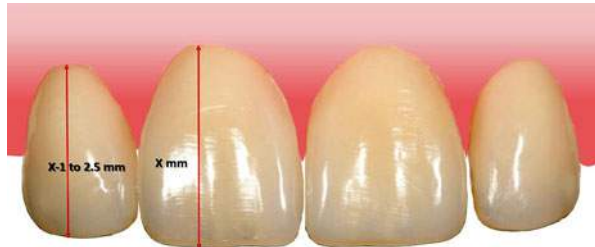
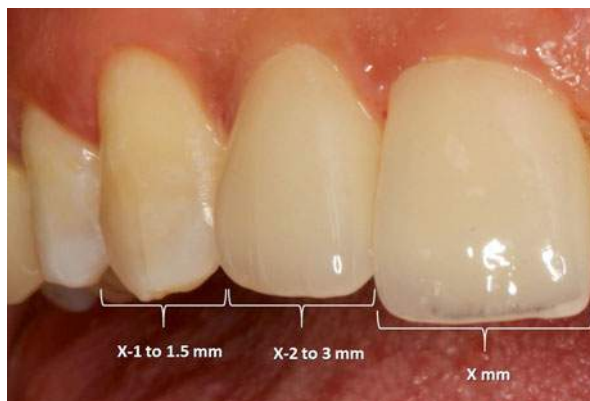


Fig. 8.7 For a natural and perfect appearance, length of the lateral incisors should be 1 mm to 2.5 mm shorter than that of maxillary central incisors



10 mm, with the maximum and minimum lengths being 12 and 8 mm, respectively [8]. Another article reported that the average length of the unworn maxillary central incisors should be 12 mm ranging from 11 to 13 mm [7]. Magne et al. [9] have also reported that the average length of maxillary unworn central incisors measured from the cemento-enamel junction to the incisal edge is slightly over 11 mm. For an esthetically pleasant smile, the length of the maxillary central incisors should be between 10.5 and 12 mm, with the average being 11 mm, a good starting point in the esthetic zone according to these authors [9]. In addition, for a natural and perfect appearance, ideal length of the lateral incisors should be 1 mm to 2.5 mm shorter than that of maxillary central incisors (Fig. 8.7) [10, 11]. Maxillary canines should also be slightly shorter than the central incisors ranging between 0.5 mm and 1 mm [10, 11]. The width of the ideal maxillary central incisors should be approximately 8–8.5 mm (Fig. 8.6) for accepted dimensions to create naturally esthetic form [5, 6]. The clinician should always bear in mind that maxillary central incisors are approximately 2–3 mm wider than the lateral incisors and 1–1.5 mm wider than the canines in the esthetic zone (Fig. 8.8) [12]. In addition, maxillary canines should be 1–1.5 mm wider than the laterals, and maxillary central incisors and canines should be positioned 1–1.5 mm incisally than the lateral incisors [12]. Maxillary lateral incisors and canines are also essential clinical evaluation parameters in smile analysis as they play an important role in a pleasing smile. In general, maxillary lateral incisors seem asymmetric in the arch and influence the gender characterization [2, 13]. Maxillary canines are also critical teeth since they are located at the corner of the dental arch. Only the mesial

Fig. 8.8 In the esthetic zone, maxillary central incisor should be approximately 2–3 mm wider than the lateral incisors and 1–1.5 mm wider than the canines



half of these teeth are visible from the frontal aspect when the patient smiles; they can support the upper lips, and position, size, and the shape of these teeth greatly affect the buccal corridor characteristics [2, 13]. In addition, canines and central incisors present gender-specific anatomical differences where femininity is characterized by roundness and smoothness, leading to an oval tooth form with round edges. On the other hand, masculinity is determined by a square shape [2, 13]. The length of the maxillary central incisor shows individual variability depending on the incisal display [8], and patients can have a pleasant smile despite the disproportionate teeth [13]. It has been previously stated that 2 mm tooth size discrepancies in the esthetic zone should be considered as a clinically significant threshold [3, 14]. If the tooth size discrepancy is less than 2 mm, the diastema can be successfully treated with orthodontic treatment [3]. If the tooth size discrepancy exceeds 2 mm, which is confirmed by the tooth size analysis, then a multidisciplinary treatment approach should be considered to enhance the size of the anterior teeth and close the space for an esthetically pleasant outcome [3]. If necessary, the clinician can prepare a diagnostic wax setup (please see Fig. 4.3a, b) for subsequent multidisciplinary evaluation and reconsider the treatment plan [3].

8.2 Dental Model Analysis

According to Andrews, “six keys of the occlusion” are the prerequisites of a normal occlusal relationship [15]. These parameters include molar interarch relationship, mesiodistal crown angulation, labiolingual crown inclination, rotation, tight proximal contacts, and occlusal plane. The inability to achieve proximal contact between all teeth in an arch while maintaining ideal molar intercuspation may indicate a tooth size-arch size discrepancy or a size discrepancy between the maxillary and mandibular teeth. There are several methods of determining the cause of this discrepancy. In this chapter, the most commonly used space and tooth size analysis will be explained.

For this purpose, digital models and a software program are most accurate, though standard dental models and a caliper are sufficient.

8.2.1 Space Analysis

Space analysis (Hays Nance analysis) reveals the relationship between tooth size and dental arch length for proper alignment of the teeth in the absence of irregularities or diastemas. This is a basic mathematical equation comparing the required and available space [16]. In each arch, the mesiodistal widths of each tooth mesial to the first permanent molar are summed to determine the “space required” (Fig. 8.9a). To determine the “space available”, the actual arch length is measured using a soft wire shaped to fit the individual arch form and placed on the occlusal surfaces of the teeth, extending from mesial contact point of the right first permanent molar to the mesial contact point of the left first permanent molar (Fig. 8.9b). The difference between the space available and the space required describes the space relationship. A negative value indicates space deficiency leading to

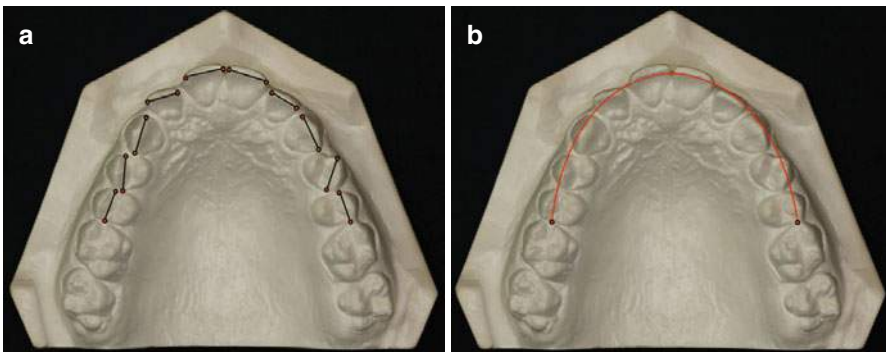
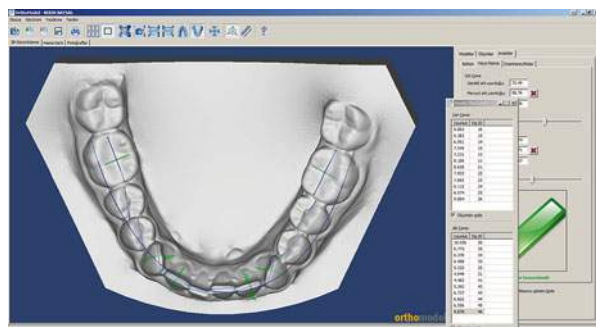

Fig. 8.9 (a) Measurement of mesiodistal tooth widths and (b) measurement of actual arch length. The difference of space available and space required is 4 mm, indicating the amount of diastema

Fig. 8.10 Digital Hays Nance analysis with software program



crowding, whereas a positive value indicates excess space, which manifests as diastemata. As an alternative to the manual method, software programs can be used (Fig. 8.10).

In diastema cases, Hays Nance analysis calculates the amount of space which should be managed by restorations, orthodontics, or combination of both.

8.2.2 Tooth Size Analysis (Bolton Analysis)

The widths of the maxillary and mandibular teeth must be proportional in order to obtain proper dental interdigitation and arch coordination. However, disproportionate tooth size is quite common [17]. There is a direct relationship between the magnitude of tooth size discrepancies and the presence of occlusal irregularities [18]. Furthermore, a significant crown size difference between upper and lower teeth may prevent achieving a satisfactory occlusion. Excess tooth material in the mandibular arch, for example, may lead to maxillary spacing or mandibular crowding with a Class I molar relationship, or reduced overjet and a Class III molar relationship in properly aligned dental arches without spacing.

Size and shape anomalies of the teeth are most prevalent in upper lateral incisors and upper and lower second premolars [19]. Diminutive maxillary lateral incisors can be easily detected by visually comparing their mesiodistal width with that of the mandibular lateral incisors. In general, a smaller width of the maxillary lateral incisors indicates a discrepancy. When the discrepancy involves several teeth, this process becomes complicated. For a group of teeth (either all anterior teeth or all permanent teeth except second and third molars), Bolton analysis determines the ratio of the mesiodistal widths of the maxillary teeth versus mandibular teeth [20]. First, mesiodistal widths of the permanent teeth are measured, then summed for calculation of the overall ratio using the following formula: overall ratio=(sum of mesiodistal widths of the 12 mandibular teeth)/(sum of mesiodistal widths of the 12 maxillary teeth) × 100 (Fig. 8.11). If this ratio is greater than 91.3 %, there is excess of mandibular tooth material. If the ratio is smaller than 91.3 %, the excess is in maxilla. The anterior ratio is also calculated using mesiodistal widths of the maxillary and mandibular incisors

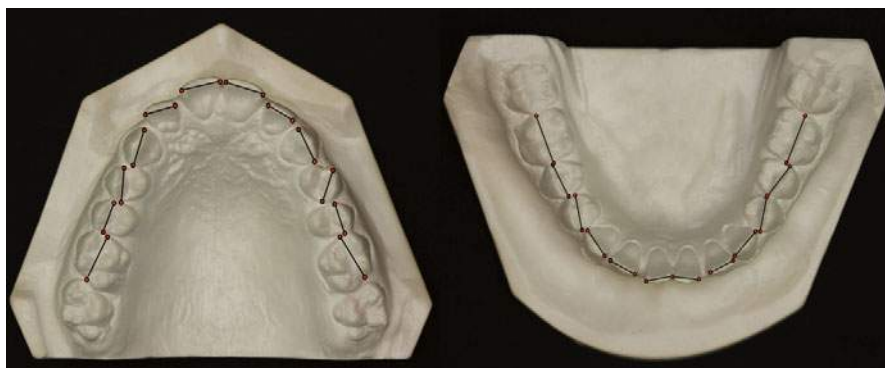


Fig. 8.11 Measurement of the mesiodistal widths of the related teeth for Bolton analysis

Table 8.1 Maxillary and mandibular tooth size relationships for 12 teeth

Overall ratio					
Max 12	Mand 12	Max 12	Mand 12	Max 12	Mand 12
85	77.6	94	85.8	103	94.0
86	78.5	95	86.7	104	95.0
87	79.4	96	87.6	105	95.9
88	80.3	97	88.6	106	96.8
89	81.3	98	89.5	107	97.8
90	82.1	99	90.4	108	98.6
91	83.1	100	91.3	109	99.5
92	84.0	101	92.2	110	100.4
93	84.9	102	93.1		

$$\text{Overall ratio} : \frac{\text{Sum mand 12 (mm)}}{\text{Sum max 12 (mm)}} \times 100 = \%$$

$$\text{Overall ratio} > 91.3 \% : \frac{\text{mm}}{\text{Actual mand 12}} - \frac{\text{mm}}{\text{Correct mand 12}} = \frac{\text{mm}}{\text{Excess mand 12}}$$

$$\text{Overall ratio} < 91.3 \% : \frac{\text{mm}}{\text{Actual max 12}} - \frac{\text{mm}}{\text{Correct max 12}} = \frac{\text{mm}}{\text{Excess max 12}}$$

Table 8.2 Maxillary and mandibular tooth size relationships for six anterior teeth

Anterior ratio					
Max 6	Mand 6	Max 6	Mand 6	Max 6	Mand 6
40.0	30.9	45.5	35.1	50.5	39.0
40.5	31.3	46.0	35.5	51.0	39.4
41.0	31.7	46.5	35.9	51.5	39.8
41.5	32.0	47.0	36.3	52.0	40.1
42.0	32.4	47.5	36.7	52.5	40.5
42.5	32.8	48.0	37.1	53.0	40.9
43.0	33.2	48.5	37.4	53.5	41.3
43.5	33.6	49.0	37.8	54.0	41.7
44.0	34.0	49.5	38.2	54.5	42.1
44.5	34.4	50.0	38.6	55.0	42.5
45.0	34.7				

$$\text{Anterior ratio} : \frac{\text{Sum mand 6 (mm)}}{\text{Sum max 6 (mm)}} \times 100 = \%$$

$$\text{Overall ratio} > 77.2 \% : \frac{\text{mm}}{\text{Actual mand 6}} - \frac{\text{mm}}{\text{Correct mand 6}} = \frac{\text{mm}}{\text{Excess mand 6}}$$

$$\text{Overall ratio} < 77.2 \% : \frac{\text{mm}}{\text{Actual max 6}} - \frac{\text{mm}}{\text{Correct max 6}} = \frac{\text{mm}}{\text{Excess max 6}}$$

and canines by the same formula to reveal any discrepancy in the anterior region. If the ratio is greater than 77.2 %, the mandibular anterior teeth are relatively wide compared to the maxillary anterior teeth. If the ratio is smaller than 77.2 %, the maxillary anterior teeth are relatively wide. After calculating the Bolton ratio, a standard table is

used to determine the ideal size of this group of teeth based on the assumption that the smaller tooth widths are correct (Tables 8.1 and 8.2). The amount of excess tooth size is then calculated as the difference between actual size and correct size. When using the Bolton analysis to define intermaxillary tooth size discrepancies, the clinician should consider that Bolton's original data is not applicable to every population [19, 21]. Therefore, population specific norms should be used if available.

In diastema cases, the Bolton analysis helps to determine the dimensions of restorations for a group of teeth. When the result of this analysis is combined with width-length ratios and interarch tooth size proportions, the tooth or teeth requiring buildup can easily be detected. Alternatively, appropriate tooth size can be determined using the analysis of permanent mesiodistal crown width as described by Sanin and Savara [18].

8.3 Tooth Form and Design

Within the context of tooth form and design, the clinician should consider many aspects that can strongly affect the natural and pleasing smile. The axial inclination, contact area or connector space, incisal embrasures, characterizations, and color of the teeth are the factors that affect esthetic appearance [1]. Normally, when viewed from the frontal aspect, the long axis of the anterior teeth should follow a slightly progressive mesial inclination when moved away from the midline (Fig. 8.12) and create a harmonious smile by framing of the lower lip [1, 2, 8, 13]. Maxillary central incisors have the least visible inclination in which their long axis are located slightly distal from the midline [1, 2, 8]. Inclination is exhibited slightly more in distal position for maxillary lateral incisors and slightly more so for canines (Fig. 8.12) [1, 2]. In the case of spaced dentition, tooth inclinations can appear normal or tilted due to tooth movement into the spacing. Sometimes it is possible to see the long axis of the tooth moved from the midline and distally or labially tilted [8] in diastema cases (Fig. 8.13). The most pleasing appearance of the maxillary central incisors is

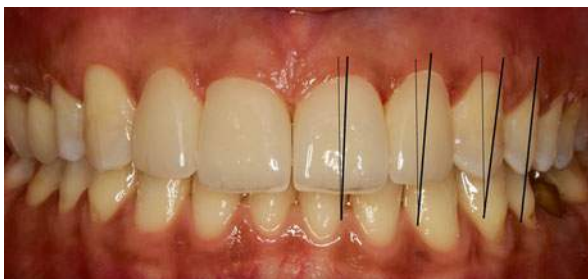

Fig. 8.12 Axial inclination of teeth should follow a slightly progressive increase in the medial tipping from the frontal view. For the maxillary central incisors, inclination is least visible whereas it is more pronounced for the canines

Fig. 8.13 Distal tipping of the maxillary central incisors in a diastema case

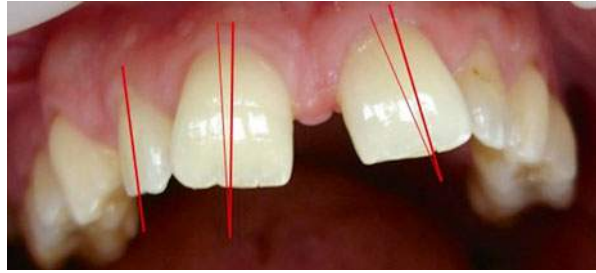
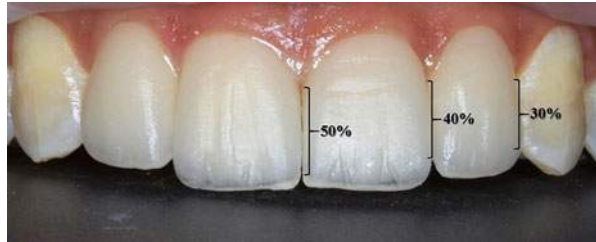

Fig. 8.14 Ideal connector area between the maxillary central incisor, the lateral incisor, and the canine should follow the 50:40:30 rule, respectively



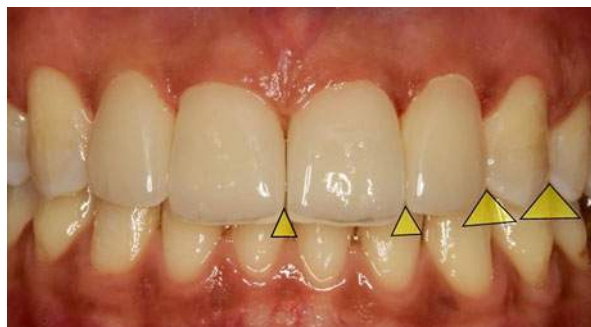achieved when these teeth are positioned vertically or slightly mesially inclined [13]. The evaluation of the axial inclination of the anterior teeth can be easily done on the frontal intraoral photographs [2]. To achieve an esthetic outcome, it is essential to know the correct tooth inclinations and create slightly medially tipped maxillary anterior teeth in harmony with the gingiva, lips, and face of the patient. With regard to the tooth form in the esthetic smile zone, the maxillary lateral incisors are the most affected teeth by the tooth size discrepancy as they can present reduced gingivo-incisal length and mesiodistal width called “peg-shaped” lateral incisors [3]. In this case, maxillary lateral incisor crowns are conical, which generally appears tapered from the gingival margin towards the incisal edge, creating a spaced dentition in the arch (please see Fig. 2.6a) [3]. Form and anatomy of the maxillary central incisors also play a significant role in the esthetic appearance and natural smile. In some diastema cases, the form can be flat, convex or tapered [3, 8] which may affect the individual’s smile characteristics. In creating a pronounced position of the maxillary central incisors in the arch, the clinician should consider all these factors for proper diastema correction.

Another clinically and esthetically important consideration in a natural smile is the interdental contact area or connector space between two adjacent teeth. Interdental contact area or connector space is defined as the broad space between two adjacent teeth that touch [1, 2, 8, 13]. These contact areas are not present in diastema cases, which creates an unpleasant appearance. In an esthetically pleasant and natural smile, these contact areas generally follow a decreasing characteristic from anterior to posterior, with the largest contact area between the maxillary central incisors [1, 2, 13]. Studies have reported that it follows the 50:40:30 rule in reference to the maxillary central incisors’ length [1, 2, 13, 22, 23].

In accordance with the rule, 50% of the length of the maxillary central incisors is defined as the ideal connector space [1, 13, 22]. The ideal connector space between the maxillary lateral incisor and central incisor would be 40 % of the length of the maxillary central incisor and 30 % of the length between the lateral incisor and canine (Fig. 8.14) [1, 13, 22]. Creation of the ideal connector spaces according to this rules is important in diastema closure. If the space connector is not created correctly and ideally between two adjacent teeth, in particular between maxillary central incisors, the formation of a black triangle is inevitable. In some diastema cases where there is insufficient bone support and blunt-edged papilla formation between maxillary central incisors, interdental contact space can be lengthened apically with restorative treatment to close the space and generate the triangular-shaped papilla formation without a black triangle [13]. Creating an interdental contact area apically provides an illusion of wider appearance for long teeth [2].

Another critical and important consideration for smile esthetics is the creation of incisal embrasures as they are normally absent in diastema cases. For ideal maxillary anterior teeth alignment, incisal embrasures form an open, darker and triangular-shaped space between the incisal edges of the two teeth's proximal surfaces [7, 13]. Incisal embrasures are created by the incisal edge curvature and spacing between the anterior teeth and display a natural progressive increase in size from the maxillary dental midline to the canine and so on (Fig. 8.15) [2, 8, 13, 22]. Contact areas of the maxillary central incisors are located at the 1/3 incisal part of the crowns, and hence, incisal embrasure space between these two teeth is triangular shaped. When moved posteriorly, the contact point of the teeth becomes approximately at the middle third, creating a larger incisal embrasure [2, 8, 13]. Therefore, normally the size and volume of the incisal embrasures between teeth progressively increase from anterior to posterior [13, 22]. In other words, incisal embrasure between the maxillary central and lateral incisor should be relatively larger than the incisal embrasures between maxillary central incisors for an esthetic and youthful appearance [1, 13, 22]. The created triangular-shaped incisal embrasure form cannot always be symmetrical on both sides of the arch, and can vary in shape [13]. The incisal embrasures can also vary in size depending on the gender. For females, disto-incisal corner

Fig. 8.15 In ideally aligned maxillary anterior teeth, incisal embrasure size should display a natural progressive increase from dental midline to the canine and so on



of the lateral incisor tends to be more rounded than for males, and hence, incisal embrasure between the maxillary lateral incisor and canine is wider in women than men [13]. Incisal embrasure form can also create an illusion for a natural and pleasing appearance of a patient. If the mesio-incisal and disto-incisal edge of the teeth is rounded to create an incisal embrasure, then the teeth would be perceived longer than their original length [13].

The characteristics of a particular tooth such as color, surface texture, transparency, and incisal characterization may differ depending on the age of the individual. For a younger individual, the teeth appear brighter with low chroma and high value due to greater amount of enamel (Fig. 8.16a) [1, 2, 13]. In contrast, in an aged individual the teeth appear more fulvous with high chroma and low value due to wear or loss of the enamel and appearance of the underlying dentin layer (Fig. 8.16b) [1, 2, 13]. Generally unworn natural-looking teeth appear as polychromatic in color in which the gingival part has more chroma due to a thin enamel layer, the middle part of the tooth has uniform color, and the incisal part exhibits a translucency that can exhibit different characteristics such as blue, amber, opaque, and gray in color [1, 8]. When moved away distally from dental midline, shade and color of the maxillary teeth exhibit a progressive pattern on the arch [22]. In normal conditions the maxillary central incisors are the lightest teeth on the arch, and the lateral incisors have a similar appearance with the slight difference being lower in value than central incisors [13, 22]. Canines are more saturated in chroma with the lower value and hence have a darker appearance in the anterior segment than central and lateral incisors as well as bicuspid [22]. For creation of a natural and esthetic appearance, the clinician should follow the natural teeth shade progression in any of the esthetic restorative treatments (Fig. 8.17), even though the patient requests the bright colored restorations [13]. Not only the shade progression but also incisal part characteristics of the teeth should be corrected depending on the age, gender and personality of a patient to achieve a natural and esthetically pleasant restoration (Fig. 8.18). Surface textures of the anterior tooth also have a significant effect on an esthetic and natural smile. In this context, for a younger patient anterior teeth exhibit more surface texture than in the elderly and result in more reflective and brighter appearance [1, 13]. Surface texture of a tooth as well as

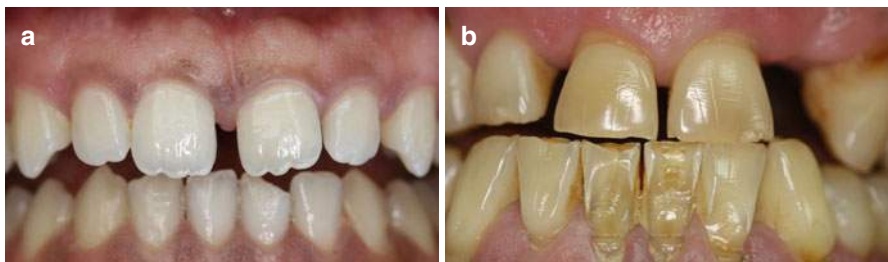


Fig. 8.16 The characteristics of a tooth such as color, surface texture, transparency, and incisal characterization may differ depending on the age of the individual. (a) Surface texture and characteristics for a young individual. (b) Surface texture and characteristics for an older individual

Fig. 8.17 Tooth surface characteristics of a young patient

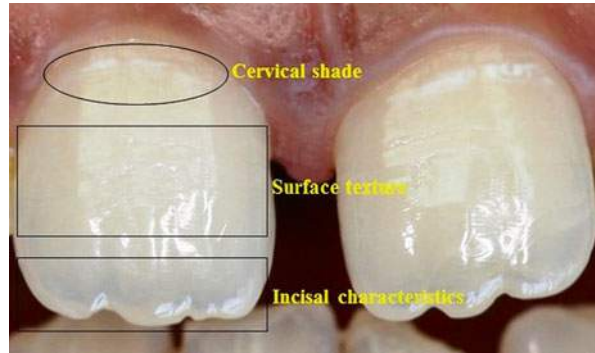
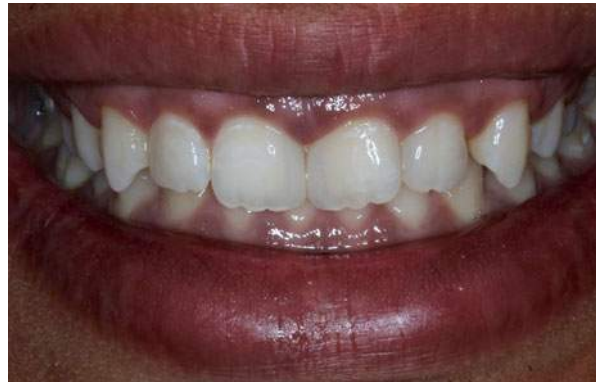

Fig. 8.18 Shade progression and incisal part characteristics of the teeth should be created depending on the age, gender, and personality of a patient for a natural and esthetically pleasant appearance



any anterior esthetic restoration either directly or indirectly affect the size and shape [13]. Younger teeth have a rough surface compared to aged teeth in which a smooth tooth surface texture is the characteristic, and hence reflection and refraction of the light on a rough surface texture creates a brighter and more natural appearance (Fig. 8.17). Therefore, in an esthetic restorative treatment, the clinician should always mimic the adjacent natural teeth to allow light to produce the same natural and brighter tooth appearance and color matching [13].

8.4 Tooth Proportions

Tooth proportions are another important parameter in an esthetic and natural smile when closing diastema. After establishing appropriate soft and hard tissue relationships, clinicians can use various intertooth ratios to create a harmonious and pleasing smile. Maxillary central incisors should be proportionate to the arch and facial morphology [13]. Various guidelines have been recommended for establishing correct intertooth proportions of the anterior teeth [1, 2, 4, 8, 13]. These guidelines are the “golden proportion proposed by Lombardi” [24], “recurring esthetic dental (RED) proportions proposed by Ward” [25], and the “esthetic guide proposed by

Chu” [26]. The golden proportion has been used for years for dental esthetic proportions and esthetic considerations in maxillary anterior segment [13, 27]. The Golden proportion was firstly proposed by Lombardi [24], and subsequently Levin [28] who developed this principle in dentistry for esthetic considerations. According to this proportion, when viewed from the frontal aspect, the width of each maxillary anterior tooth is 62 % of the width of the adjacent tooth. In other words, the maxillary central incisor should be approximately 62 % wider than the lateral incisor, and the lateral incisor should be approximately 62 % wider than the canine when observed from the frontal view (Fig. 8.19), with the ideal mathematical ratio from central to lateral and canine being 1.618:1:0.618 [1, 2, 8, 13, 27, 29]. It must be kept in mind that the golden proportion rule is not the actual width measurement of the maxillary anterior teeth and only perceived when observed from the frontal aspect. In addition, during smile analysis and creation of an esthetically pleasant smile for a patient, the clinician should use the golden proportion as a dental esthetic guideline rather than a definite rule [1, 27]. As the golden proportion does not reflect exact tooth proportions, the clinician can use it as complementary guide in cases requiring esthetic restorations (Fig. 8.20) [8, 10]. The use of these mathematical equations and percentages in an esthetic treatment plan may pose individual problems in the clinical setting depending on the case. If there is a tooth size discrepancy between the right and left lateral incisor, the application of the golden proportion

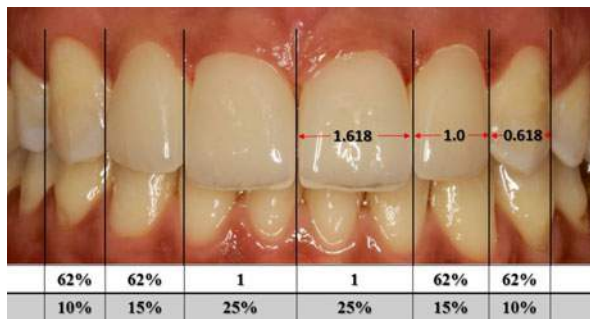


Fig. 8.19 Example of the golden proportion and the golden percentage

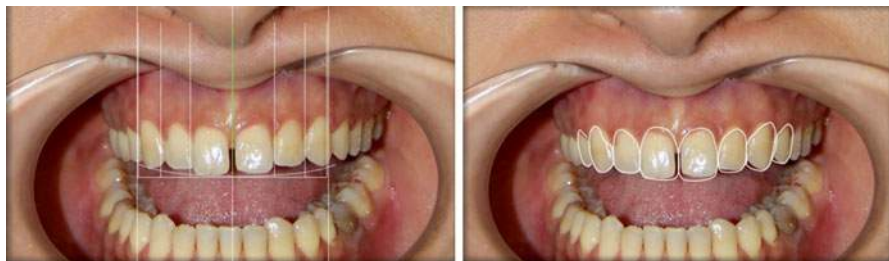

Fig. 8.20 The use of the golden proportion as a guide to create an ideal smile

will create asymmetrical central incisors [29]. In addition, the analysis of beautiful smiles in men and women revealed that the mathematical equation of the golden proportion was not observed in the majority of the cases [13]. Gurel [13] stated that if the golden proportion is applied to dentistry in all esthetic cases, all maxillary anterior teeth would display a uniformly and perfect form for every patient, but in reality every patient does not have the same facial morphology, lips, facial proportion, and dental arch form. Consistently, it has been reported that only 17 % of patients have ideal golden proportions, and strict adherence to this rule for esthetic considerations would create a narrower maxillary arch [4, 26]. A variety of golden proportion analysis instrument have been manufactured by companies to aid the clinician in designing esthetic restorations. The Golden Ruler (Panadent Corp., Colton, California, USA) or Golden Section Divider (Smile Line; Turkuaz Dental, Izmir, Turkey) is one of the directly practical instruments for ideal golden proportion determination on dentition as well as on the patient face (Fig. 8.21). It can also help to determine the diagnostic wax setup and final restoration. The golden proportion waxing guide which has grids according to the golden ratio can be used to determine the golden proportion of maxillary anterior teeth.

The Golden percentage has been suggested to overcome the limitations of the golden proportion as being a more user-friendly analysis tool in a simplified version for clinical application [27]. According to this simplified version of the golden proportion concept which was proposed by Snow [30], each maxillary anterior tooth should occupy a particular percentage on the maxillary anterior segment when viewed from a frontal aspect [27, 30]. With this concept, maxillary central incisors should occupy 25 % of the anterior segment, lateral incisors should occupy 15 %, and canines should occupy 10 %.

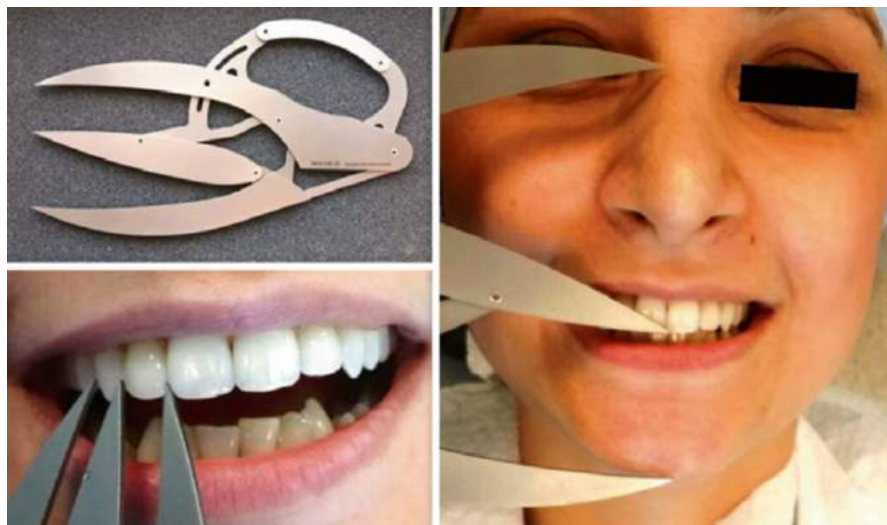

Fig. 8.21 The Golden Section Divider (Smile Line; Turkuaz Dental, Izmir, Turkey) and its use for the ideal golden proportion determination on dentition as well as on the patient face (Courtesy of Dr. Ezel Elmas and Dr. Mert Topcubasi)

and canines should occupy 10 % of this anterior segment (Fig. 8.19) [27, 30]. It has been stated that the use of the golden percentage concept has advantages such as symmetry for each tooth width, dominance, proportion, and more accurate smile design in esthetic treatment of the anterior segment [27].

When percentage proportions are not necessary, recurring esthetic dental (RED) proportions are suggested to overcome the limitations and inadequate applications of the golden proportion in all esthetic cases due to the different dental arch forms [13, 25, 26]. According to this concept, successive width proportions of the teeth when viewed from the frontal aspect should remain constant when moved distally from midline (Fig. 8.22) [2, 13, 25]. It has been stated that the use of this concept in esthetic treatment procedure gives flexibility to the clinician for using their own proportion choice in creating esthetically pleasant restorations rather than using the 62 % proportion [2, 4, 13]. RED proportion has been also found to be a pleasing concept for the clinician and the patient because it gives the clinician the opportunity to create a patient specific ratio for a perfect smile [4, 13, 31].

According to the tooth width in the maxillary anterior esthetic zone, Chu [26] has also described another concept for creating a pleasant and perfect smile. With regard to this concept, the width of the maxillary lateral incisor and canine should be approximately 2 mm and 1 mm less than that of the maxillary central incisor, respectively (Fig. 8.23). It seems that this concept is easy to use for clinicians during restorative treatment procedures.

In order to have natural, pleasing, and proportionate restorations that are in harmony with the patient's teeth, gingival structure, lips, and facial characteristics are important in esthetic dentistry. To achieve ideal esthetic restorations in the esthetic zone, the clinician should carefully record and understand their patients own perceptions as well as expectations.

As previously described, maxillary central incisors are dominant teeth in esthetic smile design, and the most pleasing width-length ratio for these teeth should be 80 % with the range of 75–85 %, and (Fig. 8.4) the ratio for the lateral incisors should be approximately 70 % with the range of 73–76 % [9, 28, 29, 32, 33]. When

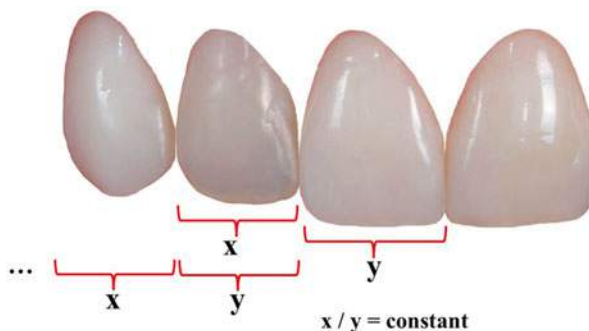


Fig. 8.22 Diagrammatic representation of the recurring esthetic dental (RED) proportions. According to this concept, successive width proportions of the teeth when viewed from the frontal aspect should remain constant when moved distally from midline (Modified from Gürel [13])

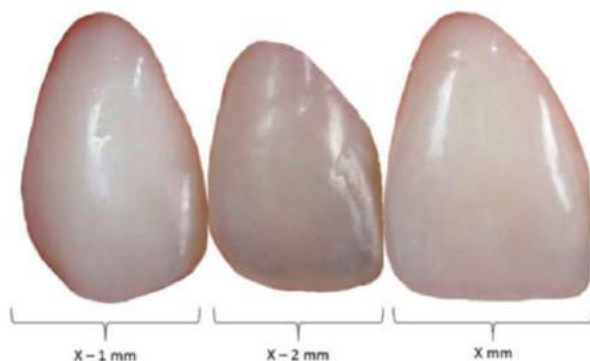

Fig. 8.23 According to the Chu [26] concept, width of the maxillary lateral incisor and canine should be approximately 2 mm and 1 mm less than that of the maxillary central incisor, respectively, for a pleasing appearance

the spacing is caused by the undersized lateral incisors, the clinician can use the central incisors as a guide and restore the lateral incisors proportionally with the central incisors. If a multispaced dentition caused by tooth size discrepancy of the incisors including the centrals is detected the clinician should carefully plan a restorative treatment procedure with the involvement of the orthodontist and the periodontist in the treatment plan to achieve a pleasant final outcome. In this situation diagnostic study plaster models, mock-up, and careful evaluation by multidisciplinary team would bring successful treatment.

8.5 Occlusion

Although occlusion is described in previous chapters, it is an additionally important evaluation criterion in the case of spaced dentition. Generally the occlusion is often ideal in diastema cases, and most of the reported reasons for spaced dentition is due to tooth size and arch size discrepancies in which teeth are too small related to the arch size [34]. Besides the esthetic smile designing procedure, envelope of function of the prepared restorations in the esthetic zone is essential. All the restorations, either direct or indirect, must be prepared in harmony with the patient occlusion and envelope of function during the restorative treatment procedure [4]. Overjet and overbite and maxillary spacing should be carefully evaluated for a successful final outcome. If the patient has maxillary spacing and representing Class II malocclusion with a significant overjet, retraction of the anterior teeth will allow the reduction of overjet and closure of the diastema with orthodontic treatment [29]. If the patient has no excessive overjet as in the case of Class I malocclusion and exhibiting spaced dentition, then closing the diastema only with the retraction of the maxillary anterior teeth will adversely affect the functional occlusion of the patient due to possible overretraction of the maxillary anterior teeth [29]. Solely orthodontic

treatment of such cases without restorative procedures may cause several problems in the future such as relapse of the case, increased incisal contact, and hence wear of the anterior teeth [29]. Therefore, it is of paramount importance for the clinician to determine the multidisciplinary effect of diastema correction on the patient occlusion as well as the stomatognathic system irrespective of the applied treatment [4].

References

1. Kirtley GE. The art of a beautiful smile. *J Cosmet Dent.* 2008;24(3):122–31.
2. Bhuvanewaran M. Principles of smile design. *J Conserv Dent.* 2010;13(4):225–32.
3. Waldman AB. Smile design for the adolescent patient – interdisciplinary management of anterior tooth size discrepancies. *J Calif Dent Assoc.* 2008;36(5):365–72.
4. Oquendo A, Brea L, David S. Diastema: correction of excessive spaces in the esthetic zone. *Dent Clin N Am.* 2011;55(2):265–81.
5. Ash MM, Nelson SJ. Wheeler’s dental anatomy, physiology, and occlusion. 9th ed. St. Louis: Saunders Elsevier; 2010. p. 99–111.
6. Panossian AJ, Block MS. Evaluation of the smile: facial and dental considerations. *J Oral Maxillofac Surg.* 2010;68(3):547–54.
7. Kokich Jr VO, Kiyak HA, Shapiro PA. Comparing the perception of dentists and lay people to altered dental esthetics. *J Esthet Dent.* 1999;11(6):311–24.
8. Davis NC. Smile design. *Dent Clin N Am.* 2007;51(2):299–318.
9. Magne P, Gallucci GO, Belsler UC. Anatomic crown width/length ratios of unworn and worn maxillary teeth in white subjects. *J Prosthet Dent.* 2003;89(5):453–61.
10. McLaren EA, Culp L. Smile analysis. *J Cosmet Dent.* 2013;29(1):94–108.
11. McLaren EA, Cao PT. Smile analysis and esthetic design: “in the zone”. *Inside Dent.* 2009;5(7):46–8.
12. Mamandras AH. Linear changes of the maxillary and mandibular lips. *Am J Orthod Dentofacial Orthop.* 1988;94(5):405–10.
13. Gurel G. The science and art of porcelain laminate veneers. Ergolding, Germany: Quintessence Publishing Co. Ltd.; 2003. p. 59–109.
14. Othman S, Harradine N. Tooth size discrepancies in an orthodontic population. *Angle Orthod.* 2007;77(4):668–74.
15. Andrews LF. The six keys to normal occlusion. *Am J Orthod.* 1972;62:296–309.
16. Nance HN. The limitations of orthodontic treatment; mixed dentition diagnosis and treatment. *Am J Orthod.* 1947;33:177–223.
17. Johe RS, Steinhart T, Sado N, Greenberg B, Jing S. Intermaxillary tooth-size discrepancies in different sexes, malocclusion groups, and ethnicities. *Am J Orthod Dentofacial Orthop.* 2010;138:599–607.
18. Sanin C, Savara BS. An analysis of permanent mesiodistal crown size. *Am J Orthod.* 1971;59:488–500.
19. Smith SS, Buschang PH, Watanabe E. “Interarch tooth size relationships of 3 populations:” does Bolton’s apply? *Am J Orthod Dentofacial Orthop.* 2000;117:169–74.
20. Bolton WA. The clinical application of tooth size analysis. *Am J Orthod.* 1962;48:504–29.
21. Uysal T, Sari Z. Intermaxillary tooth size discrepancy and mesiodistal crown dimensions for a Turkish population. *Am J Orthod Dentofacial Orthop.* 2005;128:226–30.
22. Morley J, Eubank J. Macroesthetic elements of smile design. *J Am Dent Assoc.* 2001;132(1):39–45.
23. Morley J. A multidisciplinary approach to complex aesthetic restoration with diagnostic planning. *Pract Periodontics Aesthet Dent.* 2000;12(6):575–7.
24. Lombardi RE. The principles of visual perception and their clinical application to denture esthetics. *J Prosthet Dent.* 1973;29(4):358–82.

25. Ward DH. Proportional smile design using the recurring esthetic dental (red) proportion. *Dent Clin N Am.* 2001;45(1):143–54.
26. Chu SJ. Range and mean distribution frequency of individual tooth width of the maxillary anterior dentition. *Pract Proced Aesthet Dent.* 2007;19(4):209–15.
27. Wasche M, Hepps R, Geissberger M. Guiding principles of esthetic dentistry. In: *Esthetic dentistry in clinical practice*. 1st ed. Ames: Wiley-Blackwell; 2010. p. 9–17.
28. Levin EI. Dental esthetics and the golden proportion. *J Prosthet Dent.* 1978;40(3):244–52.
29. Donitza A. Creating the perfect smile: prosthetic considerations and procedures for optimal dentofacial esthetics. *J Calif Dent Assoc.* 2008;36(5):335–40. 342.
30. Snow SR. Esthetic smile analysis of maxillary anterior tooth width: the golden percentage. *J Esthet Dent.* 1999;11(4):177–84.
31. Gracis S, Chu S. The anterior and posterior determinants of occlusion and their relationship to aesthetic restorative dentistry. In: Tarnow D, Chu S, Kim J, editors. *Aesthetic restorative dentistry*. Mahwah: Montage Media; 2008. p. 65–97.
32. Sterrett JD, Oliver T, Robinson F, Fortson W, Knaak B, Russell CM. Width/length ratios of normal clinical crowns of the maxillary anterior dentition in man. *J Clin Periodontol.* 1999;26(3):153–7.
33. Kokich VG, Nappen DL, Shapiro PA. Gingival contour and clinical crown length: their effect on the esthetic appearance of maxillary anterior teeth. *Am J Orthod.* 1984;86(2):89–94.
34. Jones A, Robinson MY. A case study: esthetic and biologic management of diastema closure using porcelain bonded restorations for excellent and predictable results. *J Cosmet Dent.* 2002;18(3):72–83.

Korkud Demirel

In recent years, clinician's and patient's esthetic demand in dentistry have increased rapidly, driven by an enhanced awareness of beauty and esthetics. The ultimate goal in modern restorative dentistry is to achieve “white” and “pink” esthetics in harmony at the esthetically relevant zones. “White esthetics” refers to the natural dentition or the restoration of dental hard tissues with suitable materials and “pink esthetics” refers to the surrounding soft tissues, which include the interdental papilla and gingiva that can enhance or diminish the esthetic outcome. While treatment of gingival recessions is rather predictable (Fig. 9.1) with current sophisticated techniques, reconstruction of the missing interdental papilla is still one of the most challenging and least predictable problems (Fig. 9.2).

Presence of a diastema results with missing interdental tissue; hence, restorative procedures to augment the diastema should also require soft tissue management. Since the interdental papilla is a small rounded protuberance in between two teeth, two implants, or a tooth and an implant or a pontic and a tooth or implant, management of any diastema consequently requires soft tissue management. Furthermore, management of the diastema may also change the mesiodistal dimensions of the clinical crown resulting in a discrepancy at the location of the zenith points (Figs. 9.3 and 9.4).

9.1 The Papilla

The presence and shape of the interdental papilla are dependent on the existence of the contact between two lateral walls of neighboring teeth or restorative structures, healthy periodontal tissues at the base, and the shape of the lateral walls. Indeed, papillae were observed to be present at all cases when the

K. Demirel, PhD, DDS
Periodontology, University of Istanbul Faculty of Dentistry, Istanbul, Turkey
e-mail: korkud.demirel@gmail.com

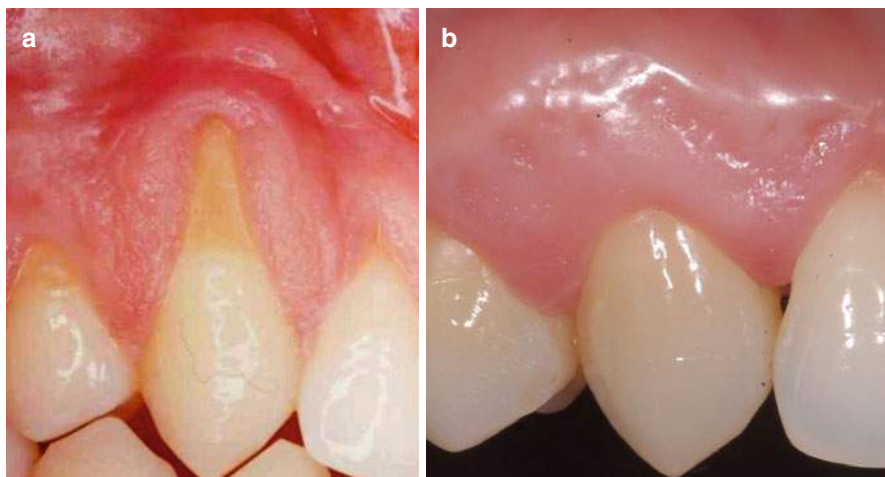


Fig. 9.1 Single Miller type II recession, treated with connective tissue grafting before (a) with a follow-up of 15 years (b)

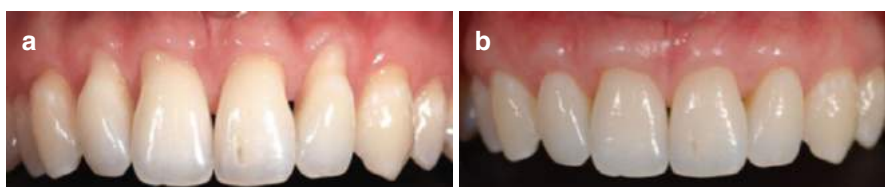


Fig. 9.2 Multiple Miller type III recessions treated with connective tissue graft before (a) and 2 years after (b). Note the changes of the interdentary soft tissue. Increasing the tissue volume at the interdental space does contribute to tissue fill without restorative intervention in the presence of contact between teeth and absence of periodontal disease

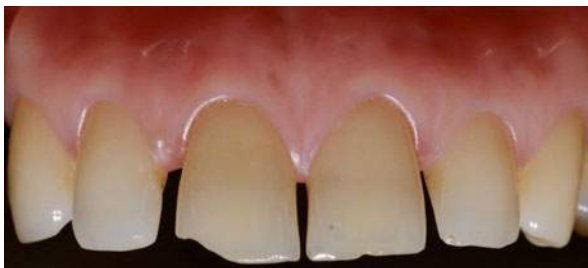

Fig. 9.3 Treatment plan of diastemas may include soft tissue management depending on the extent of proportional change in the clinical crown diameters. Cases with thin marginal gingiva with apparent zenith points require special attention

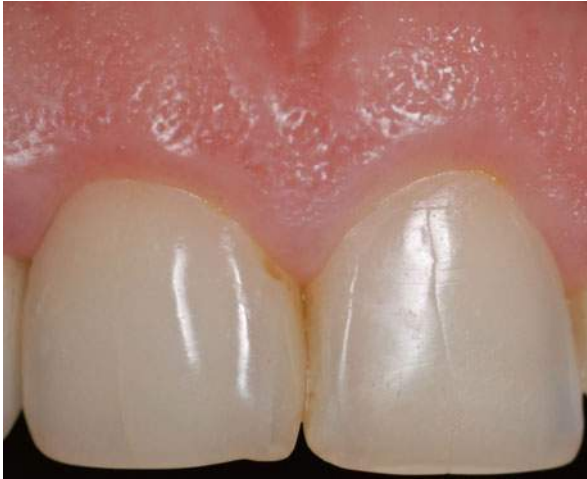

Fig. 9.4 The median diastema treated without soft tissue arrangement leaving a zenith far distal than the ideal position in tooth 11

distance between the interdental contact point and the alveolar crest was 4 mm or less. Two percent of the cases demonstrated loss of papillae with an increase of 1 mm of the distance between the contact and the alveolar crest. Generally speaking, papillae are present in almost all cases when the distance between the alveolar crest and the bone does not exceed 5 mm. However, 42 % of the cases failed to present a papilla when this distance is 6 mm, and a further 29 % lost papilla with an increase of another 1 mm, hence leaving papilla present in only 27 % of the cases observed. This demonstrates the significance of the vertical distance between the base of the papilla and the contact point between neighboring surfaces (Fig. 9.5).

On the other hand, factors affecting the presence and shape of interdental tissue are not limited only to the distance between the bone and contact. Tooth form, distance between two teeth at bone level, angulation of the roots, and the surface geometry are among other factors as well as the health of the soft tissue and the root surfaces. Factors that may affect the position and shape of the interdental tissue may be listed as follows.

9.1.1 Position of the Contact Point or Surface

Coronal positioning of the contact between neighboring structures creates a longer distance between the base of the papilla. This consequently affects the fill of the interdental space. When the biotype of the soft tissue is thick, indicating more tissue volume, giving a better chance to fill the space even the distance increases to the contact point from the base of the papilla.

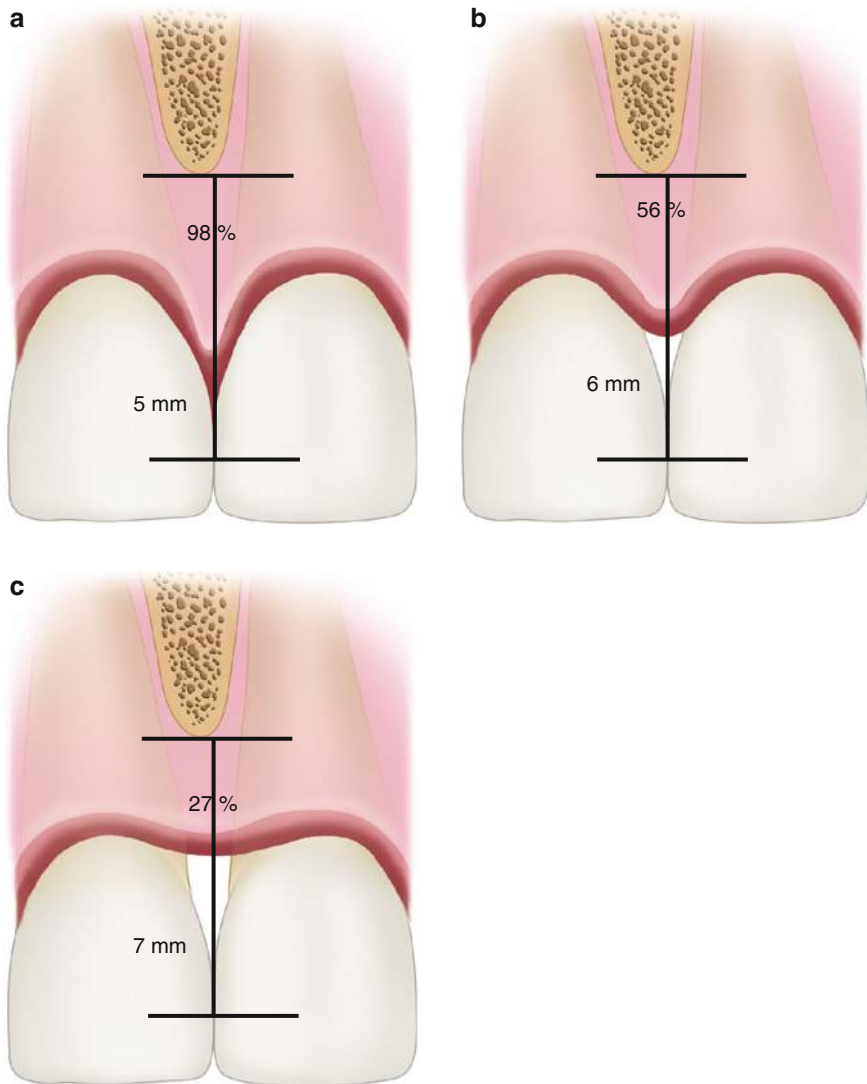


Fig. 9.5 The papilla was shown to be present 98 % of the time in the distance between the interdental contact and the tip of the alveolar bone (a), while at 6 mm, it was present 56 % of the time (b), and at 7 mm, it was only present 27 % of the time (c)

9.1.2 Lateral Walls of the Interdental Space

There are two components of lateral walls: apically the cementum surfaces where the fibers in the connective tissue are continuous with the root cementum and the epithelial attachment to the root surface immediately coronal to the connective tissue attachment. This attachment apparatus is delineated by the cemento-enamel junction and coronally followed by enamel surfaces to the point of contact with the

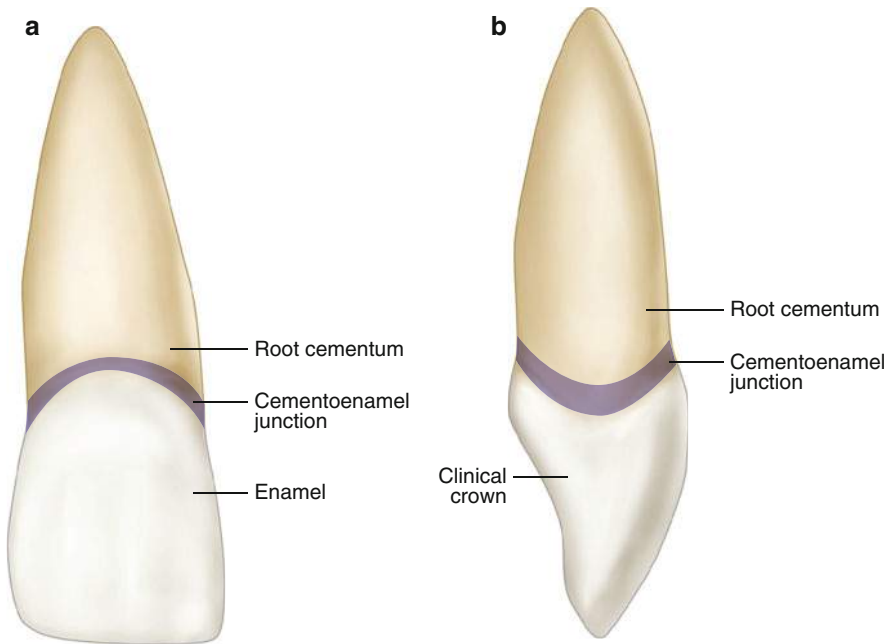


Fig. 9.6 When compared with the buccal site (a), the pronounced convex shape of the CEJ interproximally (b) promotes coronal attachment of the connective tissue fibers

neighboring tooth. The contour of the cemental walls is slightly concave from the buccal line angle to the palatal/lingual line angle. The distance as well as the buccoral concavity varies between teeth, generally speaking being longer and deeper in the posterior teeth. On the other hand, the enamel surfaces are rather convex in the coronal direction over the CEJ. The course of CEJ in the interdental aspect is pronounced convex to the coronal direction, giving more space for the root cementum over the alveolar bone level (Fig. 9.6).

9.1.3 Root Surface Cementum

In accordance with the interdental papilla, the importance of the root cementum at the proximal surfaces is more attributed to the collagen fibers attached to the cementum. The terminal portions of these fibers that are inserted to the cementum or bone are named as *Sharpey's fibers*. Once embedded in the bone or cementum, the endings calcify to a certain degree. These fibers are arranged in four groups according to their insertion and course (Fig. 9.7). The *circular fibers* run their course through the free gingiva and encircle the tooth in a cuff-like way. *Dentogingival fibers* are embedded in the cementum of supra-alveolar root surface and extend from the root into the connective tissue. *Dento-periosteal fibers* run their course apically over the facial or oral surfaces

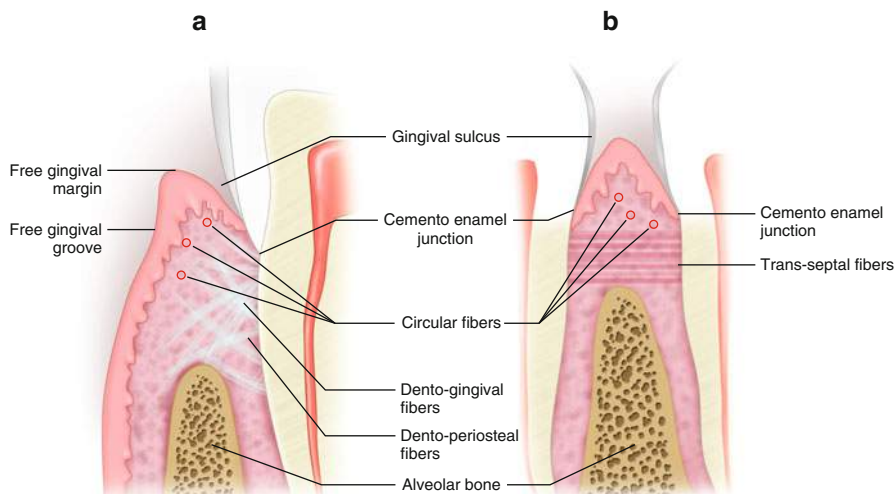


Fig. 9.7 The connective tissue fiber system provides attachment to the cementum surface. (a) Frontal plane; (b) sagittal plane. The circular fibers run their course through the free gingiva, dentogingival fibers are embedded in the cementum of supra-alveolar root surface, and dento-periosteal fibers run their course apically over the alveolar bone. Transseptal fibers run straight across the interdental septum and are embedded in the cementum of adjacent teeth. *CEJ* cemento enamel junction, *FGM* free gingival margin, *GS* gingival sulcus, *FGG* free gingival groove, *AB* alveolar bone

of the alveolar bone. *Transseptal* fibers run straight across the interdental septum and are embedded in the cementum of adjacent teeth. These fibers contribute to the tissue tonus, supporting the shape of the interdental tissue. Maintaining the health of the cementum, as well as the fibers, is the main determinant of the presence of interproximal tissue. Regardless of the etiology, inflammation has an impact on the continuity and tonus of the fibers thus changing the consistency of the tissue. This may lead to collapse and/or recession of the interdental protuberance of the soft tissue.

9.1.4 The Distance Between Neighboring Teeth

The distance between the roots or two neighboring teeth may have an effect on the presence and form of the interdental tissue. Furthermore, crown forms and divergent roots have a strong association with open gingival embrasures. Although none other than the crown form may be modified by restorative means, one should bear in mind other alternatives while planning for such treatments.

9.1.5 Health Status of the Tissues

Loss of interdental tissue may be due to periodontal disease and this is not in the scope of this chapter. On the other hand, efforts to build up contact between two teeth may also contribute to develop gingival inflammation due to improper contour and/or promotion of microbial dental plaque accumulation as well as physical irritation.

9.1.6 The Biotype

There is a positive correlation between the gingival thickness and papilla fill. It is generally agreed that thick gingival biotype allows better tissue manipulation and encourages creeping attachment. Since management of the diastemas comprises of relocating and rebuilding lateral walls of the papilla, it is crucial to have enough soft tissue volume in order to facilitate the interproximal tissue to elevate up to the contact point or area (Fig. 9.8).

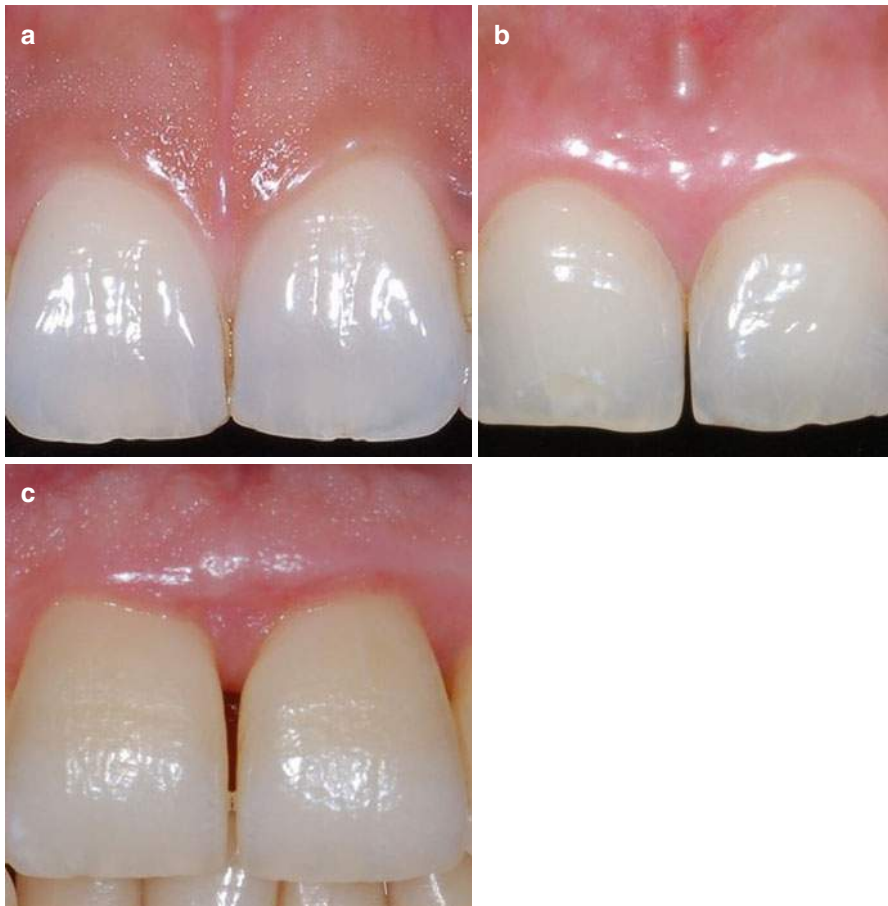

Fig. 9.8 Tissue biotype is one of the key determinants of interdental presence of soft tissue. The thin biotype (a) is likely to fill the interdental space only if the conditions are in favor and the normal (b) provides relatively more tissue volume at the interdental space; however, thick (c) biotype supports enough tissue to fill the space even in cases when other variables are not optimal

9.2 The Marginal Gingiva

The gingival zenith is defined as the most apical point of the buccal marginal gingiva. Since the marginal gingiva follows the cemento-enamel junction of the tooth, the location of zenith is defined by this anatomical landmark and the contour of the root surface as well as the marginal alveolar bone, in healthy gingival tissues. Arrangement of teeth and their location can also affect the position of zenith as well. Although the undulations of the gingival margin is determined under the tooth form and contour, there is a consensus that the location of zenith of the central incisors is located approximately 1 mm distal to the midline of the anatomical crown (Fig. 9.9). Location of the zenith in other anterior teeth is still under debate but presence of a sister tooth in the cross arch always make it easier to make clinical decisions. Zenith of the lateral incisors is usually concurrent with the midline, whereas in canines, zenith points are reported to be either at the midline or distal to it. Treatment of the central diastema is a challenge due to the unique nature of the interdental space between the two central incisors. Since the visual significance of symmetry grows by moving closer to the center of symmetry, the marginal gingiva of the two incisors plays a crucial role in esthetic perception. Building up diastemas may considerably change the crown proportions due to unilateral buildup of the clinical crown. This may lead to further discrepancy between the zenith point and the midline of the teeth, depending on the extent of the diastema to be treated.

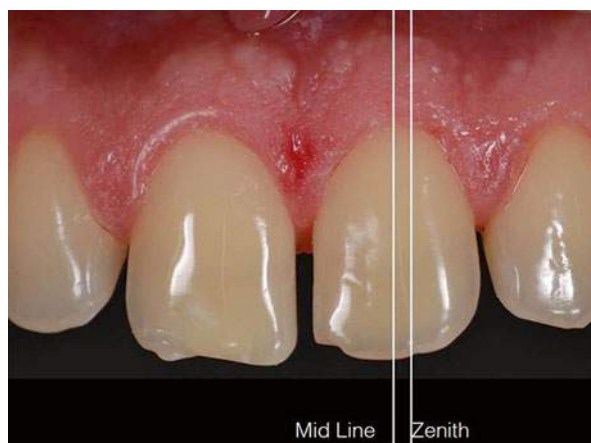

Fig. 9.9 Zenith of the central incisors is located approximately 1 mm distal to the midline of the anatomical crown

References

1. Chang LC. The association between embrasure morphology and central papilla recession. *J Clin Periodontol.* 2007;34(5):432–6.
2. Chow YC, Eber RM, Tsao YP, Shotwell JL, Wang HL. Factors associated with the appearance of gingival papillae. *J Clin Periodontol.* 2010;37(8):719–27.
3. Chu SJ, Tarnow DP, Tan JH, Stappert CF. Papilla proportions in the maxillary anterior dentition. *Int J Periodontics Restorative Dent.* 2009;29(4):385–93.
4. Gonzalez MK, Almeida AL, Gregghi SL, Pegoraro LF, Mondelli J, Moreno T. Interdental papillary house: a new concept and guide for clinicians. *Int J Periodontics Restorative Dent.* 2011;31(6):e87–93.
5. Olsson M, Lindhe J, Marinello CP. On the relationship between crown form and clinical features of the gingiva in adolescents. *J Clin Periodontol.* 1993;20(8):570–7.
6. Sharma AA, Park JH. Esthetic considerations in interdental papilla: remediation and regeneration. *J Esthet Restor Dent.* 2010;22(1):18–28.
7. Tarnow DP, Magner AW, Fletcher P. The effect of the distance from the contact point to the crest of bone on the presence or absence of the interproximal dental papilla. *J Periodontol.* 1992;63(12):995–6.
8. Zetu L, Wang HL. Management of inter-dental/inter-implant papilla. *J Clin Periodontol.* 2005;32(7):831–9.

Esra Yildiz, Taner Yucel, Ugur Erdemir, and Korkud Demirel

Abstract

Understanding of the etiology in the case of diastema before initiation of treatment procedure is important due to its multietiological factors. Therefore, a detailed medical and patient history, previous treatments, a series of periapical or panoramic radiographs must be obtained before initiation of the treatment. Due to multifactorial etiology of diastema, a multidisciplinary treatment approach should be designed. Not only facial, intraoral photographs must be obtained for analysis and measurements, but also models to make wax setup of the case must be studied. Afterwards, these should be shared with the patient as well as multidisciplinary team members for most appropriate treatment planning and best final outcome. When a multidisciplinary treatment procedure is planned between the multidisciplinary team members regarding the closure of diastema, collaboration should begin at the diagnostic phase for the correct treatment planning and successful outcome of the case.

Before initiation of any definitive restorative approach in the case of diastema closure, the clinician must understand its etiology [1]. It can be due to an anomaly in the anterior region such as mesiodens or hypodontia, size of the teeth as microdontia, enlarged and hypertonic labial frenum, pernicious habits as tongue trusting, periodontal problems, and cystic formation [1, 2]. Therefore, clinician must obtain a detailed medical

E. Yildiz, PhD, DDS (✉) • T. Yucel, PhD, DDS • U. Erdemir, PhD, DDS
Operative Dentistry, University of Istanbul Faculty of Dentistry, Istanbul, Turkey
e-mail: eyildiz1966@hotmail.com

K. Demirel, PhD, DDS
Periodontology, University of Istanbul Faculty of Dentistry, Istanbul, Turkey

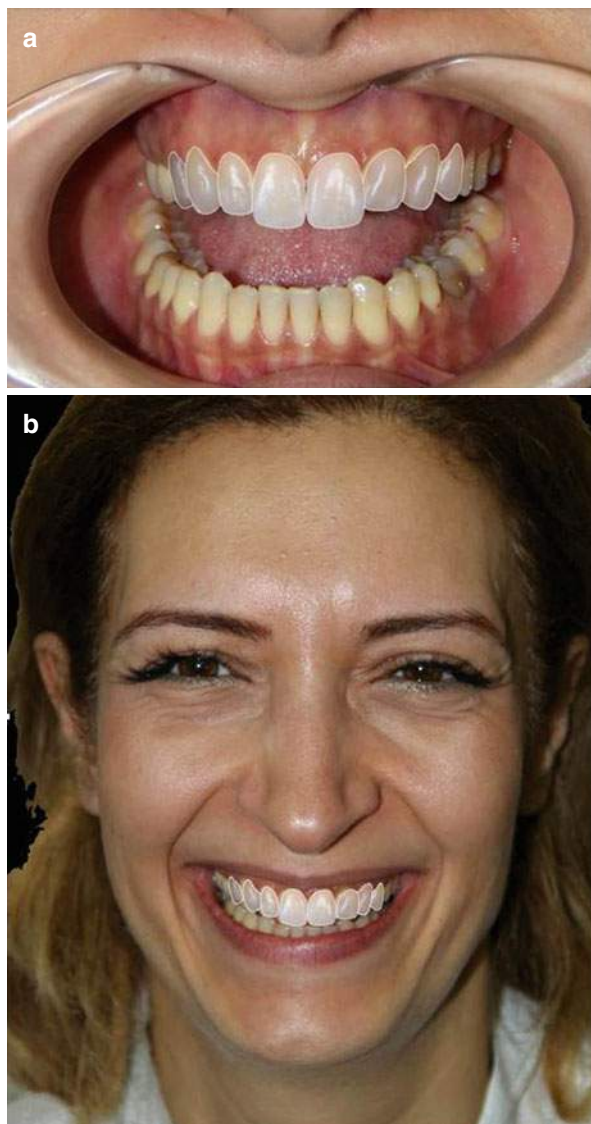
and patient history, previous treatments, and a series of periapical or panoramic radiographs of the patient before initiation of the treatment [2]. In the clinical examination session, clinician should also examine the dentition, occlusion, labial frenum, gingival structures, lips, as well as patient face regarding the esthetic treatment procedure and periodontal condition [1]. For a multidisciplinary approach procedure, clinician should also need to obtain facial and intraoral photographs, study models to make wax setup of the case for analysis and measurements, and share it with the patient as well as multidisciplinary team member for most appropriate treatment option and best final outcome [1]. If possible, clinician can also use a smile design software to show proposed treatment and planned restorative options as a guideline for esthetic evaluation (Fig. 10.1a, b). Understanding of diastema etiology is the most important step for the proper treatment and also pleasant final outcome of the procedure [2]. Several treatment procedures have been suggested for its proper treatments such as frenectomy [3, 4] where the enlarged frenum is present (Fig. 10.2), orthodontic treatments (Fig. 10.3) [1, 4–6], restorative treatments (Fig. 10.4a, b) [1, 6–10], and orthodontic-restorative combined procedures (Fig. 10.5) [8, 11–13]. In some situations, orthodontic and/or restorative treatments can successfully treat the midline diastema, but in some no single treatment method can treat all diastema cases, and hence, multidisciplinary treatment approach is necessary for a successful outcome. Restorative treatment of diastema closure can be successfully accomplished by the minimally prepared laminate veneers [5, 9, 14] and buildup with the resin composites [5, 15] in one visit. During diastema closure with composite resins, care must be taken to avoid creation of any over-counteracted restoration (Fig. 10.6) and appropriately created width/length ratio for a particular tooth.

Key Note

When a multidisciplinary treatment procedure is planned between the orthodontist and restorative dentist regarding the closure of diastema, then collaboration should begin at the diagnostic phase for the correct treatment procedure and successful outcome of the case.

When a multidisciplinary treatment procedure is planned between the orthodontist and restorative dentist regarding the closure of diastema, then collaboration should begin at the diagnostic phase for the correct treatment procedure and successful outcome of the case [16]. Not in all the diastema cases but in some of them that gingival tissue can be found in asymmetric and creation of a pleasant restoration, and also natural smile cannot be overemphasized during closure of diastema [5]. Creation of an esthetically pleasant final restoration that is in harmony with the gingival structure can be accomplished by the periodontal surgery. When a disproportionate tooth form is identified and this is due to the gingival soft tissue, clinician should need to alter gingival soft tissue first by periodontal surgery (i.e., gingivectomy or gingival grafting) before initiation of any definitive restoration (Fig. 10.7) [5]. Leveling of gingival structures can be also accomplished by the orthodontic intrusion or extrusion treatments [5].

Fig. 10.1 Showing proposed treatment and planned restorative options to the patient using smile design software. **(a)** Showing intraoral situation. **(b)** Full facial appearance of the proposed restorative options



Both median and polydiastemas can make an esthetically unpleasant appearance for the patients, and hence, many patients seek treatment of these occurrences for esthetical reasons. As described in previous chapters, occurrence of the diastema in the childhood due to physiological development is normal characteristics, and less than 2-mm diastema can close spontaneously by the growth and eruption of the canine teeth. If they do not close spontaneously by the growth of the children, less than 2–3 mm diastema can be successfully closed by the removable appliances. For adult patient with a wider diastema more than 2 mm, fixed orthodontic appliances can be used to close diastema. Tooth size discrepancies can also cause the formation of diastema, and these situations can be successfully treated by the orthodontic, restorative, or in combination

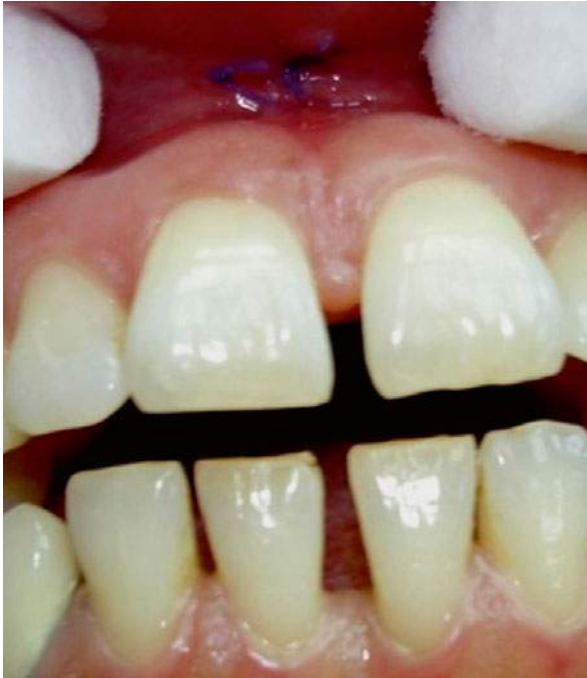

Fig. 10.2 A frenectomy case due to enlarged frenum

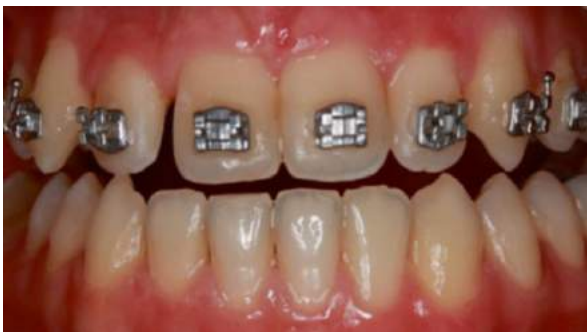

Fig. 10.3 Example of orthodontic treatment for diastema

of both treatment approaches. Generally fixed-type orthodontic treatment can provide better control in crown/root angulation, overbite, and overjet [2]. In the case of missing laterals that can cause midline diastema, closing of the median space and alignment of the teeth according to dental midline can successfully be done by orthodontic treatment [2]. Thereafter, missed lateral space can be reconstructed with fixed prosthesis (Fig. 10.8) or minimal invasively by using adhesive-type bridges.

Clinician can also use computer-assisted treatment planning, digital impression, and digital smile design by using computer-aided design/computer-aided

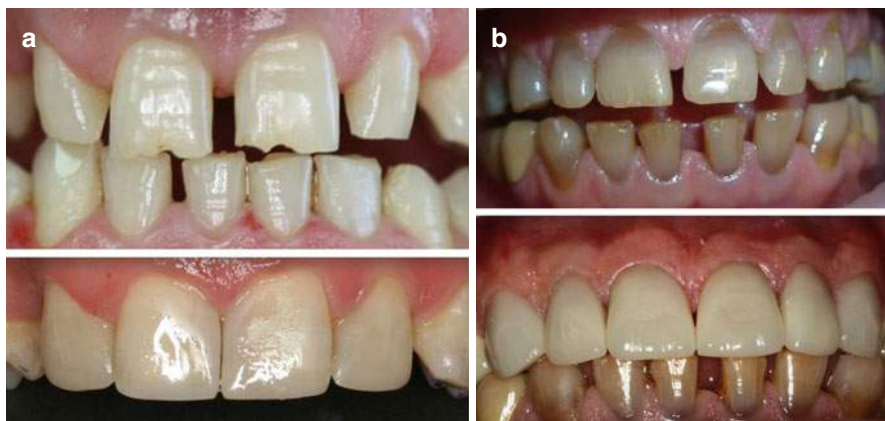

Fig. 10.4 Restorative treatment of diastema closure. (a) Diastema closure with direct composite resin. (b) Diastema closure with porcelain laminate veneers

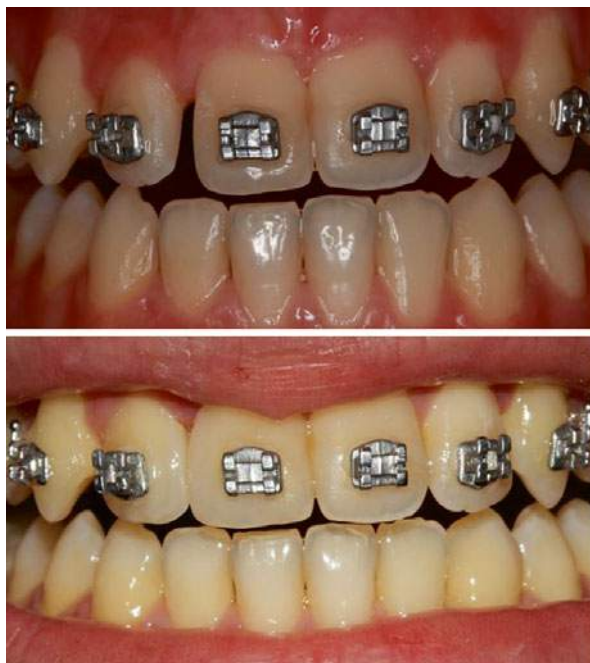

Fig. 10.5 Example of diastema closure with orthodontic-restorative combined procedures

manufacturing (CAD/CAM) systems [16]. However, little information is available regarding the fabrication of porcelain laminate veneers, esthetic characterization, longevity of the restorations, and applicability in clinical environment due to its relatively high cost [17–19].

In the case of median diastema, restorative closure of 2-mm space can be accomplished by the direct and/or indirect technique with no any esthetical problems. But

Key Note

If there is more than 2-mm wide median and/or polydiastema, diastema closure must be distributed in all anterior teeth to accomplish a proportionated tooth form and a pleasant final outcome.

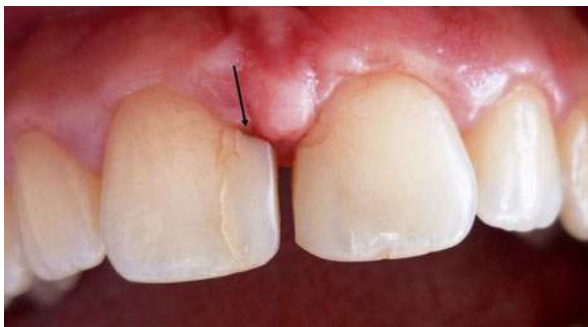

Fig. 10.6 Example of an over-counteracted (*arrow*) and did not properly finished restoration of diastema closure with composite resin

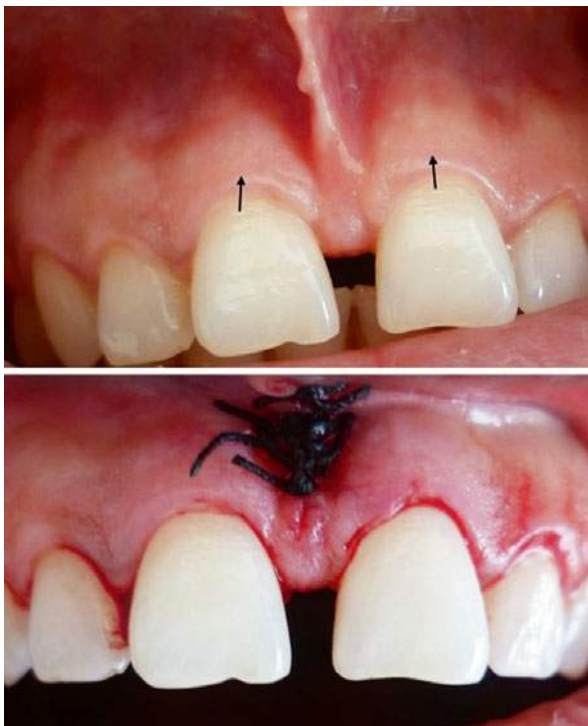


Fig. 10.7 Frenectomy and periodontal crown lengthening procedure due to short clinical crowns before initiation of definitive restoration

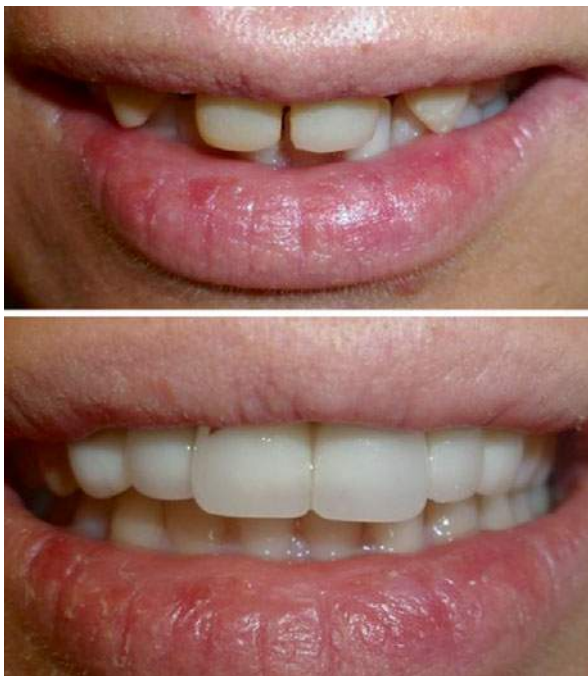

Fig. 10.8 Treatment of diastema with full ceramic fixed bridge in the case of congenitally missed laterals

in the case of more than 2-mm wide midline and/or polydiastema cases, restorative space must be closed proportionally, and diastema closure must be distributed in all anterior teeth to accomplish a proportionated tooth form and a pleasant final outcome [9]. If however when the midline space is closed by the two laminate veneers, then it will result disproportioned width/length ratio and relatively square appearance teeth (Fig. 10.9) with an unsatisfactory outcome [9].

If there is discoloration in the treatment-planned teeth, especially in the anterior region, then clinician should first do vital bleaching by using either in-office or home technique before initiation of definitive restoration for smile enhancement (Fig. 10.10a–c). In the case of discolored teeth especially for the mild to moderate tetracycline cases, bleaching can also be a useful treatment procedure before the preparation of the teeth for porcelain laminate veneers. With this treatment procedure, laboratory technician may not also need for the use of opaque layer on the veneer for masking the discoloration. In the case of tetracycline discoloration, bleaching procedure can also allow clinician less reduction in the tooth structures and, hence, avoid exposing discolored dark dentin layer in which tetracycline is deposited in the dentin layer. It must be bear in mind that clinician should postpone the definitive direct restoration to a reasonable time (preferably 2 weeks later) to not jeopardize the tooth-restoration bonding.

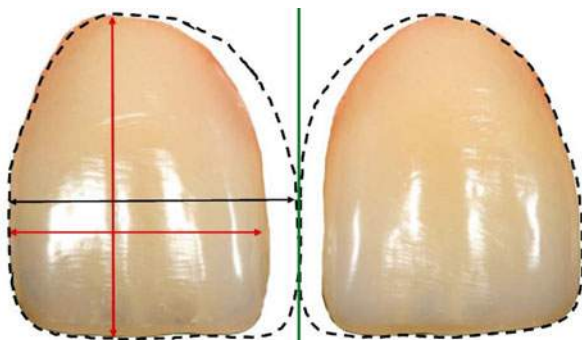


Fig. 10.9 Schematic illustration of the midline space which is closed by two laminate veneers. In this situation, it will result to a disproportioned width/length ratio and relatively square appearance teeth

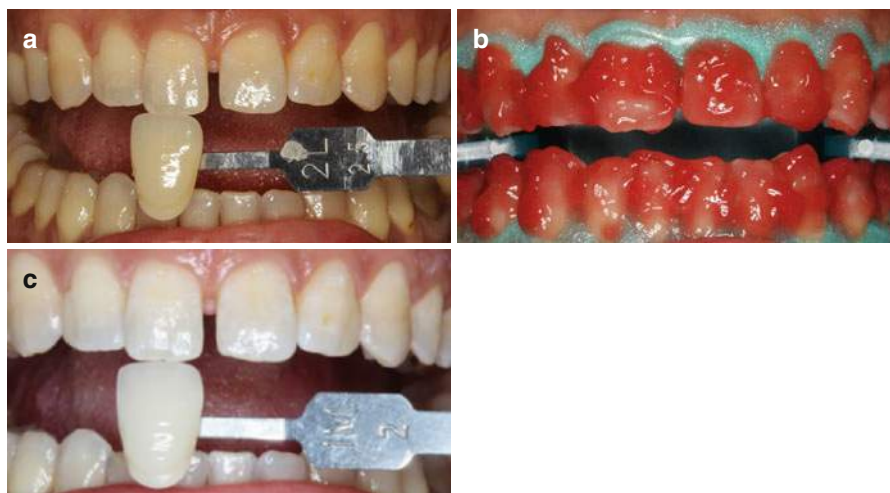

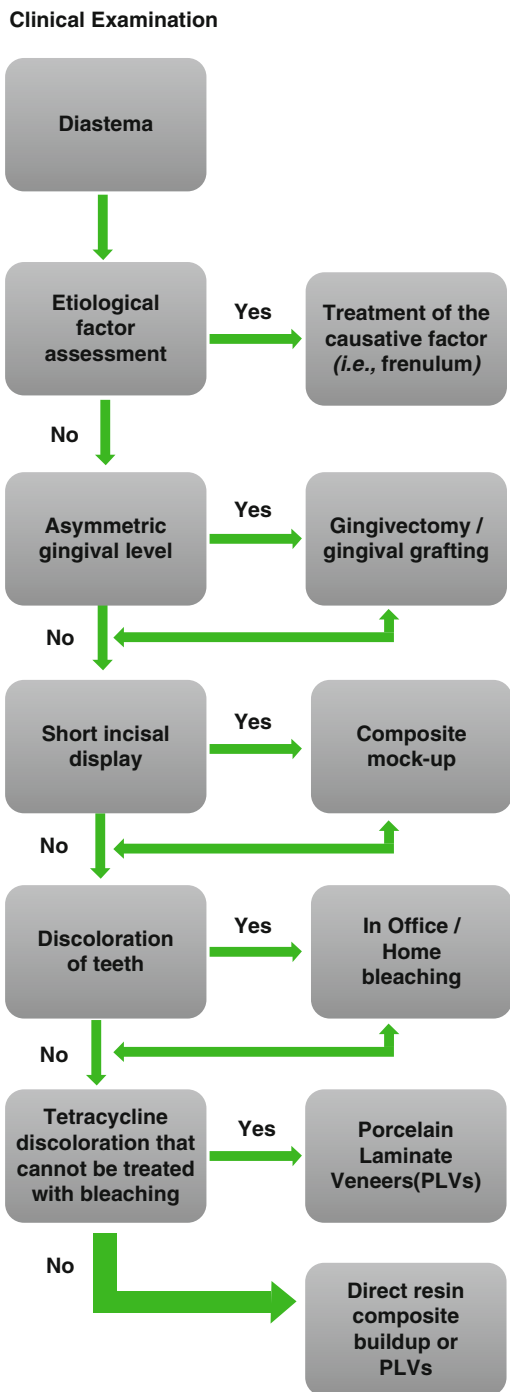
Fig. 10.10 If there is tooth discoloration especially in the anterior region, then clinician should first do vital bleaching by using either in-office or home technique before initiation of definitive restoration for smile enhancement. (a) Tooth shade of the patient. (b) In-office bleaching with 40 % hydrogen peroxide gel. (c) Tooth shade after two sessions of vital bleaching

In addition to the abovementioned factors, patient's preferences, expectations, and financial and time factors can also affect the treatment planning and performing of a successfully pleasant dental treatment [1].

Due to complexity of diastema cases, clinician should determine its contributing factors at first and then should communicate with the multidisciplinary team member for a successful and functional treatment plan. A comprehensive history and clinical evaluation along with relevant radiographs is necessary for a sound treatment plan of the case. Success for a case is not only dependent on the diastema closure but also to the long-term function and stability.

Clinician can follow the presented restorative treatment chart for diastema patients in their clinic (Fig. 10.11).

Fig. 10.11 Restorative treatment chart for the diastema cases in clinical applications



References

1. Chu CH, Zhang CF, Jin LJ. Treating a maxillary midline diastema in adult patients: a general dentist's perspective. *J Am Dent Assoc.* 2011;142(11):1258–64.
2. Huang WJ, Creath CJ. The midline diastema: a review of its etiology and treatment. *Pediatr Dent.* 1995;17(3):171–9.
3. Edwards JG. A clinical study: the diastema, the frenum, the frenectomy. *Oral Health.* 1977;67(9):51–62.
4. Delli K, Livas C, Sculean A, Katsaros C, Bornstein MM. Facts and myths regarding the maxillary midline frenum and its treatment: a systematic review of the literature. *Quintessence Int.* 2013;44(2):177–87.
5. Oquendo A, Brea L, David S. Diastema: correction of excessive spaces in the esthetic zone. *Dent Clin North Am.* 2011;55(2):265–8.
6. Chu FC, Siu AS, Newsome PR, Wei SH. Management of median diastema. *Gen Dent.* 2001;49(3):282–7.
7. De Araujo EM, Fortkamp Jr S, Baratieri LN. Closure of diastema and gingival recontouring using direct adhesive restorations: a case report. *J Esthet Restor Dent.* 2009;21(4):229–40.
8. Furuse AY, Herkrath FJ, Franco EJ, Benetti AR, Mondelli J. Multidisciplinary management of anterior diastemata: clinical procedures. *Pract Proced Aesthet Dent.* 2007;19(3):185–91.
9. Gurel G. The science and art of porcelain laminate veneers. Carol Stream: Quintessence Publishing Co. Ltd., Ergolding, Germany; 2003. p. 369–90.
10. Jones A, Robinson MY. A case study: esthetic and biologic management of diastema closure using porcelain bonded restorations for excellent and predictable results. *J Cosmetic Dent.* 2002;18(3):72–83.
11. Ittipuriphat I, Leevailoj C. Anterior space management: interdisciplinary concepts. *J Esthet Restor Dent.* 2013;25(1):16–30.
12. Sundfeld RH, Machado LS, de Oliveira FG, Santos EA, Lugato IC, Sundfeld ND. Conservative reconstruction of the smile by orthodontic, bleaching, and restorative procedures. *Eur J Dent.* 2012;6(1):105–9.
13. Beasley WK, Maskeroni AJ, Moon MG, Keating GV, Maxwell AW. The orthodontic and restorative treatment of a large diastema: a case report. *Gen Dent.* 2004;52(1):37–41.
14. Nazarian A. Closing the gap with minimal preparation veneers. *Dent Today.* 2006;25(12):70–1.
15. Willhite C. Diastema closure with freehand composite: controlling emergence contour. *Quintessence Int.* 2005;36(2):138–40.
16. Kavanagh C, Kavanagh D. Maxillary midline diastema – aetiology and orthodontic treatment. *J Ir Dent Assoc.* 2004;50(1):22–8.
17. Jordan A. Clinical aspects of porcelain laminate veneers: considerations in treatment planning and preparation design. *J Calif Dent Assoc.* 2015;43(4):199–202.
18. Vafiadis D, Goldstein G. Single visit fabrication of a porcelain laminate veneer with CAD/CAM technology: a clinical report. *J Prosthet Dent.* 2011;106(2):71–3.
19. Schmitter M, Seydler BB. Minimally invasive lithium disilicate ceramic veneers fabricated using chairside CAD/CAM: a clinical report. *J Prosthet Dent.* 2012;107(2):71–4.

Derya Germec Cakan and Korkmaz Sayinsu

Abstract

The treatment of diastema either by orthodontics, restorative dentistry, periodontology or a combination of these disciplines should be focused on the aetiological factors, patient needs, aesthetics and stable results. Identification of the aetiological factors and consideration of the dentofacial characteristics of the patient are essential for the appropriate therapy. Following diagnosis and individualised treatment planning, satisfactory treatment outcomes can be achieved with different orthodontic mechanics and approaches. This chapter will present management of spacing with orthodontics alone or as a part of interdisciplinary treatment depending on the causative factors. The timing and sequencing of the orthodontic treatment and retention protocol at the end of therapy will also be explained.

11.1 Introduction

Diastema can occur in deciduous, mixed or permanent dentition. According to epidemiological studies, the prevalence of midline diastema is high in the children of 6–9 years old, ranging between 43 and 97 % [1–3]. As mentioned in Chap. 2, the physiologic diastema of early dentitional stages generally does not necessitate orthodontic intervention because it spontaneously closes during development of the dentition. However, approximately 10 % of the orthodontic patients have been reported to have a midline diastema larger than 0.5 mm after the mixed dentition

D. Germec Cakan, DDS, PhD (✉)
Orthodontics, Yeditepe University, Dental Faculty, Istanbul, Turkey
e-mail: dgermec@gmail.com

K. Sayinsu, DDS, PhD
Orthodontics, Private Practice, Istanbul, Turkey

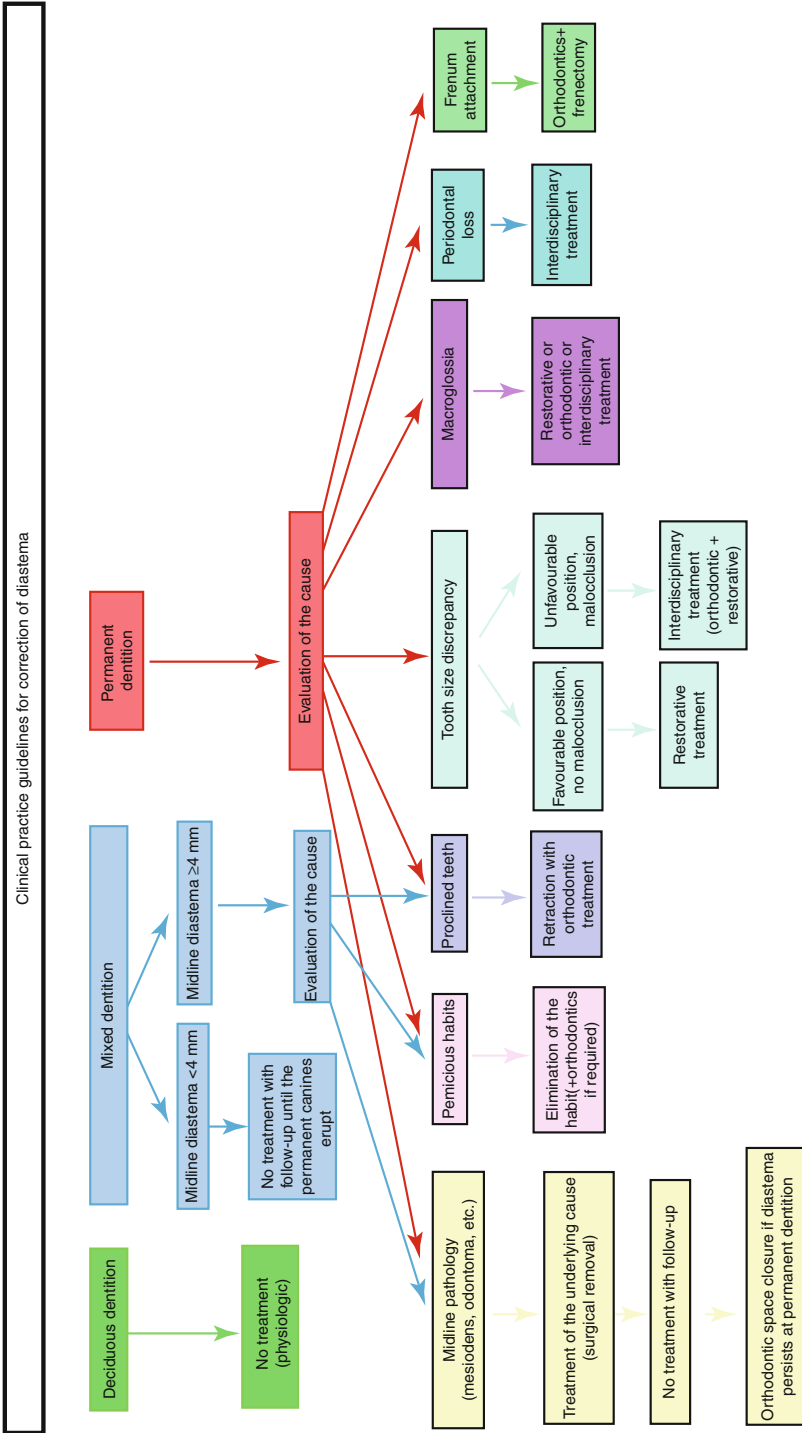


Fig. 11.1 Clinical practice guidelines for correction of diastema

period [4]. If the spacings in the dental arches persist after the eruption of the permanent canines, orthodontic treatment may be required.

Clinical practice guidelines of midline diastema treatment are summarised in Fig. 11.1. However, the clinician should also consider that these general guidelines may not apply in every case.

11.2 Orthodontic Closure of Diastema

Orthodontic closure of an anterior diastema can be accomplished either by mesio-distal and/or anteroposterior movement of the teeth. If the teeth are proclined and the overjet is increased, retraction of the incisors will automatically close the anterior spacing (Fig. 11.2). If the teeth are not protruded but laterally migrated (e.g. when the maxillary lateral incisors are congenitally missing), mesially directed forces will bring the teeth together to close a median diastema. In cases where the buccolingual position of the teeth and lips should be maintained, anterior movement of the posterior teeth would be preferred (Fig. 11.3). The decision of which orthodontic mechanics to use in order to obtain these forces and moments largely depends on the amount and localization of the diastema, the age and dentitional

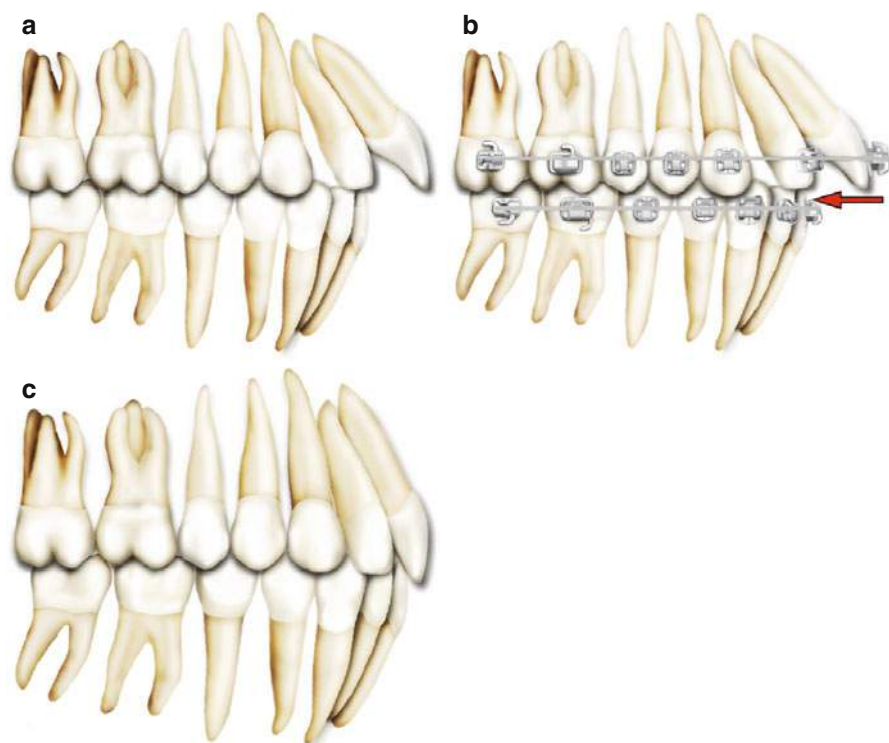


Fig. 11.2 (a–c) Diagrammatic illustration of anterior diastema closure with retraction of the flared maxillary incisors

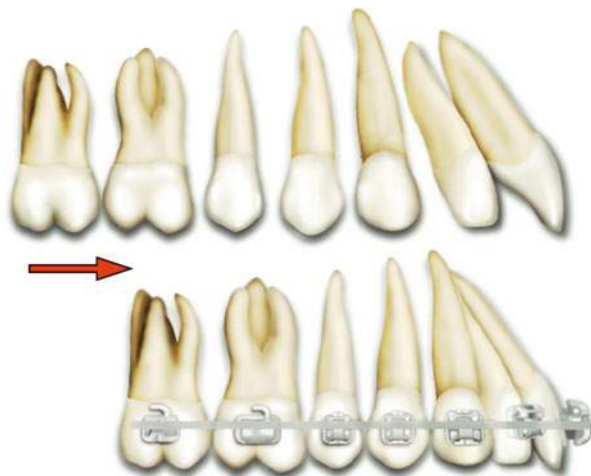


Fig. 11.3 Diagrammatic illustration of generalised diastema closure with mesialisation of the posterior teeth when the retraction of the incisors is contraindicated

stage of the patient, inclinations and angulations of the teeth and the presence of an adequate overjet.

Key Note

The evaluation of overjet is important in diastema cases. If the overjet is reduced, diastema cannot be closed by palatal tipping of the maxillary incisors.

Minor diastema (less than 2 mm) caused by distal crown angulation of the teeth can easily be corrected by tipping movement with removable appliances in an adolescent patient (Fig. 11.4). The finger springs of a removable Hawley appliance create mesially directed tipping forces to bring the teeth together. As an alternative, clear plastic appliances and rubber bands can also be used to close median diastema [5]. It is important to note though whenever possible, mechanics enabling three-dimensional tooth control should be chosen especially in complex cases (e.g. large median diastema, generalised spacings, deepbite, skeletal problems, microdontia, hypodontia). Therefore, active orthodontic treatment to close a diastema is preferably achieved by bodily tooth movement generated by fixed appliances (Fig. 11.5). For this purpose, anterior segmental archwires, 2×4 appliances (extending from first molars to incisors) or continuous archwires can be used (Fig. 11.6). Stiff and rectangular archwires provide good control of tooth movement during space closure.

Key Note

Never place elastics around the teeth to close a diastema without the use of orthodontic appliances. Uncontrolled subgingival dislocation of the elastics may cause severe periodontal breakdown.

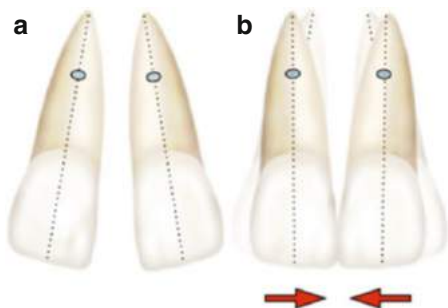


Fig. 11.4 (a) Distally tipped maxillary central incisors and minor median diastema. (b) Closure of the median diastema by mesial tipping of the incisors (note the final upright position of the teeth)

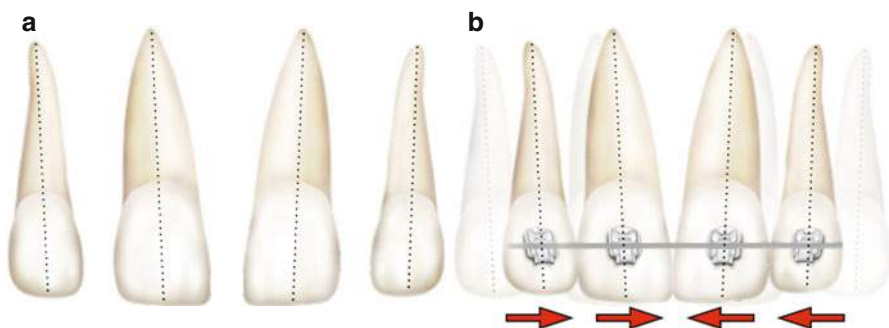


Fig. 11.5 (a) Generalised anterior diastemas. (b) Closure of the diastemas by mesially directed bodily tooth movement using fixed orthodontic appliances

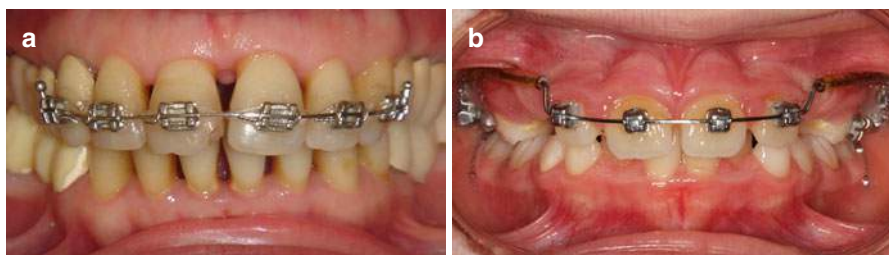


Fig. 11.6 The use of anterior segmental archwire (a) and 2x4 mechanics (b) for orthodontic treatment of maxillary diastemas

11.2.1 Case 1: Maxillary Midline Diastema

The patient in Fig. 11.7 had a maxillary midline diastema in mixed dentition. She was complaining about the unpleasant appearance of the spacings and irregularities. Although the physiological process was explained, she preferred not to wait for the eruption of the canines for psychological reasons. A removable appliance with finger springs was used to close the median diastema. Once the median diastema is closed, the finger spring on the left lateral incisor will be activated. Although the left lateral

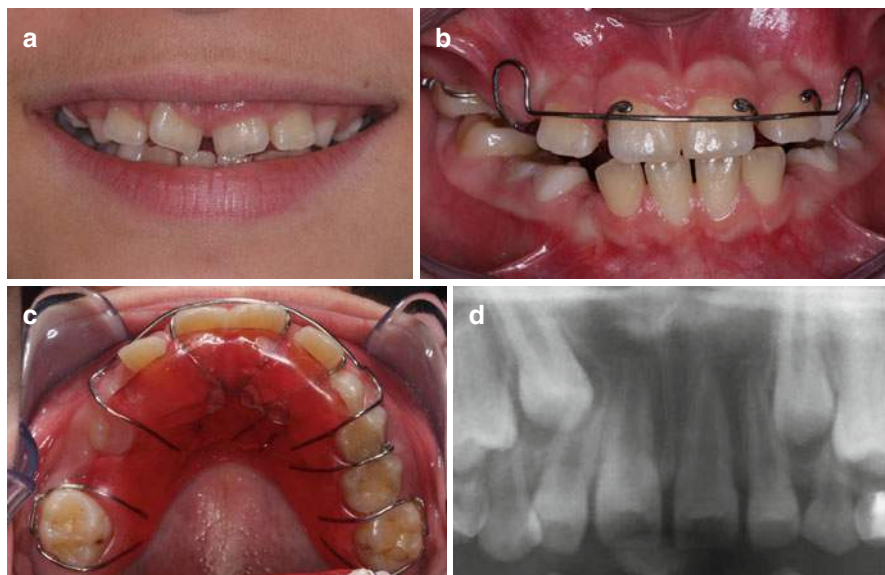


Fig. 11.7 (a) Mixed dentition patient with maxillary midline diastema. (b, c) A removable appliance with finger springs was used to close the median diastema. (d) Note the close proximity of the erupting right maxillary canine with the root of the lateral incisor. Because of the risk of root resorption, mesial tipping of the lateral incisor was avoided

incisor's medial movement is indicated, the right lateral incisor's mesial tipping is contraindicated because the cusps of the erupting canines are in close proximity with the roots of the lateral incisors at the early stages of dental development. Tipping the mesially inclined crowns of the lateral incisors in the ugly duckling stage will result in distal movement of the roots into the eruption path of the developing canines; thus, early orthodontic treatment may create risk of root resorption or canine impaction. Bishara [6] suggested to begin orthodontics after the cusp tips of the erupting canines have passed the apical third of the root of the lateral incisors. Therefore, orthodontic intervention should be avoided in the early mixed dentition period. The exceptions are midline diastema larger than 4 mm which may complicate eruption of the lateral incisors, presence of a midline pathology (mesiodens, odontome etc.) or bad oral habits.

11.2.2 Case 2: Generalised Diastemas

A 12-year-old boy, at the end of mixed dentition stage, presented with proclined maxillary and mandibular incisors and generalised spacings (Fig. 11.8a–d). Although the maxillary canines had not fully erupted, the tooth-arch dimension analysis (Hays Nance analysis, see Chap. 8) revealed excess spacing at permanent

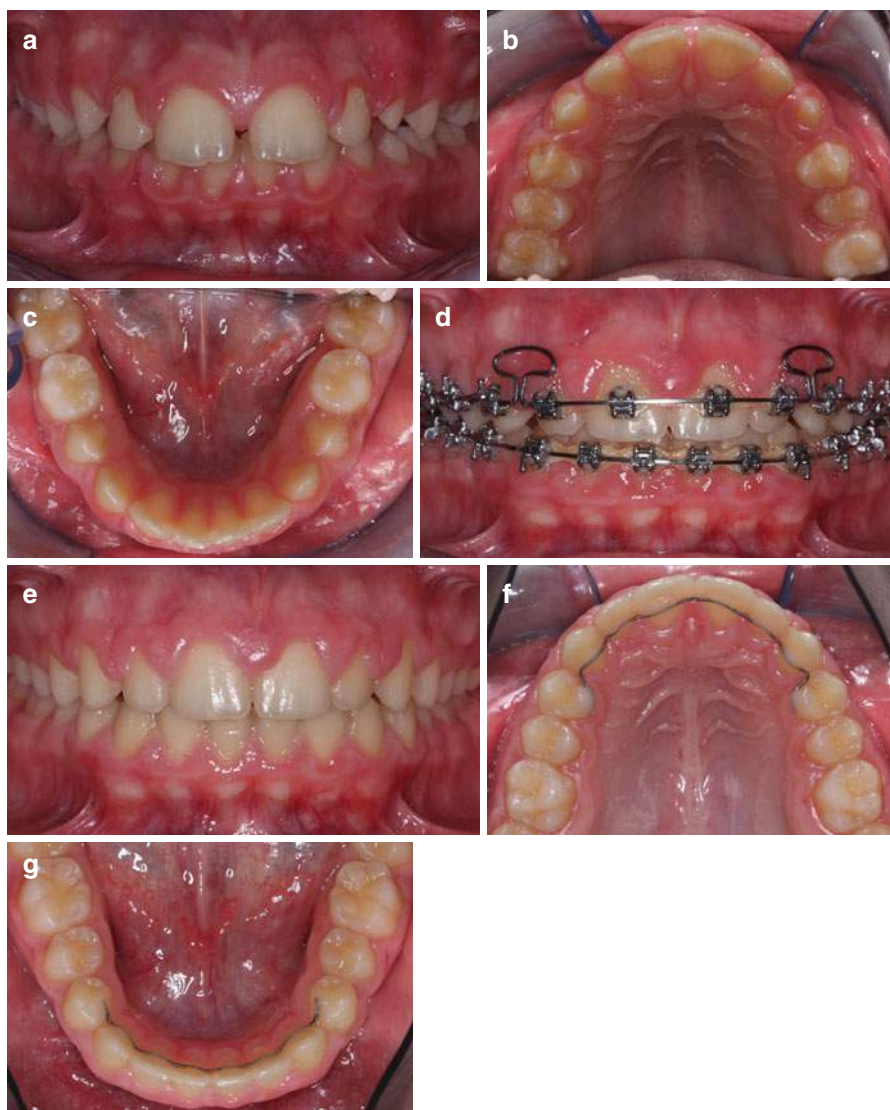


Fig. 11.8 (a–c) Frontal and occlusal intraoral views of generalised spacing before orthodontic treatment. (d) Closing the spaces with a consolidation arch in the maxillary dental arch and elastic chains in the mandibular dental arch during fixed orthodontic treatment. Headgear and intermaxillary elastics were used to reinforce the posterior anchorage. (e–g) Frontal and occlusal intraoral views after orthodontic space closure. Fixed lingual retainers were bonded to each tooth from right first premolar to left first premolar in the maxillary and mandibular dental arches following orthodontic treatment of polydiastema to prevent relapse

dentition. The maxillary and mandibular spacings were closed using fixed orthodontic appliances with elastic chains and a consolidation arch aiming to control root divergence and torque (Fig. 11.8e–g).

Key Note

In general, excessive proclination of the teeth generates spacing, whereas retraction of the teeth to their neutral position helps to close the diastemas. However, elimination of the aetiological factor is essential.

11.3 Management of Diastema Due to Abnormal Oral Habits: Breaking the Habit

The teeth are in equilibrium between forces generated by muscles, mastication and stabilisation of the periodontium [7]. If there is an alteration in the equilibrium due to an abnormal oral habit such as finger sucking, dental movement is likely to occur resulting in spacing in the dental arches in addition to other malocclusions. If the abnormal habit is stopped before the eruption of permanent teeth, normal cheek and lip pressures can establish the equilibrium and self-correction of the displaced teeth. However, if it persists in mixed dentition, orthodontic treatment may be required. In general, when the parafunctional cause is eliminated, a spontaneous correction will be observed [8]. There are several methods to stop abnormal oral habits. In orthodontics, myofunctional therapy and the use of habit breakers are very effective as a complementary to a psychological approach [8, 9]. After the patient has stopped the pernicious habit, wearing of the appliance is recommended for an additional several months.

11.3.1 Case 3: Lower Lip Sucking and Maxillary Spacing

An 11-year-old female patient presented with generalised maxillary spacing of 7 mm (Fig. 11.9a, b). Her history revealed that she was sucking her lower lip in her sleep throughout the night (Fig. 11.9c). Lower lip sucking habit caused proclination of the maxillary incisors which could not have been opposed by the forces of the upper lip. The aim was to normalise the extraoral muscle force and establish the equilibrium. A lip bumper appliance was used to break the sucking habit (Fig. 11.9d). This prefabricated appliance was placed at the level of the gingiva 2–3 mm in front of the lower incisors and 4–5 mm away from the buccal segments and was fixed to the molar tubes. It was reactivated when necessary. After 3 months of lip bumper therapy (full-time wear), the lower lip sucking habit was stopped, maxillary incisors spontaneously retroclined due to elimination of increased forces generated by sucking, and thus, maxillary diastemas were reduced (Fig. 11.9e, f). The residual diastemas were closed with fixed orthodontic therapy (Fig. 11.9g, h).

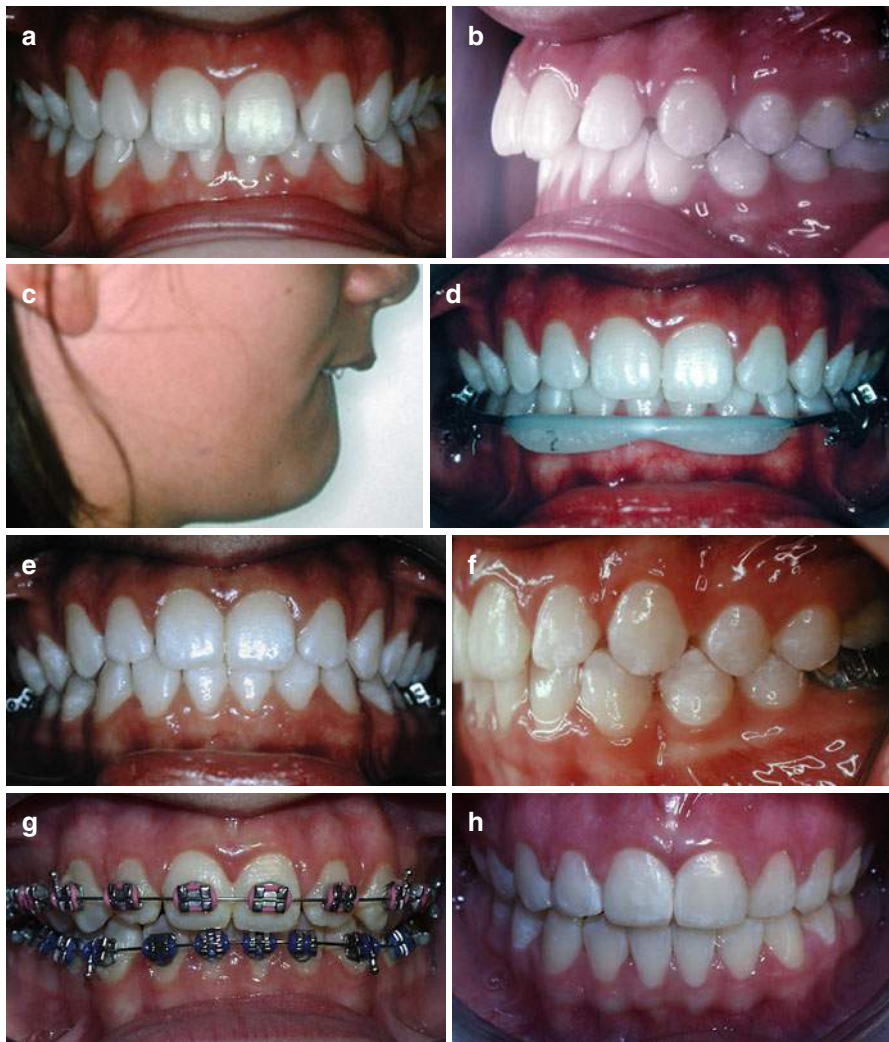


Fig. 11.9 (a, b) Generalised maxillary spacing and increased overjet. (c) Lower lip sucking exerting abnormal and unopposed force causing flaring of the upper teeth. (d) Use of lip bumper appliance to break the sucking habit. (e, f) Spontaneous reduction of maxillary spacing due to normalised muscle forces shows retroclination of the maxillary incisors after 3 months of lip bumper therapy. (g) Fixed orthodontic therapy phase. (h) Correction of the malocclusion at the end of orthodontic treatment (From Germeç and Taner [8]. Reprinted with permission from Angle Orthodontist)

11.3.2 Case 4: Finger Sucking and Maxillary Spacing

A female patient in early transitional dentition having a finger sucking habit showed increased overjet, labial inclination of the incisors and maxillary spacing (beyond physiologic diastema of mixed dentition) particularly on the right side where she inserted her right finger to suck (Fig. 11.10a–d). A myofunctional appliance was

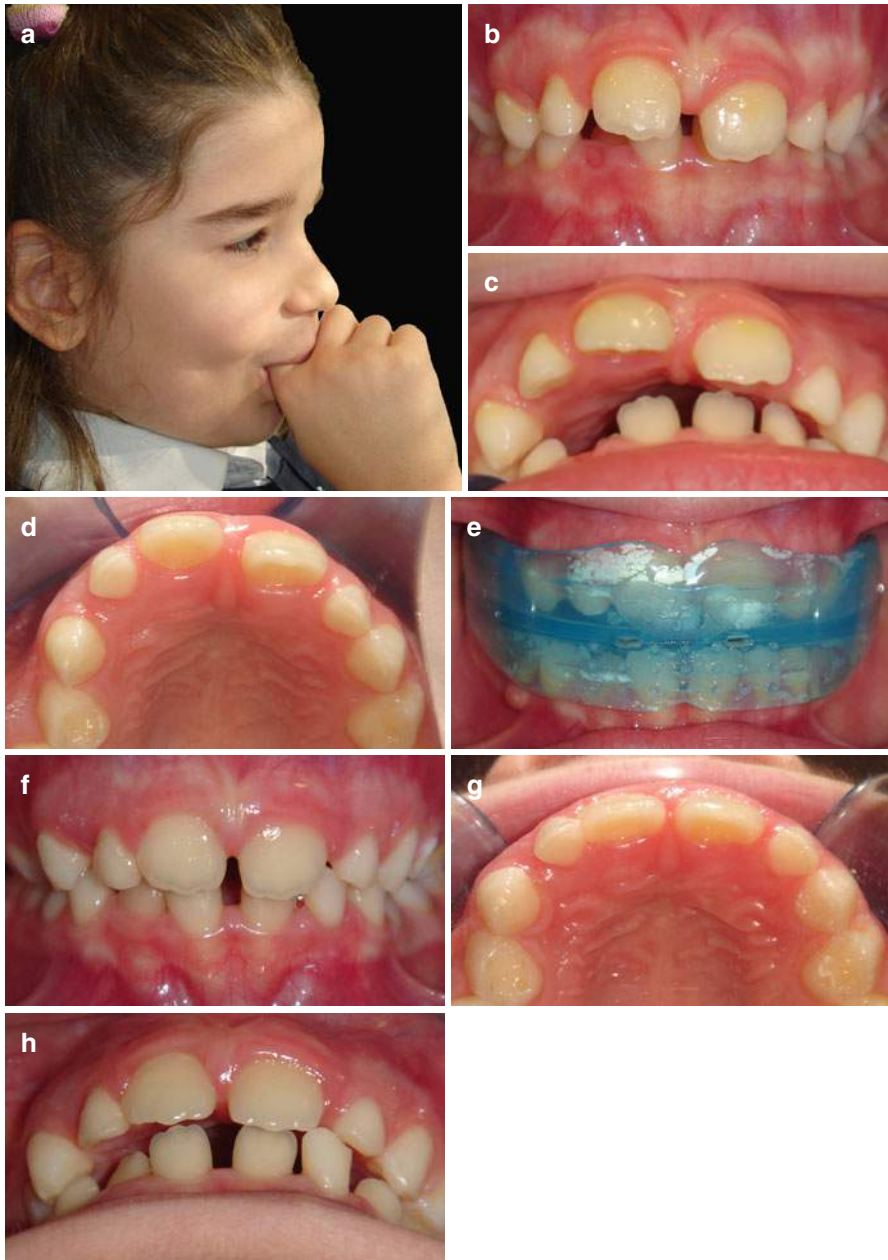


Fig. 11.10 (a–d) A 7.5-year-old patient with finger sucking habit, placing her finger on the right side of the dentition, leading to proclination of the incisor, increased diastema and overjet. (e) Soft myofunctional appliance was used to stop the habit and worn during sleep (when she used to suck her finger). (f–h) Intraoral photographs showing decrease in spacing, correction of overjet and retroclination of the incisors after 3 months of myofunctional therapy (From Tozlu and Germec [9]. Reprint permission from 7 Tepe Klinik)

used for 3 months (only at night) to stop finger sucking habit (Fig. 11.10e). This soft appliance with vestibular screens broke the finger sucking habit and thus eliminated the abnormal pressure caused by the finger sucking and established a balance between intraoral and extraoral muscles. In addition, it generated palatally directed forces to the overproclined right maxillary incisors. The final result was decreased maxillary spacing. At the end of myofunctional therapy, the maxillary spacing was reduced but not totally eliminated (ideal for a transitional period, see Chap. 2), and the overproclined incisors and the increased overjet were corrected (Fig. 11.10f-h).

11.4 The Role of Orthodontics in the Interdisciplinary Management of Diastema Due to Tooth Size Discrepancies and Missing Teeth

Diastemas caused by tooth size discrepancies can generally be treated by restorations. This treatment approach offers a quick solution and is readily accepted by patients. However, sometimes it is not possible to correct tooth size discrepancy with restorations alone due to unfavourable tooth positions and malocclusions (Fig. 11.11). Orthodontics helps to solve these problems by tooth movement, properly positioning the teeth and enabling an infrastructure for aesthetic restorations.

Interdisciplinary treatment starts with collecting accurate data, analysing it and composing a list of problems. Subsequently a treatment with alternatives is planned and discussed in the interdisciplinary team considering both treatment objectives and the patient's needs, demands and expectations. Once the final treatment plan is agreed and upon approval of the patient, every discipline works in collaboration to achieve the stated goals. This collaborative team work has some important steps. A crucial step of interdisciplinary treatment in diastema cases is to determine the final positions of the teeth and redistribute the spaces with orthodontics, which is guided by the principles of proportion and occlusion. The tooth size should be in harmony with the adjacent teeth and dental arch. The clinician can use the tooth proportions

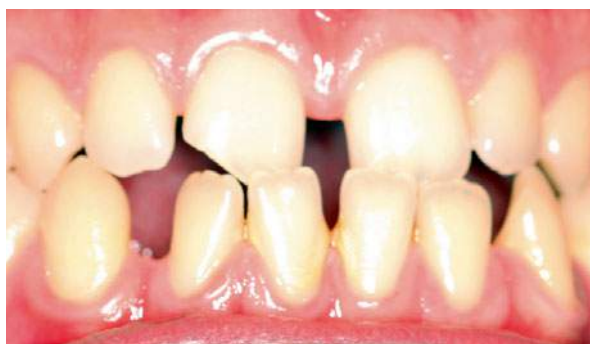

Fig. 11.11 A maxillary and mandibular generalised spacing case due to small teeth and large alveolar base. Restorative approach without orthodontics for this case presenting a Class III malocclusion with anterior crossbite, a midline diastema of 3 mm, disproportionate localisation of the maxillary and mandibular spacings between teeth may result in compromised aesthetics and impede the survival of the restorations

(e.g. width/length ratio, relationship between the sizes of the adjacent teeth) and tooth size analysis (see Chap. 8) as a guide when redistributing the spaces between the teeth. A diagnostic wax set-up is also very helpful to visualise the final result (see Chap. 4), which will provide information about the final position of the teeth, the number of teeth to be restored, the position and dimensions of the restorations and the timing, sequencing and progress of the treatment.

When the discrepancy involves several teeth, the ideal treatment is to redistribute the spacings between these undersized teeth (Fig. 11.12). Otherwise, if the spacings in the maxillary arch are collected between lateral incisors and canines, this will result in very large, disproportionate lateral incisors which might also impede the gingival health as well as aesthetic outcomes.

Key Note

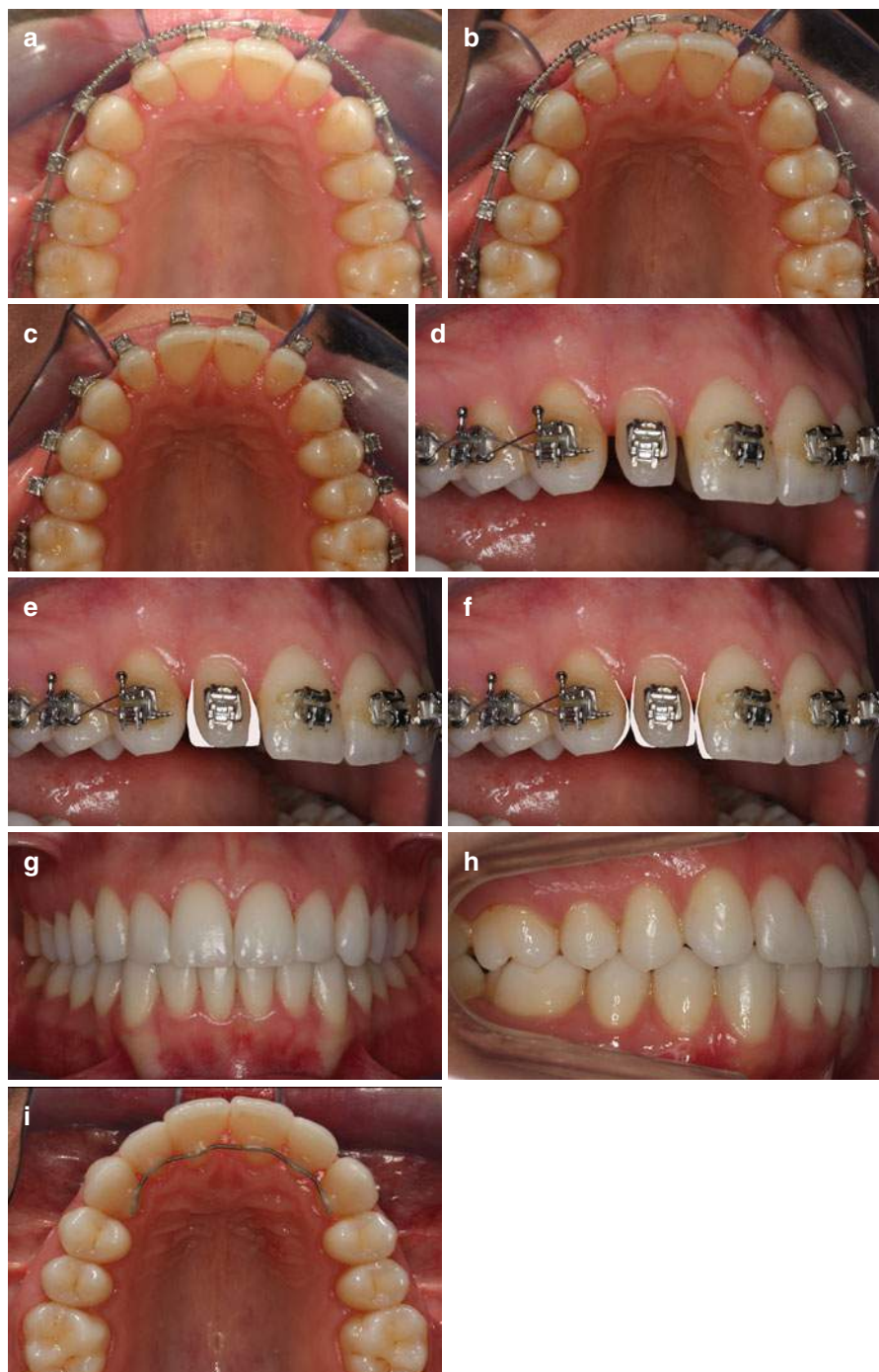Dental proportional norms and occlusal requirements guide the clinician when redistributing the spaces and repositioning the teeth in a complicated generalised diastema case.

The size and shape anomalies of the teeth are mostly seen in upper lateral incisors [10]. When there are small- or peg-shaped lateral incisors, the tooth can be positioned slightly closer to the central incisor, because the distal curvature of the lateral incisor is more convex than the mesial curvature [11]. In other words, the orthodontist should leave more space on the distal than the mesial side of the upper lateral incisor to enhance the restorative results (Fig. 11.13).

Key Note

Redistribution of the spaces and positioning of the teeth with orthodontics require close collaboration and communication between orthodontist and restorative dentist not only in planning but also during treatment. Therefore, the orthodontist should refer the patient to the restorative dentist for the evaluation of the final tooth position prior to debonding of the braces.

Fig. 11.12 Redistribution of the spaces in a case with maxillary anterior tooth size discrepancy. (a) When the discrepancy involves several teeth, collecting spaces distal to lateral incisors will ruin the tooth form and proportions. (b) Redistribution of the spaces between anterior teeth using push coils. Note the right side is appropriate, whereas the left side requires distal movement of the lateral incisor. (c) Proper positioning of the anterior teeth prior to restorations. Note that the spacings were generated on the mesial and distal side of the undersized teeth. (d) Spacing on the mesial and distal side of the lateral incisor. (e) Avoid building up only one tooth and creating a large tooth as shown in the illustration. (f) Illustration of the build-ups guided by width/length ratios and proportions between anterior adjacent teeth. (g–i) Intraoral views showing proportional anterior tooth size and good occlusal relationships at the end of interdisciplinary treatment accomplished with direct composite restorations of the six anterior teeth (Restorations by Dr. Esra Can Say)



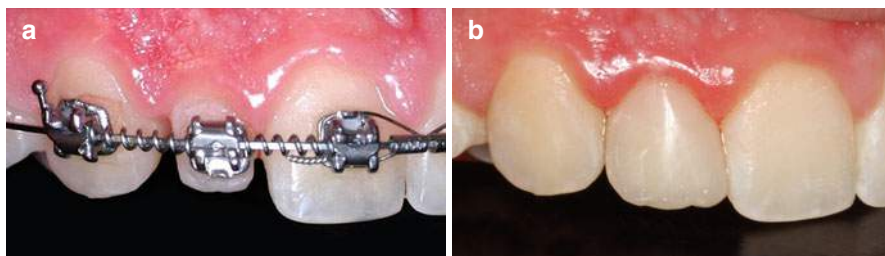


Fig. 11.13 (a) Slightly mesial positioning of the microdentic upper lateral incisor. (b) After direct composite restoration (both mesial and distal sides of the lateral incisor were built up) (Restoration by Dr. Umut Cakan)

Another important aspect of interdisciplinary management of diastema is the timing and sequencing of the treatments. Treatment timing and sequencing depends on the initial position of the teeth, the presence of a malocclusion and demands of the patient. In general orthodontics is becoming easier when there are contact points between teeth, which prevent jiggling. Therefore, whenever possible, it is wise to begin interdisciplinary treatment with provisional restorations before orthodontic therapy. The key point is to restore teeth with respect to its axial inclination meaning the radiographic evaluation is essential. When the tooth positions and occlusion are not suitable for build-ups, restoration of the teeth is generally recommended after the correction of tooth positions and during distribution of the spaces in the last stages of orthodontic treatment. The final restorations should be postponed to the end of active orthodontic treatment for several reasons. Patients experiencing gingivitis with swollen and bleeding gingiva are not uncommon during orthodontic treatment due to poor oral hygiene. A healthy and properly levelled gingival tissue is required before any kind of restorations are made. Therefore, gingival status should be optimised by periodontal care after the removal of the braces. In addition, if bleaching is necessary, the sequencing is first orthodontics, followed by bleaching and finally restorations.

The interdisciplinary approach is the gold standard for most patients with diastema due to undersized incisors. For patients who reject this approach, increasing the root divergence with orthodontics may be an alternative method to treat generalised spacing. When the positive angulation of the teeth (the root divergence) is increased, the crown occupies more space because the mesiodistal width of the tooth is also increased [12]. However, distal tipping of the roots of the anterior teeth results in canted incisal edges that should be reshaped for aesthetic reasons. This treatment option should only be preserved for patients with minor discrepancies who do not accept restorative approaches.

11.4.1 Case 5: Tooth Size-Arch Size Discrepancy and Bimaxillary Generalised Spacing; Redistribution of the Spaces

The chief complaint of this adult female patient was the unaesthetic appearance of her smile. Her clinical examination and cephalometric analysis revealed that the inclination of the maxillary and mandibular incisors should be maintained to preserve the position of the lips in her orthognathic profile (Fig. 11.14a-f). Her model

analysis showed a tooth size-arch size discrepancy caused by small mesiodistal widths of the entire dentition compared to large arch size. Furthermore, the presence of previously extracted right maxillary first molar contributed to the creation of diastema due to distal migration of the premolars. Maxillary midline diastema was 3.6 mm. Bolton analysis revealed mandibular anterior excess of 2.8 mm. A restorative approach alone would lead to disproportionate, oversized central incisors with distorted crown shape and compromised periodontal health. An interdisciplinary treatment was planned. The role of orthodontics was to redistribute the spacing to facilitate restorative and prosthetic dentistry and treat the malocclusion characterised by deepbite and posterior scissors bite (Fig. 11.14g). At the end of the orthodontic treatment, teeth were aligned and properly positioned enabling fabrication of proportional restorations and prosthetic rehabilitation. Maxillary central and lateral incisors were built up by direct composite restorations (Fig. 11.14h-m).

Key Note

The essential of diastema closure is to establish proper tooth proportions that are as close to the ideal as possible. From an orthodontic perspective, the orthodontist should not try to close all the spaces if there are tooth size anomalies (e.g. peg-shaped lateral incisors). From a restorative perspective, the clinician should not restore teeth when it is impossible to achieve proportional aesthetic results. In either situation, one must seek for interdisciplinary treatment because no matter how well treated, unaesthetic results will lead to patient dissatisfaction.

11.4.2 Case 6: Tooth Size -Arch Size Discrepancy and Bimaxillary Generalised Spacing; Orthodontic Closure of the Diastemas and Periodontal Surgery

A 30-year-old female patient's chief complaint was the spacing between her teeth. She had maxillary and mandibular polydiastema, deepbite and Class II skeletal and Class I molar relationships (Fig. 11.15). The generalised spacing was mainly due to tooth size-arch size discrepancy and proclined mandibular incisor. Therefore, the treatment plan included closure of the spacing by incisor retraction. At the end of 15 months of orthodontic treatment, the inclination of the incisors was corrected, and bimaxillary spacing was closed. However, the gingival tissue was hypertrophic and the tooth width/length ratio was compromised. To obtain satisfactory aesthetic outcomes, periodontal surgery was carried out. Gingival margins were levelled and proper width/length ratio was achieved after periodontal surgery.

11.4.3 Case 7: Tooth Size-Arch Size Discrepancy and Bimaxillary Generalised Spacing; Generating Space for Extra Teeth

A 35-year-old male patient was complaining about the spacings between his upper teeth. He had bimaxillary generalised spacing due to tooth size-arch size

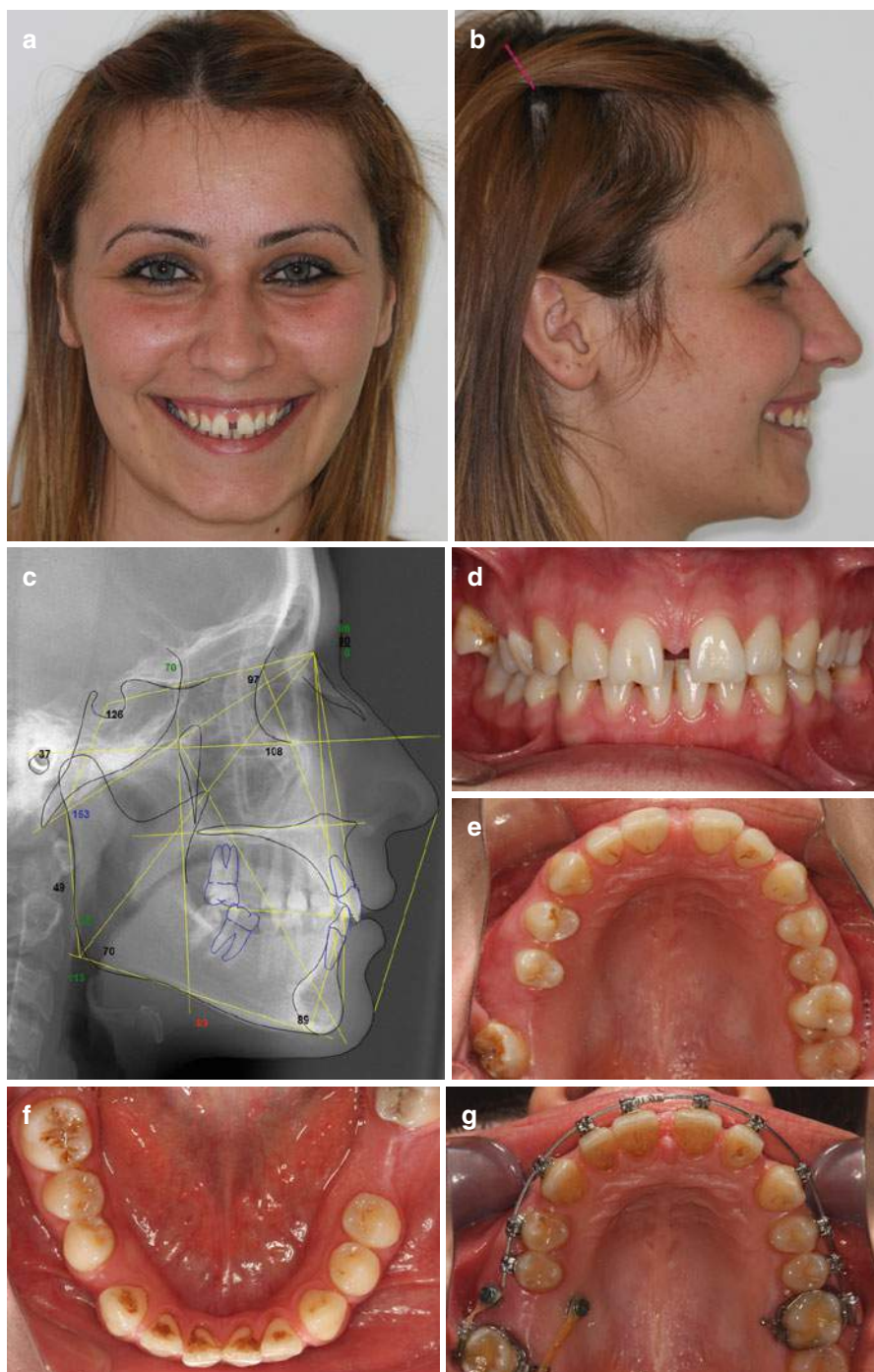


Fig. 11.14 (a–f) A female patient with a large median diastema, generalised bimaxillary spacing due to small tooth size and previously extracted teeth. (g) Redistribution of the maxillary spaces and correction of scissors bite. (h–m) At the end of interdisciplinary treatment (maxillary incisors were built up by direct composite restorations. Note that abraded incisal edges of the maxillary central incisors were also restored. The incisor and lip positions were maintained during orthodontic treatment)

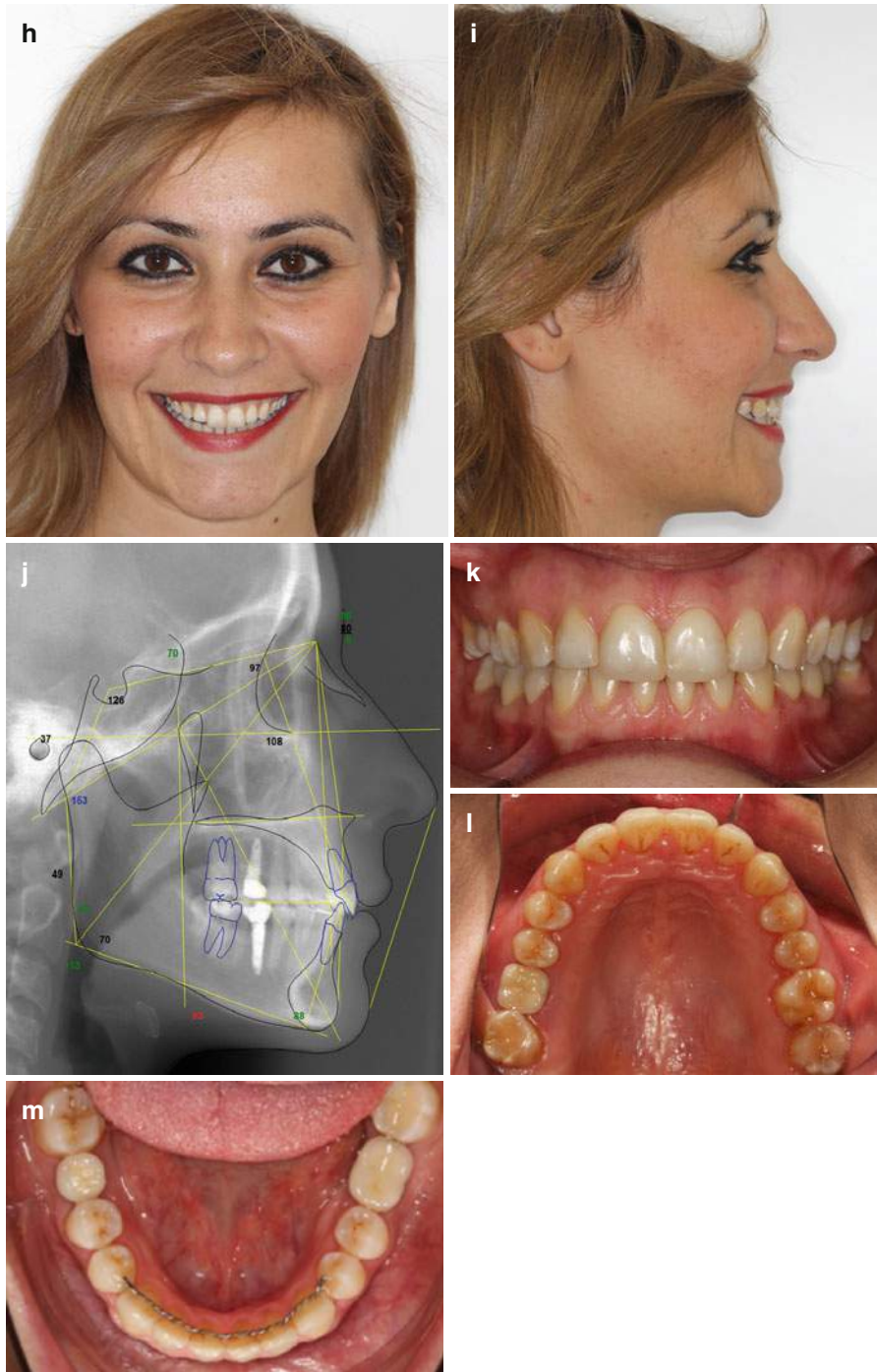


Fig. 11.14 (continued)

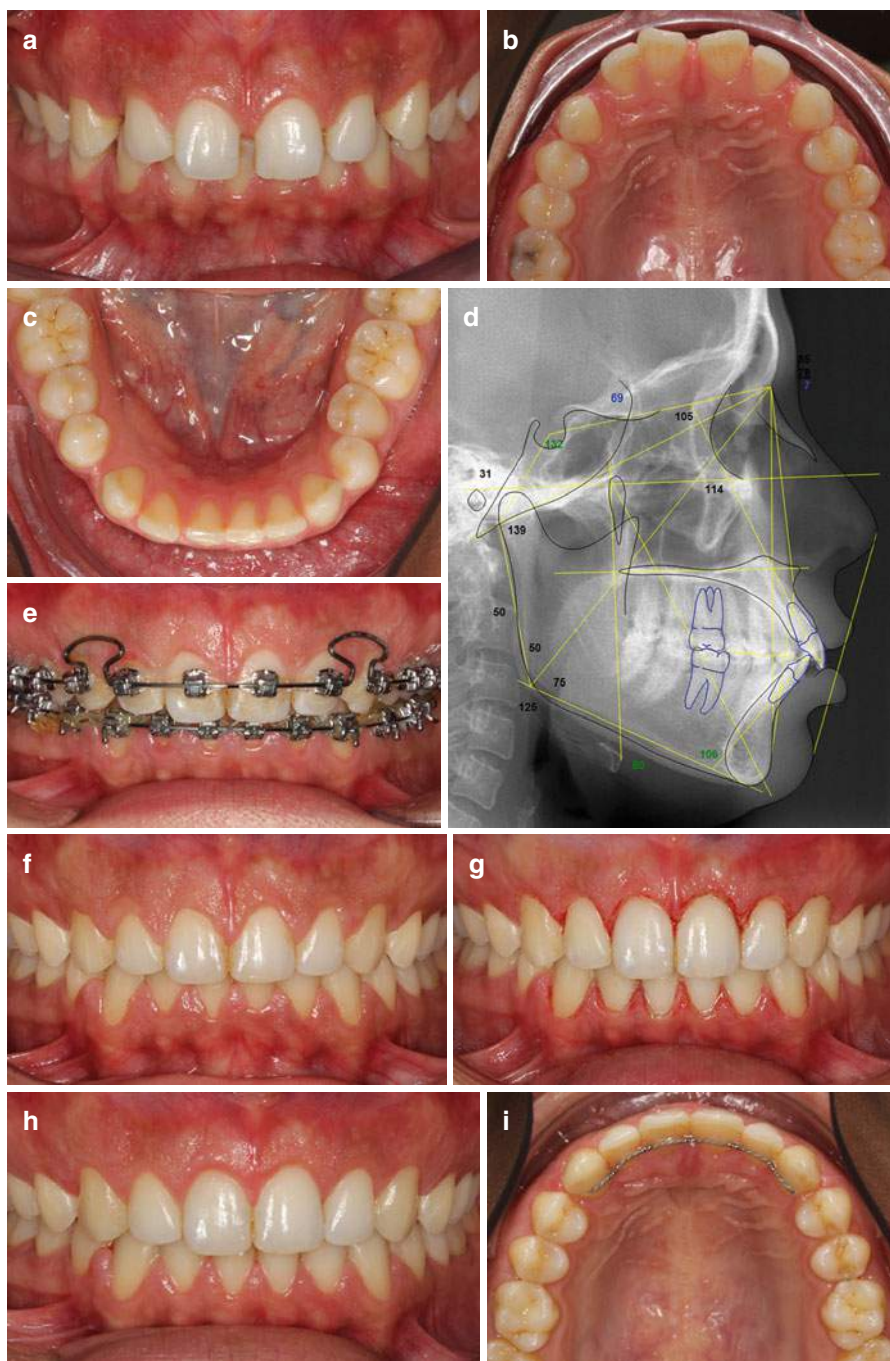


Fig. 11.15 (a–d) A female patient with bimaxillary spacing due to tooth size-arch size discrepancy and proclined mandibular incisors. (e) Closure of the spaces with fixed orthodontic appliances. (f) Intraoral view at the end of orthodontic treatment. Note hypertrophic gingival tissue and disproportionate width/length ratio of the teeth. (g) Correction of the gingival level and width/length ratio with gingivectomy. (h–k) Final records showing good occlusal and aesthetic outcomes at the end of orthodontic and periodontal interdisciplinary treatment

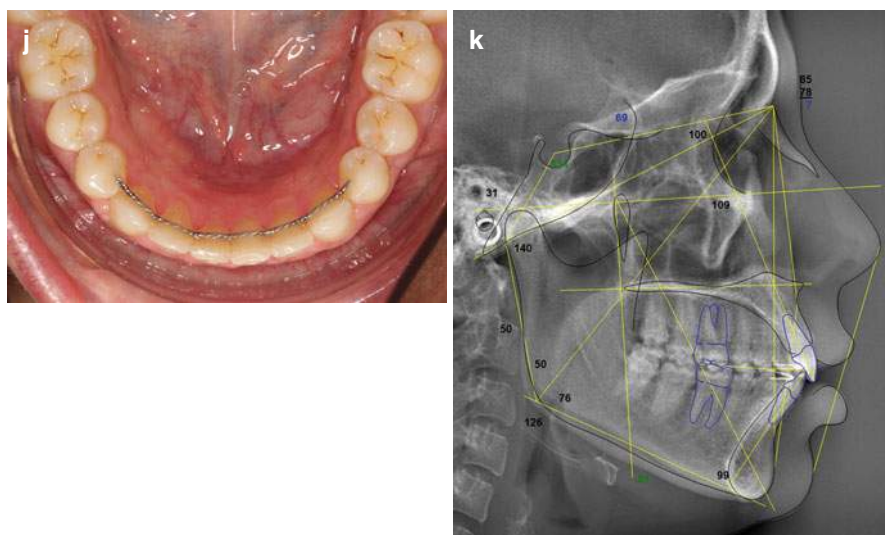


Fig. 11.15 (continued)

discrepancy (Fig. 11.16). Hays Nance analysis revealed 12 mm excess space in the maxillary and 10.5 mm excess space in the mandibular dental arches. No Bolton discrepancy was noted. Cephalometric analysis showed proclined incisors. Therefore, although the spacings could have been closed by retraction of the incisors with fixed orthodontic appliances, the stability of the orthodontic result was questionable. When the tooth-arch size discrepancy is severe, closing the spaces by retracting incisors may require excessive tooth movement which cannot be tolerated by the soft tissues. Particularly, when the size of the tongue is large (e.g. the presence of indentations on the tongue borders, see Chap. 3), the orthodontist should avoid moving teeth lingually into the tongue area, which may lead to unstable results. Therefore, this case was treated with an interdisciplinary approach, collecting diastemas mesially and generating an extra tooth space in every quadrant distal to the canines, placing dental implants and prosthetic rehabilitation.

11.4.4 Case 8: Congenital Tooth Agenesis and Bimaxillary Diastema; Closing the Spaces with Orthodontics

Cases with missing teeth either congenital or acquired may also present diastema. One of the most common situations is missing maxillary lateral incisors [13]. From an orthodontic perspective, there are two treatment alternatives: to close or to open the space for prosthetic rehabilitation. The decision whether to close or open the space depends largely on the age of the patient, the malocclusion, the size and form of the canines and tooth exposure while smiling.

This 21-year-old female patient's main concern was spacing between her upper teeth. The polydiastema was caused by congenitally missing upper left lateral incisor and right peg-shaped lateral incisor. In addition, she had persisted deciduous

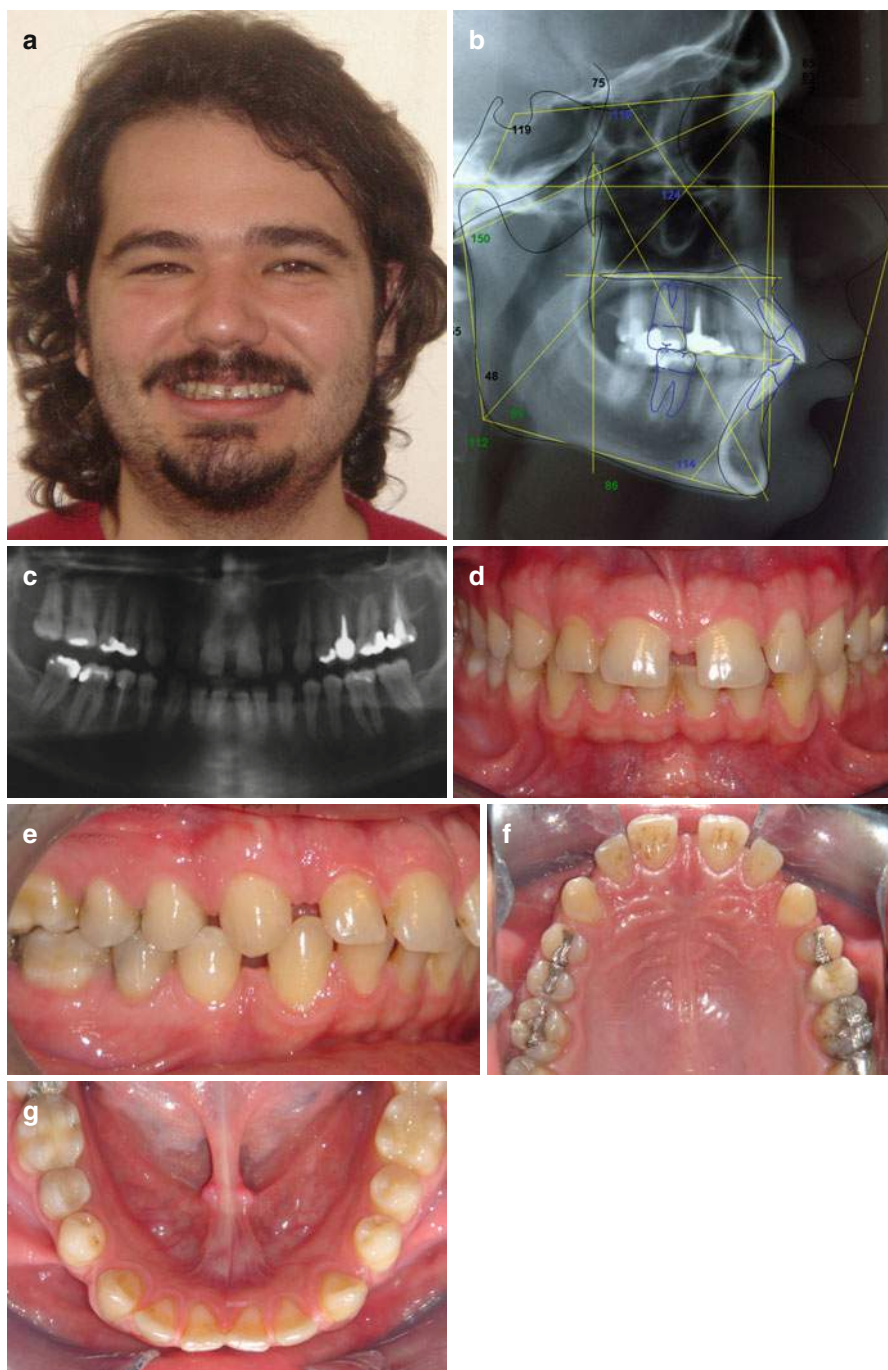

Fig. 11.16 (a–g) A male patient with severe bimaxillary generalised spacing due to tooth size-arch size discrepancy. (h–n) Interdisciplinary treatment comprised of generating spaces for a third premolar in every quadrant, placement of dental implants and prosthetic rehabilitation. Cephalometric tracing shows that maxillary and mandibular incisors were slightly upright. (o–q) Five years postretention photographs showing stable results (Restorations by Dr. Arzu Aykor)

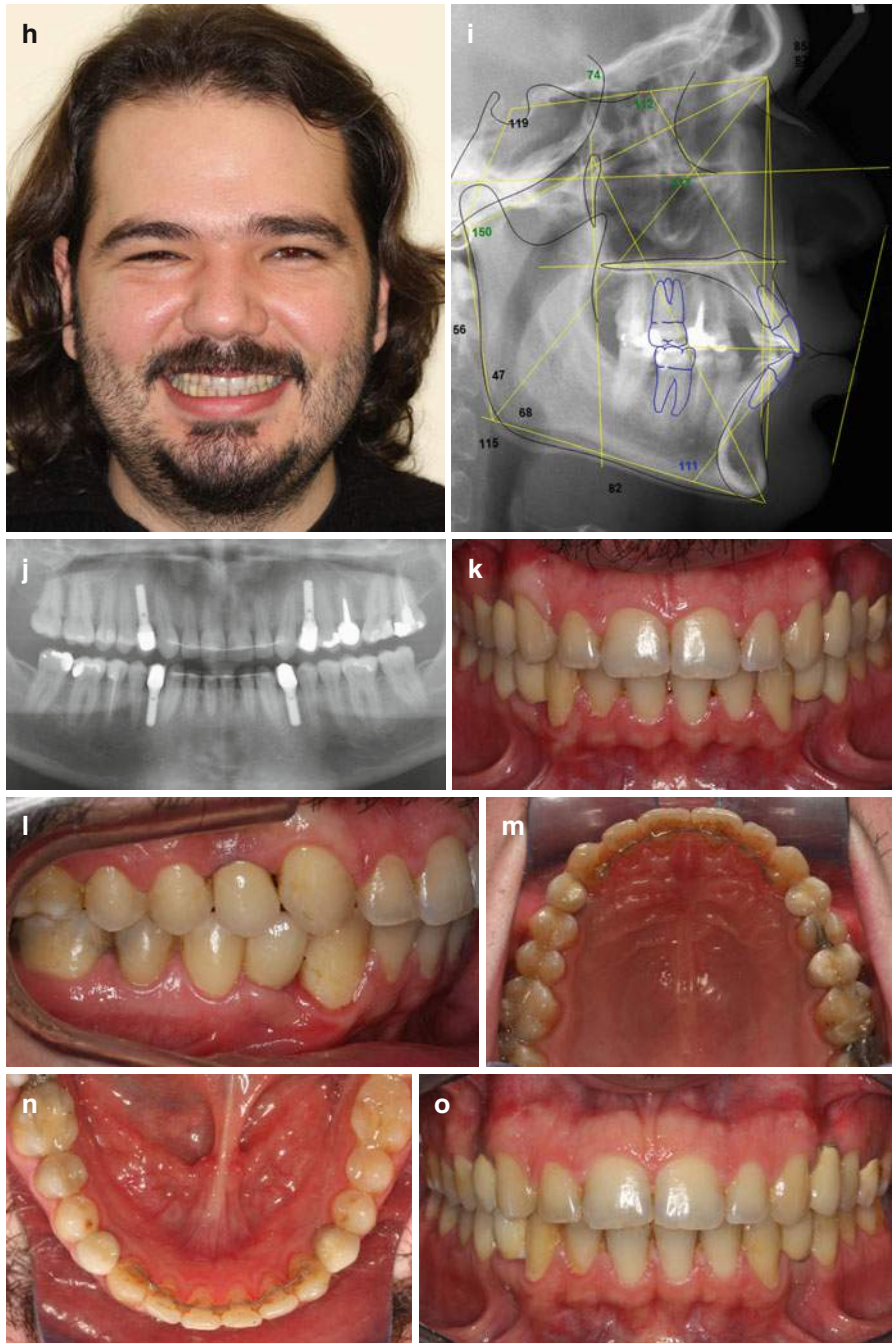


Fig. 11.16 (continued)

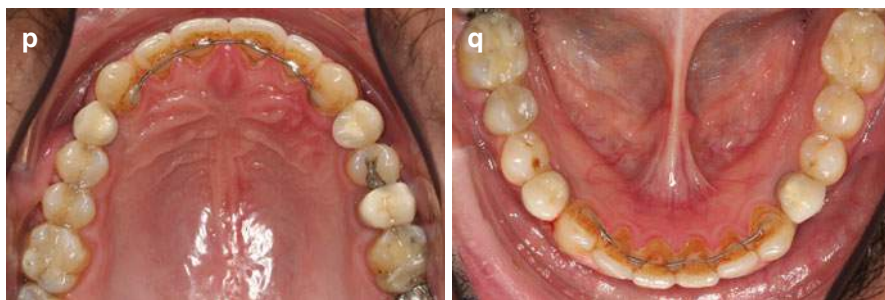

Fig. 11.16 (continued)

maxillary left and mandibular right canine, congenitally missing mandibular incisor and left second premolar (Fig. 11.17). Cephalometric evaluation revealed labially inclined incisors, Class II skeletal pattern and a straight facial profile.

Two different interdisciplinary treatment alternatives were proposed: (1) space opening for congenitally missing teeth with orthodontic treatment, prosthetic rehabilitation with implants and ceramic crowns and restorative treatment of the peg-shaped upper right lateral incisor and (2) closing the spaces caused by missing teeth with orthodontic treatment, canine substitution, restorative treatment of the canines and gingival surgery. The patient rejected the first treatment plan because she did not want to have implants at the end of the treatment. The second treatment option was chosen. In order to achieve symmetrical maxillary arch form, left peg-shaped lateral incisor was extracted. Maxillary canines and right mandibular canine were substituted for lateral incisors. All the spaces caused by tooth agenesis were closed with orthodontic treatment. Gingival levelling was achieved with gingivectomy, and canines and first premolars were reshaped with restorative treatment.

11.5 Orthodontic Management of Spacing in Periodontal Loss

Periodontal bone loss is considered as one of the aetiological factors of diastema. When the teeth lost their periodontal support due to periodontal disease, the stabilisation of the periodontal ligament is decreased leading to changes in the equilibrium between the teeth, soft tissues and forces generated at rest or function. Thus, pathological migrations may be observed after severe periodontal breakdown, which may cause diastema. Generally, these patients with no previous history of diastema in younger ages are complaining about the recently developed spacings. Orthodontics can help to bring the teeth together in alveolar bone, level the alveolar crest and eliminate the occlusal trauma (Fig. 11.18). The use of fixed retainers following orthodontic treatment also serves as splints in a periodontally compromised patient. The prerequisite to orthodontics in these cases is to control inflammation by periodontal therapy.

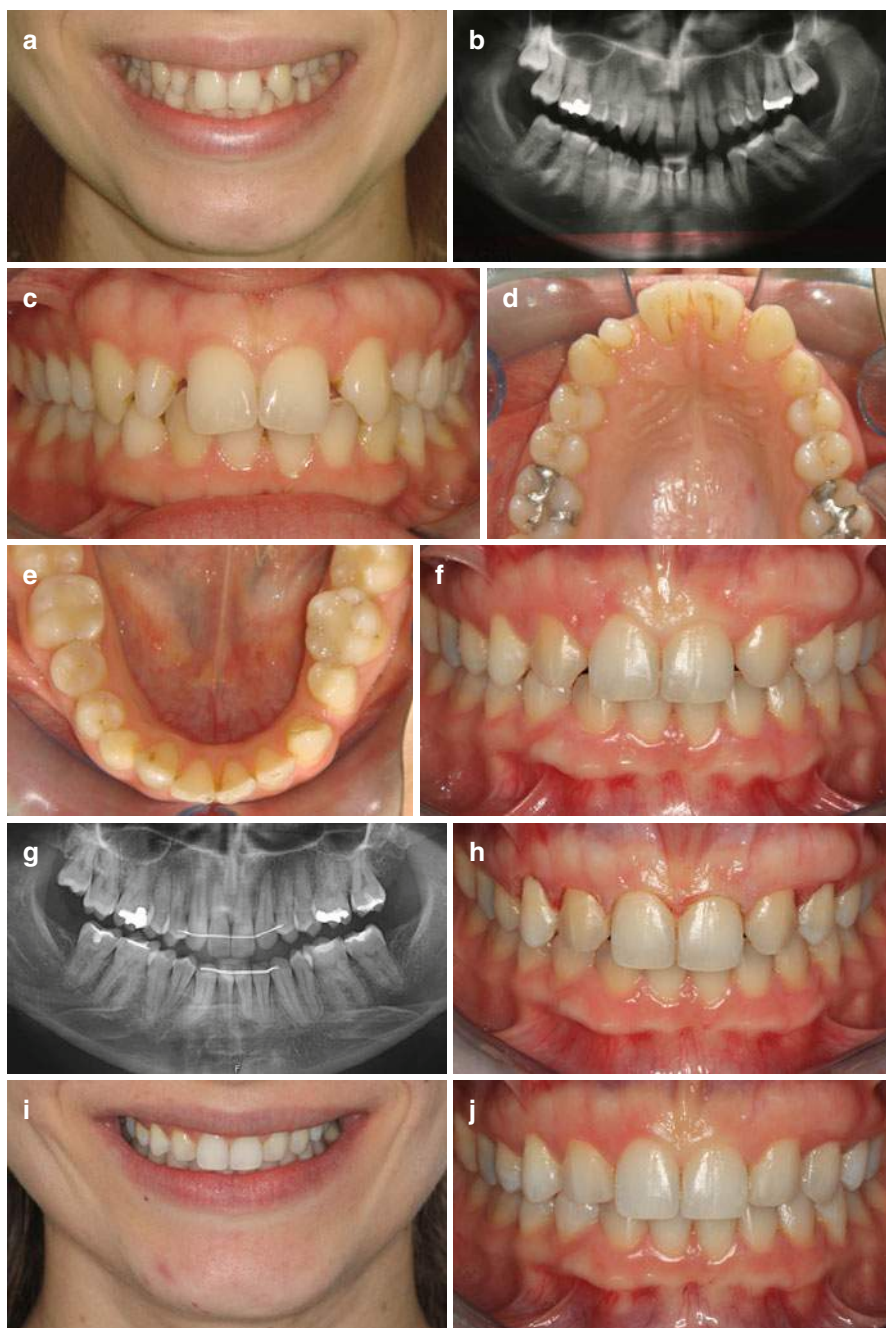

Fig. 11.17 (a–e) Extraoral, intraoral photographs and panoramic radiograph of a patient with maxillary and mandibular spacing caused by congenital tooth agenesis and size anomaly. (f, g) Intraoral and radiographic views after spaces were closed by orthodontic treatment. (h) Gingival levelling with gingivectomy. (i–j) Final extraoral and intraoral photographs after interdisciplinary treatment. Note maxillary canines and first premolars were reshaped with direct composite restorations (Restorations by Dr. Murat Ozarslan)

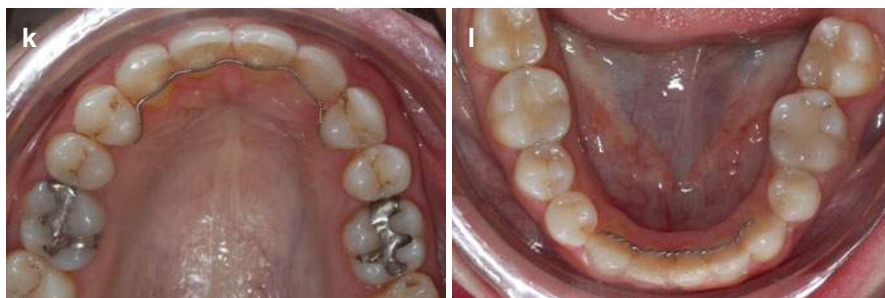

Fig. 11.17 (continued)

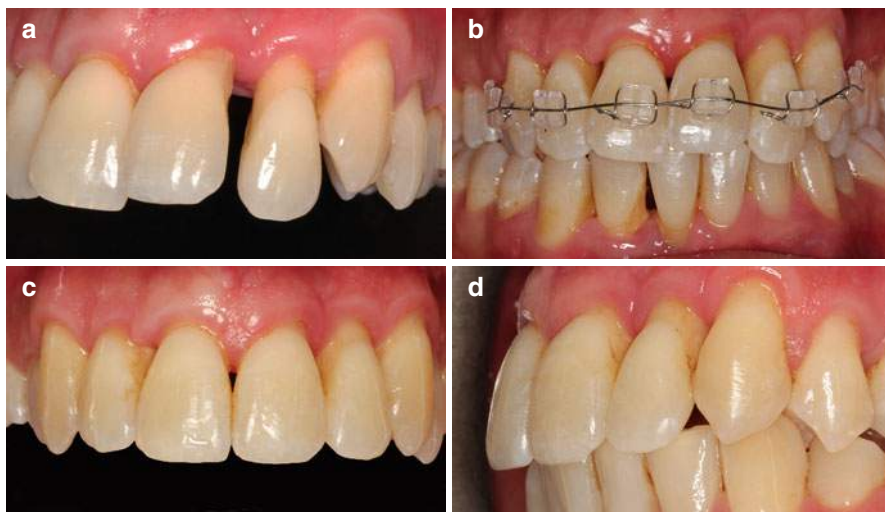


Fig. 11.18 (a) Extrusion and migration of the maxillary teeth and development of diastema due to periodontal disease. (b) Orthodontic treatment aiming to level the crestal bone and close the diastema in the maxillary anterior region. (c, d) Alignment of the teeth and closure of the spacing after orthodontic treatment

11.6 Timing of Frenectomy

An abnormal maxillary labial frenum has been strongly (but not absolutely) correlated to the presence of maxillary midline diastema [14]. Surgical removal of the maxillary labial frenum (frenectomy) is generally indicated to avoid recurrence of the midline diastema after orthodontic closure.

Early frenectomies without prior orthodontic treatment should be avoided because they may result in scar formation, which may tend to prevent physiologic mesial movement of the incisors [15]. Frenectomies should be performed in conjunction with orthodontic treatment if there is a remnant midline diastema after the

eruption of all anterior permanent teeth. However, the timing of frenectomy is controversial. The abnormal frenum is generally removed after orthodontic treatment because the scar tissue may impede the closure by tooth movement [16]. However, if the frenum is severely hypertrophic complicating orthodontic treatment, it can be removed just prior to closure [17].

Key Note

Early frenectomy is not recommended before the eruption of the permanent maxillary canines.

11.7 Relapse and Retention of Diastema

Relapse of diastema is a major problem. The common opinion on this particular dental challenge is that diastema is easy to treat but difficult to retain. In orthodontic textbooks, median diastemas and generalised spacing are considered among the situations necessitating lifelong retention especially in adults because the relapse potential of diastema after orthodontic treatment may be considerably high [18]. When it comes to the evidence, the results of the studies are controversial. Long-term stability studies on relapse of generalised spacing treated in childhood and adolescence revealed that the results are quite stable into adulthood likely due to progressive arch length and width constriction in postretention period [19, 20]. However, there are others reporting a high relapse of median diastema in approximately 50–60 % of the orthodontically treated patients [4, 21]. The reported amount of relapse is also diverse. Only minimal and partial relapse was found in most of the studies, whereas Edwards [14] showed 2.4–2.7 mm of midline space reopening in patients with an average initial diastema of 3.2 mm. Its recurrence has been correlated with abnormal frenum attachment, maxillary bony cleft, tooth size anomalies, improper axial inclination of the central incisors, persistent bad habits, post-treatment proclination of the maxillary incisors, increase in overjet, fremitus of the maxillary incisors and deepbite [4, 14, 16, 21–24]. The initial amount of diastema, familial tendency and additional spaces between the anterior teeth have been shown as predictors of relapse of maxillary median diastema [4, 21]. De Morais et al. [21] advised the lifetime wear of maxillary fixed retainer particularly in cases with large initial median diastema and muscle imbalance. Until orthodontists are provided with the results of randomised controlled studies proving good stability, it seems they tend to take every measure to reduce the probability of reopening of the spaces.

When planning retention protocol following orthodontic or interdisciplinary treatment of diastema, the causative factors, the original position and amount of the diastema and oral hygiene of the patient should be taken into consideration. As a general rule, the causes of the malocclusion such as bad habits or abnormal frenum attachment should be eliminated before the retention period, which is thought to have an influence on stable outcomes. However, sometimes it may not be possible to eliminate the cause in a case with periodontal loss and re-establish the

equilibrium because the stabilisation effect of the periodontal tissue is decreased. If the spacing is caused by periodontal loss, lifelong retention with a fixed lingual retainer is advised (Fig. 11.19a). When the causative factor is thought to be macroglossia, some authors suggest a rare operation (glossectomy or partial glossoplasty) to reduce the size of the tongue in order to ensure stability as an alternative to life-long fixed retention [25]. An additional advantage of glossoplasty was reported as the elimination of tongue thrust habit in low rest position even in adults due to the hypersensitivity of the tongue immediately after the operation, serving as a feedback to reposition the tongue [25].

Unfortunately, the elimination of the cause does not always guarantee stable results after diastema treatment. Therefore, general opinion is to set a permanent or semi-permanent retention protocol. Compliance-free fixed lingual multistranded wire retainers are very effective for permanent retention of the diastema [26]. In case of a median diastema, the wire extends on the lingual side of the two central incisors (Fig. 11.19b). If there is polydiastema, it may extend to the canines or premolars (Fig. 11.8f). A flexible wire (diameter of 0.0215 inch), which is out of occlusal contact, should be used to enable physiological tooth movement while keeping the spaces closed. The main disadvantage of using fixed retainers is the difficulty of maintaining oral hygiene and controlling plaque accumulation. A very strict oral hygiene protocol with frequent dental follow-ups can be advised.

In diastema cases, retention with removable appliances alone (Hawley retainers or clear appliances) is not the treatment of choice because of the jiggling effect on the teeth when the appliance is not worn. The back-and-forth closure of the diastema may be detrimental in the long-term [27]. Some clinicians prefer to use both removable and fixed retainers together as an extra precaution to prevent diastema relapse.

There are also some experimental approaches to ensure stability of closed spaces without the use of permanent retention, such as changing the root inclination to prevent relapse [12]. According to Mulligan [12], long-term stability of closed spacings depended on the control of the divergence of the incisal axis and vertical effects

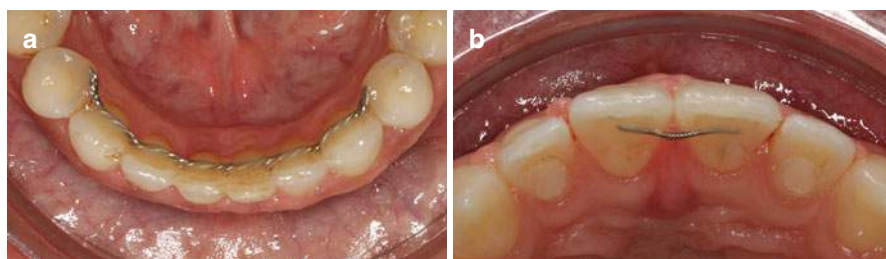

Fig. 11.19 (a) The use of bonded lingual retainer after orthodontic diastema closure in a case with periodontal loss. The fixed retainer was fabricated from 0.032 inch braided stainless steel wire. (b) A fixed retainer bonded to maxillary central incisors to prevent the recurrence of midline diastema

of occlusal forces. But this approach does not seem to be widely used among orthodontists.

When diastema is relapsed, what can be done? If there is minimal relapse, diastema can be closed with removable appliances (retraction of the incisors by activating the vestibular arch), clear aligners with or without set-up, segmental fixed appliances or restorations (if the tooth proportions allow). When there is a major relapse, the clinician should reconsider the causes and replan comprehensive treatment either orthodontic, restorative or interdisciplinary.

References

1. Taylor JE. Clinical observations relating to the normal and abnormal frenum labii superioris. *Am J Orthod Oral Surg.* 1939;25:255–9.
2. Gardiner JH. Midline spaces. *Dent Pract.* 1987;17:287–98.
3. Weyman J. The incidence of median diastema during the eruption of the permanent teeth. *Dent Pract.* 1987;17:276–98.
4. Shashua D, Artun J. Relapse after orthodontic correction of maxillary median diastema: a follow-up evaluation of consecutive cases. *Angle Orthod.* 1999;69:257–63.
5. Sheridan JJ, Armbruster P. Clear plastic appliances for retention and tooth movement. In: Graber TM, Vanarsdall Jr RL, Vig KWL, editors. *Orthodontics: current principles and techniques.* 4th ed. St. Louis: Elsevier Mosby; 2005. p. 1169.
6. Bishara SE. Development of dental occlusion. In: Bishara SE, editor. *Textbook of orthodontics.* Pennsylvania: W.B. Saunders Company; 2001. p. 56.
7. Proffit WR, Fields Jr HW, Sarver DM. *Contemporary orthodontics.* 4th ed. St. Louis: Mosby Elsevier; 2007. p. 145–8.
8. Germeç D, Taner TU. Lower lip sucking habit treated with a lip bumper appliance. *Angle Orthod.* 2005;75:1071–6.
9. Tozlu M, Germeç D. Ortodontide Myofonksiyonel Tedavi Seçenekleri. *7 Tepe Klinik.* 2008;2:34–42.
10. Smith SS, Buschang PH, Watanabe E. Interarch tooth size relationships of 3 populations: “does Bolton’s apply?”. *Am J Orthod Dentofacial Orthop.* 2000;117:169–74.
11. Kokich VG, Kokich VO. Interrelationship of orthodontics with periodontics and restorative dentistry. In: Nanda R, editor. *Biomechanics and esthetic strategies in clinical orthodontics.* St. Louis: Elsevier Saunders; 2005. p. 361.
12. Mulligan TF. Diastemas: is permanent retention really necessary? In: Nanda R, Kapila S, editors. *Current therapy in orthodontics.* 1st ed. St. Louis: Mosby Elsevier; 2010. p. 215–27.
13. Polder BJ, Van’t Hof MA, Van der Linden FP, Kuijpers-Jagtman AM. A meta-analysis of the prevalence of dental agenesis of permanent teeth. *Community Dent Oral Epidemiol.* 2004;32:217–26.
14. Edwards JG. The diastema, the frenum, the frenectomy: a clinical study. *Am J Orthod.* 1977;71:489–508.
15. Dewel BF. The normal and abnormal labial frenum: clinical differentiation. *J Am Dent Assoc.* 1946;33:318–29.
16. Bishara SE. Management of diastemas in orthodontics. *Am J Orthod.* 1972;61:55–63.
17. Meister Jr F, Van Swol RL, Rank DF. The maxillary anterior frenectomy. *J Wis Dent Assoc.* 1981;57:205–10.
18. Joondeph DR. Stability, retention and relapse. In: Graber TM, Vanarsdall Jr RL, Vig KWL, editors. *Orthodontics: current principles and techniques.* 5th ed. St. Louis: Elsevier Mosby; 2012. p. 1011.

19. Little RM, Reidel RA. Postretention evaluation of stability and relapse – mandibular arches with generalized spacing. *Am J Orthod Dentofacial Orthop.* 1989;95:37–41.
20. Jonsson T, Magnusson TE. Crowding and spacing in the dental arches: long-term development in treated and untreated subjects. *Am J Orthod Dentofacial Orthop.* 2010;138:384.e1–7.
21. de Morais JF, de Freitas MR, de Freitas KM, Janson G, Castello Branco N. Postretention stability after orthodontic closure of maxillary interincisor diastemas. *J Appl Oral Sci.* 2014;22:409–15.
22. Becker A. The median diastema: a review of its aetiology. *Israel J Dent Med.* 1977;26:21–7.
23. Sullivan TC, Turpin DL, Artun J. A postretention study of patients presenting with a maxillary median diastema. *Angle Orthod.* 1996;66:131–8.
24. Nanda R, Kapila S. *Current therapy in orthodontics.* 1st ed. St. Louis: Mosby Elsevier; 2010. p. 215–27.
25. Attia Y. Midline diastemas: closure and stability. *Angle Orthod.* 1993;63:209–12.
26. Zachrisson BU. Clinical experience with direct-bonded orthodontic retainers. *Am J Orthod.* 1977;71:440–8.
27. Proffit WR, Fields Jr HW, Sarver DM. *Contemporary orthodontics.* 4th ed. St. Louis: Mosby Elsevier; 2007. p. 626–8.

Treatment Options, Timing and Sequencing: Direct-Indirect Restorative Treatment

12

Ugur Erdemir, Taner Yucel, and Esra Yildiz

Abstract

Diastema closure with direct or indirect restorative procedures, esthetic considerations, smile design, and multidisciplinary comprehensive approach should be considered for a successful restorative treatment. Closure of diastema directly with resin-based composites in restorative approach can be simple and relatively low cost compared to indirect restorations particularly porcelain laminate veneers, and also it does not impede future orthodontic treatment owing to its reversible treatment. However, change of color, leakage, and mechanical and/or chemical degradation of the material by the time despite improvements in formulations are the major drawbacks of the resin composite restorations. Indirect restorations such as porcelain laminate veneers (PLVs) are the most common indications for diastema closure and offer clinicians as well as patients the most esthetically pleasant final outcome. PLVs require minimal invasive tooth preparation and allow clinician to optimal esthetics with that of perfect mimicking tooth structures, perfect anatomical contours, correct tooth proportions, and resistance to discoloration and surface degradation compared to resin composite materials.

When planning diastema closure, esthetic considerations, smile design, and multidisciplinary comprehensive approach should be considered for a successful restorative treatment. Achieving an esthetically pleasant and functional final outcome that is in good relationship with the temporomandibular joints, muscles, face, lips, gingival structures, teeth, and occlusion is an important factor for the multidisciplinary treatment options [1]. Diastema closure especially for the excessive spaces present

U. Erdemir, PhD, DDS (✉) • T. Yucel, PhD, DDS • E. Yildiz, PhD, DDS
Operative Dentistry, University of Istanbul Faculty of Dentistry, Istanbul, Turkey
e-mail: uerdemir@hotmail.com

challenging treatment procedure, and therefore, a comprehensive treatment planning along with the study models, photographs, occlusion analysis, soft and hard tissue, as well as facial analysis should be correctly and collaboratively planned. During the diastema closure, the clinician should always measure the tooth proportions and should create as proper tooth proportions as to ideal form for an esthetically pleasant and natural final outcome [2, 3]. Orthodontic treatment procedure alone can successfully resolve most of the spaced dentition problems except where the dentoalveolar and Bolton discrepancies are present [2, 4]. After an orthodontic intervention, closing of remaining anterior spacing resulting from Bolton discrepancy may also require a restorative treatment which involves direct or indirect restorative approach to reestablish mesiodistal widths of the teeth and optimize the final result (Fig. 12.1a, b) [5]. In this situation, orthodontic treatment can be used to correct distribution of maxillary anterior teeth on the arch before the restorative treatment procedure [2, 6]. Previous reports propose many treatment procedures for diastema closure such as directly with resin composites [3, 7–9] and indirectly with porcelain laminate veneers [2, 3, 10–12], crowns [2, 13, 14], and adhesive-type bridges [15, 16] where the absence of lateral incisors and all with and without orthodontic treatment [2, 17]. During the restorative stage of the significant tooth size discrepancy in the multidisciplinary approach, permanent teeth of the patient should be fully erupted in order to have good access to the restoration area for a successful restorative treatment [14]. In addition, during an active orthodontic intervention properly placed resin composite restorations may be advantageous in order to enable proportionate and ideal spacing for definitive restorations and may also allow clinician to necessary modification during the finalizing stage of the orthodontic treatment [14]. Irrespective of the treatment procedure that is chosen (direct or indirect) for diastema closure, the clinician as well as the patient should be aware of the possible concurrent change of speech along with the esthetic restorative treatment [18]. Therefore, clinicians should advise their patients on the possible change of speech after finishing of the restorative treatment [2]. If there is any disharmony related to gingival structures in diastema cases, then periodontal treatment procedure should also be included in the treatment plan, and accomplished before the initiation of restorative treatment procedures (please see Fig. 10.7). Management of the labial frenulum in the case of diastema is also another important parameter that should be carefully considered. Current consensus among the clinicians regarding the maxillary frenulum is that initially diastema is corrected by the orthodontic

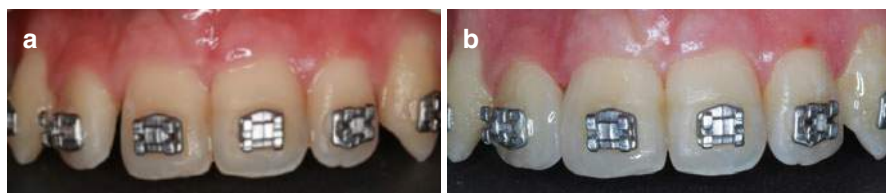


Fig. 12.1 (a) Orthodontically distributed dentition in a younger patient. (b) During orthodontic treatment, closing of remaining anterior spacing with direct resin composite buildup

treatment and then the frenulum must be surgically operated [19–21]. During the healing process of the soft tissue after surgical treatment, orthodontic appliances should also remain in the current place to form soft tissue in this new position and help retain the result [20]. If any disproportional tooth form is identified during clinical examination in an unworn dentition, the clinician should primarily perform crown lengthening to reach the ideal tooth proportions and then finalize the treatment, either direct or indirect restorative procedures. Diagnostic study models with wax setup or direct mock-ups can be useful tools to optimize final restoration at this stage (Fig. 12.2a, b). Generally, orthodontic treatment by itself closes most of the diastema cases where acceptable width/length tooth ratio is obtained and ideal proximal tooth contacts maintained [2, 14, 18]. In addition, significant overjet cases with spaced dentition can also be particularly treated by orthodontic treatment, and this will close the diastema along with the reduced overjet [2, 14]. If there is spaced dentition with no significant overjet, treatment of the case solely by orthodontic treatment without restorative treatment may cause over-retraction of the teeth and, hence, may lead to incisal wear in the anterior teeth [2]. Although orthodontic treatment provides pleasant final outcome in some of the diastema cases, major drawbacks of this treatment procedure are the time, relatively high cost compared to direct restorative treatment, relapse of the case where the proper stabilization was not provided, and most importantly increased dental caries and periodontal inflammation due to plaque accumulation around the brackets [2].

Direct restorative approach with resin-based composites can be simple and relatively low cost compared to indirect restorations particularly porcelain laminate veneers, and also it does not impede future orthodontic treatment owing to its reversible treatment [3]. In addition, this conservative approach allows clinician to minimal or no tooth preparation in a single appointment (Fig. 12.3a, b) with esthetically and functionally pleasant outcome [2]. Current resin composite materials have adequate physical and mechanical properties, provide esthetically natural appearance with that of teeth structure, and are durable owing to refinement in the size of the inorganic fillers with optimal polishing capability [2, 22] (Fig. 12.4). Innovations in the filler technology have also led to the use of nanosized particles in the material composition, and this allowed to improve color stability of the materials itself besides the physical and mechanical properties of the resin composites [2, 22]. On the other hand, one of the advantage of the resin composite materials is that the

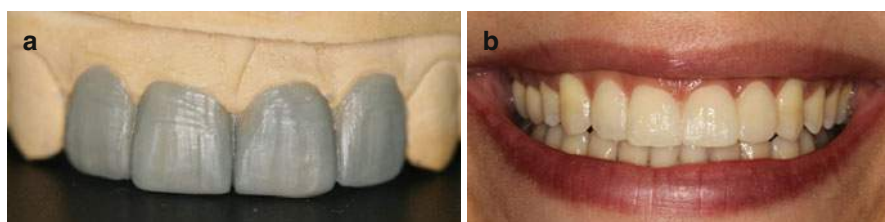


Fig. 12.2 (a) Diagnostic study models with wax setup or (b) direct mock-ups can be useful tools to optimize final restoration

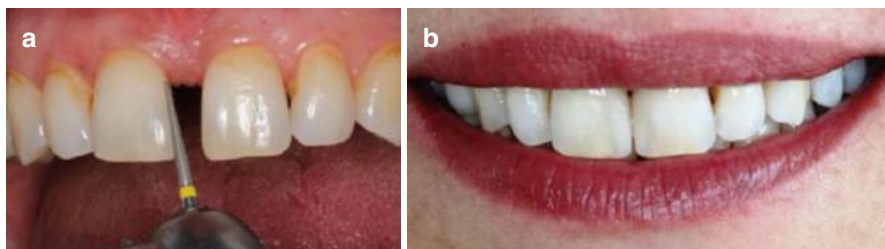

Fig. 12.3 (a) Minimal enamel preparation using fine diamond bur. (b) Final appearance of the case restored with direct resin composite in a single appointment



Fig. 12.4 Some examples of the current resin composite materials (Courtesy of Dr. Murat Tiryaki)

intraoral repair in a single visit without needing laboratory process and at a lower cost with a desirable repair outcome of the chipping, defects, and stains [2, 22]. Resin composite materials can be used in the direct stratification of the material (Fig. 12.5) or layered with a fabricated silicone index from the study models to assist in material buildup during diastema closure (Fig. 12.6a–d) [3]. The clinician should bear in mind that if an enlarged frenulum is present between maxillary central incisors, it should be operated before restorative treatment procedure, and closure of the diastema is postponed after tissue healing (Fig. 12.7). During the application of the resin composite material, the clinician should carefully isolate the working area to avoid any contamination. Additionally, before initiation of the restorative procedure, clinician should also clean the tooth surface to remove any

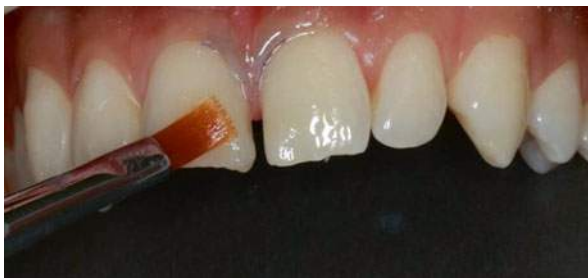

Fig. 12.5 Direct stratification of the resin composite material

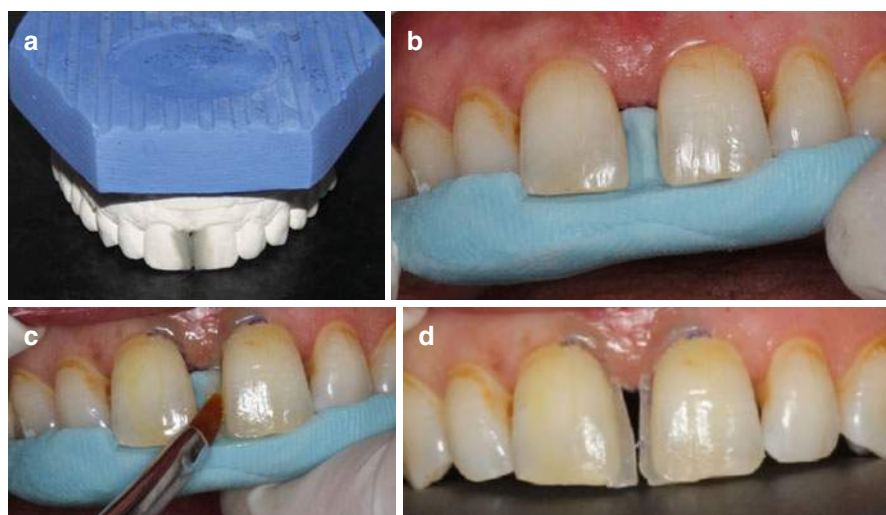


Fig. 12.6 Resin composite buildup using silicone index. (a) Laboratory prepared wax setup on the study model. (b) Fabricated silicone index from the study model and placing onto the teeth. (c) Resin composite buildup with the help of silicone index. (d) Prepared palatal contours of the restoration

plaque, stains, and debris remnants (Fig. 12.8a, b). If the patient has a significant spaced area more than 3 mm, the clinician should prefer indirect restoration such as porcelain laminate veneers to maintain ideal tooth proportion. In that situation, direct restorative procedure with resin composite may cause distally tilted tooth appearance and disproportionate tooth form with an unpleasant outcome. Both direct and indirect restorative treatment choice should be limited to patients with good oral hygiene and who pay attention to oral care [2]. Although direct resin composite buildup in the treatment of diastema can provide good treatment outcome in a single visit, the clinician must pay attention not to create overcountered and biologically excessive intrasulcular restorations [2, 23]. One of the major difficulties in diastema closure is the creation of anatomical contacts with rounded counters and anatomical gingival margin adaptation. The use of wedges in order to create

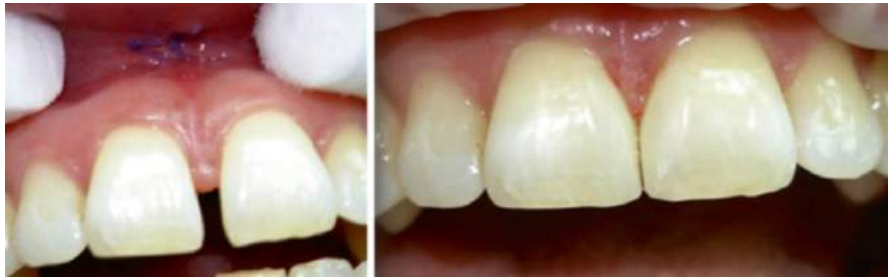

Fig. 12.7 Operated enlarged frenulum between maxillary central incisors and after tissue healing, diastema closure with direct resin composite

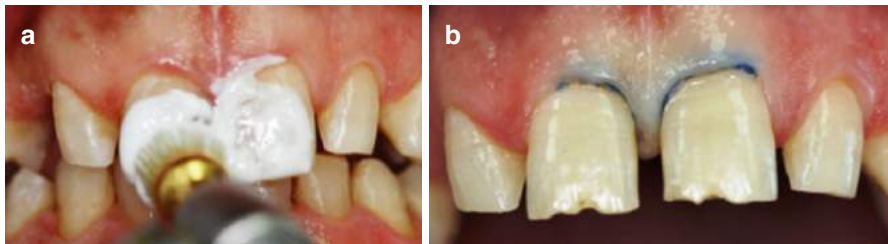


Fig. 12.8 (a) Cleaning of the tooth surface to remove stains and (b) isolation of the working area using cotton rolls, retraction cords, and if possible rubber dam to avoid any contamination is necessary before initiation of the restorative procedure

anatomical gingival adaptation may be useful in some cases, however, the use of wedge may also create undesired black triangles in the interproximal area. To overcome correctly countered and good intrasulcular restorations and limitations of the traditional clear matrix strips when closing diastema with direct resin composite, it has been proposed to use anatomic diastema closure matrix (Bioclear Matrix Systems, Tacoma, WA, USA) systems (Fig. 12.9) for intimate adaptation to the gingival margin and fully rounded counters of the restoration [24].

Despite improvement in the formulations of the resin composite materials, the major drawbacks are still change of color, leakage and mechanical and/or chemical degradation of the material and hence, requirement of possible multiple replacement process by time [2, 3, 14, 25]. Therefore, the patient should be aware of the possible replacement requirement of the restoration due to color change and surface texture alterations within a reasonable time [2, 6].

Indirect restorations such as porcelain laminate veneers (PLVs) are the most common indications for diastema closure and offer clinicians as well as patients the most esthetically pleasant final outcome [10]. Requirement of minimal invasive tooth preparation (Fig. 12.10) for PLVs allow clinicians to obtain optimal esthetics with that of perfect mimicking tooth structures, perfect anatomical contours and correct tooth proportions. The other advantage of the restoration is also maintaining resistance to discoloration and surface degradation in comparison to resin composite

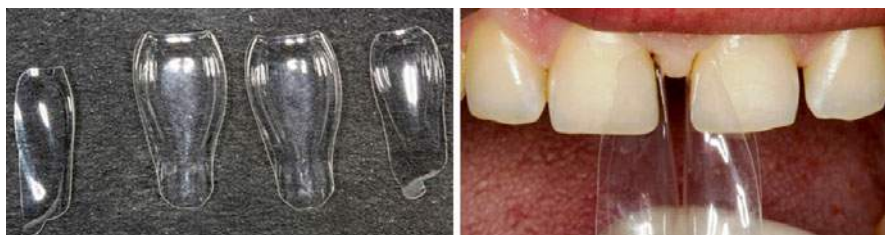

Fig. 12.9 Different types of Bioclear Matrix Systems and trying on the patient teeth (thanks to Dr. Özgür Baydemir for providing the matrix systems)

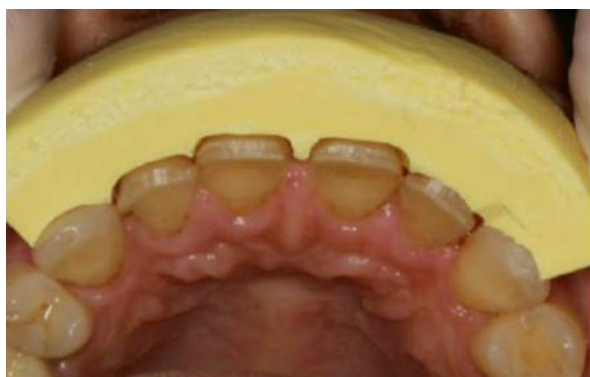

Fig. 12.10 Minimal invasively prepared tooth surface for porcelain laminate veneers. Note, using silicone index allows ultraconservative and homogeneity tooth preparation

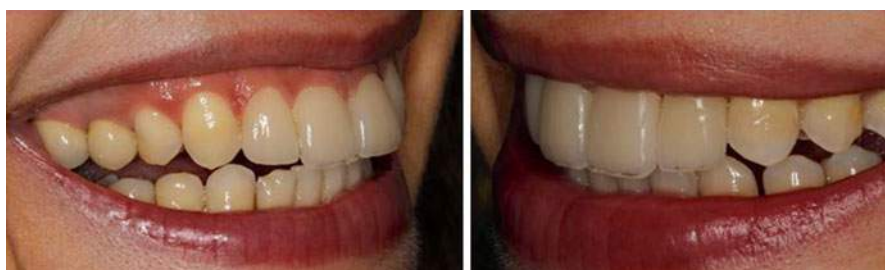

Fig. 12.11 PLVs are highly esthetic restorations with that of perfect mimicking tooth structures, perfect anatomical contours, and resistance to discoloration and surface degradation compared to resin composite materials

materials (Fig. 12.11). Glazed perfect smooth surface can decrease plaque accumulation on the restoration, and also it has been reported that it increase the gingival sulcular fluid and hence promotes periodontal health by decreasing periodontal inflammation [2, 26, 27]. Disadvantages of PLVs are that they are time consuming, require technique-sensitive laboratory process, and have relatively high cost

compared to resin composites [2, 17]. In addition, unlike resin composite restorations, PLVs can only be placed after the completion of orthodontic treatment procedure and must be placed after growth completion as well as when stable gingival margins are achieved [14]. During diastema closure with restorative procedures, clinician should pay attention to preserve or maintain ideal width/length ratio for a particular tooth [2, 10]. Careful multidisciplinary clinical evaluation and treatment plan will bring success, and diagnostic wax setup, composite mock-up, and digital smile design software (Fig. 12.12) can be helpful to the clinician in achieving an esthetically and functionally pleasant final restoration [1–3, 10, 14]. Preparation design and equal placement of restorative material on each side of the gap is very important during closing diastema. In general, small space between 0.5 and 1 mm does not require any restorative treatment, and patients feel happy to live with that spacing (Fig. 12.13). If any treatment is planned on a maxillary diastema that is 1 mm or less and the teeth is in ideal proportions, approximately 0.5 mm of restorative material adding to each tooth (Fig. 12.14) does not negatively affect the esthetic appearance and proportions [2]. Rounding the disto-incisal corners of the teeth and vertical lines for creation of illusion on the facial surface of the restoration can be used for a narrower tooth appearance [2, 10, 28]. In some situation where the teeth exhibit short clinical crowns, it should be necessary to perform crown lengthening procedures either apically by periodontal surgery, incisally with the addition of a restorative material, or combination of both procedures for maintaining ideal tooth proportion during diastema closure (Fig. 12.15) [2, 10]. At this point, the clinician should need to evaluate incisal display of the anterior teeth and if the incisal display

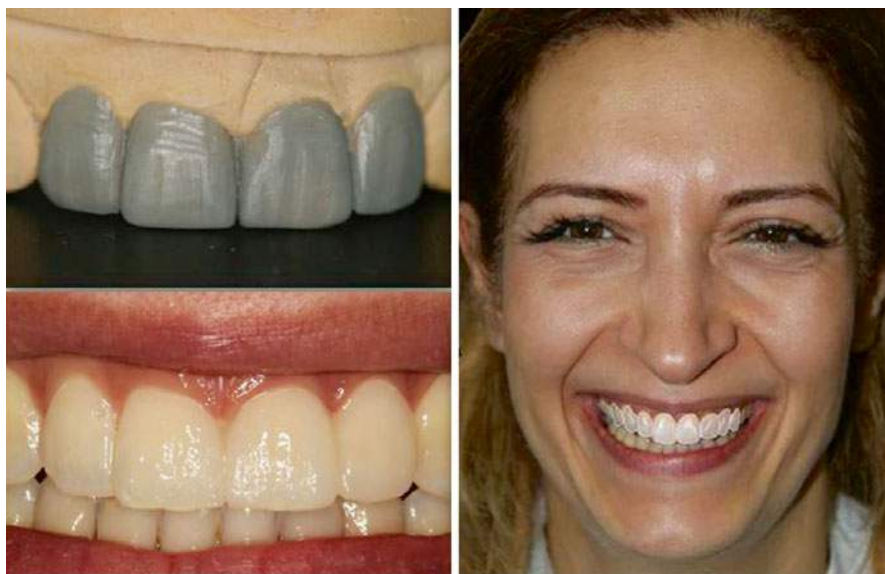

Fig. 12.12 Diagnostic wax setup, composite mock-ups, and digital smile design software are helpful tools to achieve esthetically and functionally pleasant final restoration

Fig. 12.13 Patient representing approximately 0.5-mm space between maxillary central incisors who feels happy to live with that spacing

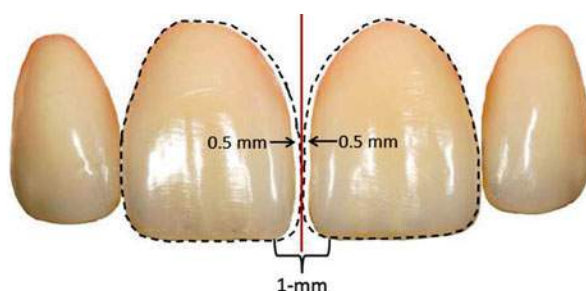
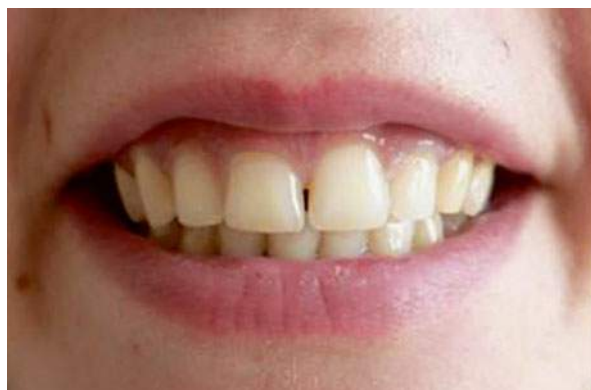

Fig. 12.14 Schematic illustration if the maxillary diastema is 1 mm or less and the teeth is in ideal proportions, approximately 0.5 mm of restorative material adding to each tooth does not negatively affect the esthetic appearance and proportions

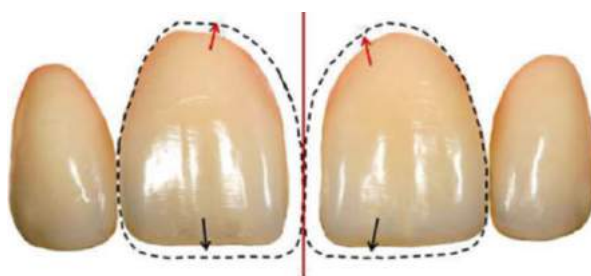


Fig. 12.15 Schematic illustration where the teeth exhibit short clinical crowns. In this situation, to maintain ideal tooth proportion, crown lengthening procedures either apically by periodontal surgery (*red arrow*) or incisally with addition of a restorative material (*black arrow*), or both combination procedures are necessary before diastema closure

is normal and the incisal edge in correct position but with teeth exhibiting short clinical crown; then periodontal crown lengthening procedure should be done (Fig. 12.16) before initiation of restorative approach to maintain proper tooth proportions [2, 10]. Without periodontal crown lengthening procedure, teeth will be appeared as squared

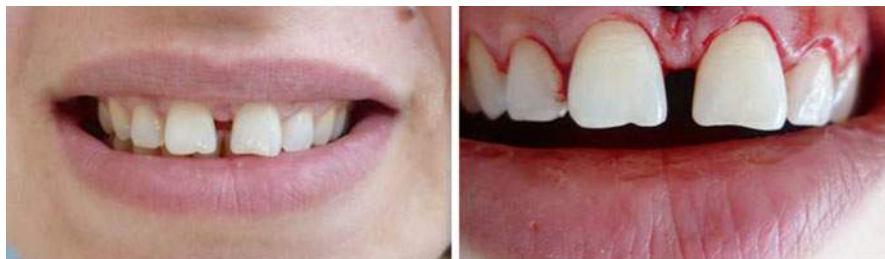

Fig. 12.16 Patient representing normal incisal display with short clinical crown. Periodontal crown lengthening procedures before initiation of restorative approach to maintain proper tooth proportions

form with disproportional short clinical crowns and will be perceived as unaesthetic [2]. If gingival level is correct and symmetric but length of the crown is short, then clinician can lengthen the teeth by using PLVs to achieve ideal width/length ratios (Fig. 12.17) during closing of the space [10]. If there is more than 2-mm gap between two maxillary central incisors, closing this space with one or two laminate veneers will create esthetically unpleasant appearance and disproportionate tooth form (Fig. 12.18) [10]. In this situation, clinician should need to restore maxillary anterior 4 or more teeth for the closure of diastema (Fig. 12.19) and maintain esthetic and proportionate tooth form as well as proper mesialization of the teeth towards the dental midline [2, 10]. When anterior teeth exhibits ideal tooth proportions on the arch with a significant midline diastema, distal surface of the maxillary central and lateral should be altered to half and $\frac{1}{4}$ of the amount of the diastema space, respectively, to maintain proper tooth proportions and mesialization of the teeth towards dental midline (Fig. 12.19) and right position on the arch [2, 10]. The best way for the mesialization and proper positioning of the anterior teeth relative to dental midline is the use of silicone index that was prepared in accordance with the diagnostic wax setup prior to tooth preparation [10]. During space management for both median and multi-diastema cases, clinician should send the diagnostic study models and impressions of the mock-ups to the laboratory technician for the creation of proportionate, functional, and esthetically pleasant final restorations [10].

Arrangement of the correct gingival zenith point location is also another important criterion during diastema closure. If zenith point location did not change at the same time with the teeth towards dental midline with respect to their pretreatment point, then teeth will appear as mesially tilted [2]. In order to avoid mesial tilted tooth appearance, location of the zenith points can be shifted by periodontal procedure or by gingival tissue recontouring using provisional restorations (Fig. 12.20) [2, 28]. During tooth preparation for diastema closure, veneer preparation should also be modified for the natural triangular formation of papillae [2, 10]. In general, papilla formation in diastema cases is round and flat with a blunt edge rather than triangular shape, and hence, formation of natural triangular-shaped papillae is important in these cases. To ensure the formation of triangularly shaped papillae in diastema cases, veneer preparation should be subgingivally performed on the gap

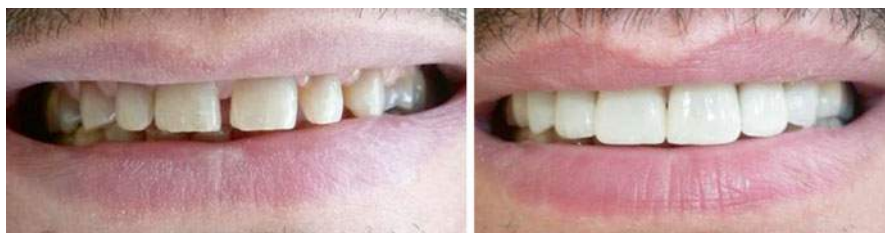

Fig. 12.17 Patient representing polydiastema on maxillary anterior teeth with correct gingival level and short clinical crown. Incisal crown lengthening and diastema closure with PLVs for achieving ideal proportions

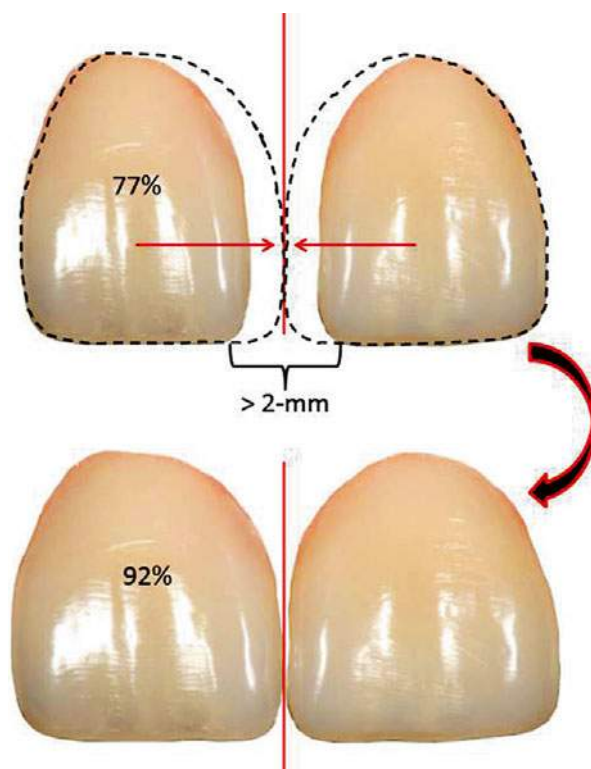


Fig. 12.18 Schematic illustration when there is more than 2-mm gap between two maxillary central incisors. Closing this space with one or two laminate veneers will create unaesthetic appearance and disproportionate tooth form

side for both teeth (Fig. 12.21a), and fabricated laminate veneers should be prepared slightly overcountered with a gentle push on the papillae (Fig. 12.21b) for its natural triangular reshaping by the time [2, 10]. Interproximal contact area should also be modified for veneer preparation in which preparations should be extended palatally (Fig. 12.22) rather than the wing-type preparation design without creation of

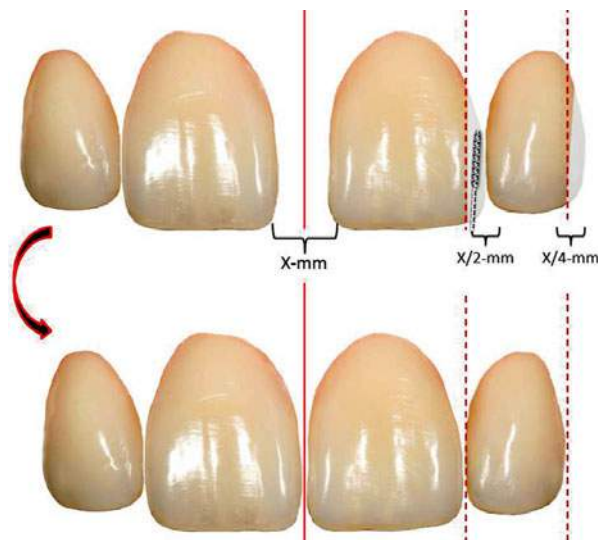


Fig. 12.19 Schematic illustration of significant diastema between maxillary centrals. In this situation, 4 or more teeth to be included in restorative treatment procedure and distal surface of the maxillary central and lateral should be altered to $\frac{1}{2}$ and $\frac{1}{4}$ amount of the diastema space, respectively, to maintain proper tooth proportions and mesialization of the teeth towards dental midline

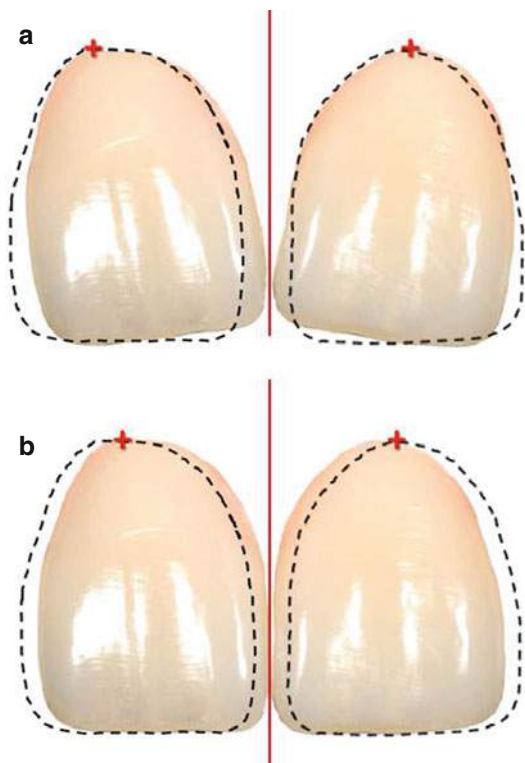


Fig. 12.20 Schematic illustration (a) if zenith point location did not change at the same time with the teeth towards dental midline with respect to their pretreatment point, then teeth will appear as mesially tilted. (b) In this situation, location of the zenith points can be relocated by periodontal procedures or using provisional restorations in order to avoid mesial tilted tooth appearance

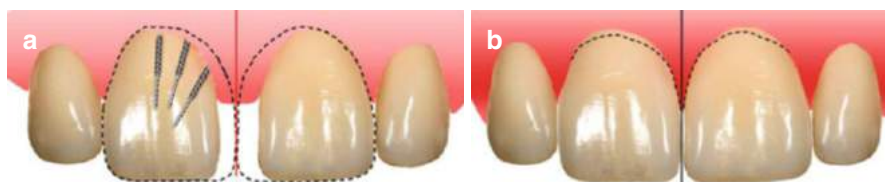


Fig. 12.21 Schematic illustration of tooth preparation for diastema closure to the formation of natural triangular-shaped papillae. (a) Veneer preparation should be subgingivally performed on the gap side for both teeth, and (b) fabricated laminate veneers should be prepared slightly overcountered with a gentle push on the papillae for the formation of natural triangular shape by the time

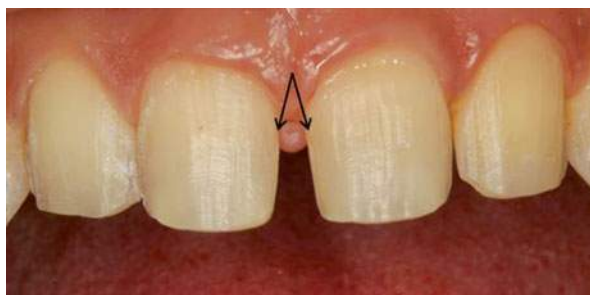

Fig. 12.22 Interproximal contact area should be extended palatally in diastema cases, and this will allow laboratory technician to create a naturally and esthetically pleasant veneers with a certain thickness on the proximal area and also to mask the dark shadow of the oral cavity on this area

any undercuts [2, 10]. Palatally extended preparation design would allow laboratory technician to create a naturally and esthetically pleasant clinical crown with a certain thickness on the proximal area and also to mask the dark shadow of the oral cavity on this area. [2, 10]

In the case of spaced dentition due to congenitally missing or peg-shaped lateral incisor, the clinician can close the gap with minimal invasion by adhesive-type bridges, crowns, or implants [2, 13–16]. It is important to restore in an ideal proportion for peg-shaped lateral incisor primarily and then to close remaining space with orthodontic approach [14]. Single-tooth implants where the missing lateral is present is also another treatment procedure which is invasive in nature that can be apply after gaining appropriate space on the arch with orthodontic intervention [29, 30].

The specific main goal of the abovementioned treatment options in diastema cases is to create excellent functional stability, esthetically and naturally pleasant final outcome, as well as harmonious tooth form with gingiva, lips, and face with a multi-disciplinary treatment procedure. Using contemporary materials, treatment, and smile design procedures, with an appropriate treatment plan and sequencing will bring success by enhancing the optimal outcome for each case.

References

1. Davis NC. Smile design. *Dent Clin N Am.* 2007;51(2):299–318.
2. Oquendo A, Brea L, David S. Diastema: correction of excessive spaces in the esthetic zone. *Dent Clin N Am.* 2011;55(2):265–8.
3. Chu CH, Zhang CF, Jin LJ. Treating a maxillary midline diastema in adult patients: a general dentist's perspective. *J Am Dent Assoc.* 2011;142(11):1258–64.
4. Huang WJ, Creath CJ. The midline diastema: a review of its etiology and treatment. *Pediatr Dent.* 1995;17(3):171–9.
5. Wise RJ, Nevins M. Anterior tooth site analysis (Bolton Index): how to determine anterior diastema closure. *Int J Periodontics Restorative Dent.* 1988;8(6):8–23.
6. Furuse AY, Franco EJ, Mondelli J. Esthetic and functional restoration for an anterior open occlusal relationship with multiple diastemata: a multidisciplinary approach. *J Prosthet Dent.* 2008;99(2):91–4.
7. Sundfeldt RH, Machado LS, de Oliveira FG, Santos EA, Lugato IC, Sundfeldt Neto D. Conservative reconstruction of the smile by orthodontic, bleaching, and restorative procedures. *Eur J Dent.* 2012;6(1):105–9.
8. Hwang SK, Ha JH, Jin MU, Kim SK, Kim YK. Diastema closure using direct bonding restorations combined with orthodontic treatment: a case report. *Restor Dent Endod.* 2012;37(3):165–9.
9. Willhite C. Diastema closure with freehand composite: controlling emergence contour. *Quintessence Int.* 2005;36(2):138–40.
10. Gurel G. The science and art of porcelain laminate veneers. Carol Stream: Quintessence Publishing Co Ltd., Ergolding, Germany; 2003. p. 369–90.
11. Ittipuriphat I, Leevailoj C. Anterior space management: interdisciplinary concepts. *J Esthet Restor Dent.* 2013;25(1):16–30.
12. Nazarian A. Closing the gap with minimal preparation veneers. *Dent Today.* 2006;25(12):70–1.
13. Lyssova V, Estafan D, Cunningham RP. A multidisciplinary esthetic approach to single-tooth replacement and diastema closure. *Gen Dent.* 2008;56(3):282–5.
14. Waldman AB. Smile design for the adolescent patient – interdisciplinary management of anterior tooth size discrepancies. *J Calif Dent Assoc.* 2008;36(5):365–72.
15. Kinzer GA, Kokich Jr VO. Managing congenitally missing lateral incisors. Part II: tooth-supported restorations. *J Esthet Restor Dent.* 2005;17(2):76–84.
16. Willhite C, Bellerino M, Eubank J. Treatment of congenitally missing lateral incisors with resin-bonded fixed partial dentures. *Quintessence Dent Technol.* 2002;25:63–72.
17. Beasley WK, Maskeroni AJ, Moon MG, Keating GV, Maxwell AW. The orthodontic and restorative treatment of a large diastema: a case report. *Gen Dent.* 2004;52(1):37–41.
18. Furuse AY, Herkrath FJ, Franco EJ, Benetti AR, Mondelli J. Multidisciplinary management of anterior diastemata: clinical procedures. *Pract Proced Aesthet Dent.* 2007;19(3):185–91.
19. Edwards JG. Soft-tissue surgery to alleviate orthodontic relapse. *Dent Clin N Am.* 1993;37(2):205–25.
20. Miller Jr PD. The frenectomy combined with a laterally positioned pedicle graft. Functional and esthetic considerations. *J Periodontol.* 1985;56(2):102–6.
21. Gkantidis N, Kolokitha OE, Topouzelis N. Management of maxillary midline diastema with emphasis on etiology. *J Clin Pediatr Dent.* 2008;32(4):265–72.
22. Ferracane JL. Resin composite – state of the art. *Dent Mater.* 2011;27(1):29–38.
23. De Araujo Jr EM, Fortkamp S, Baratieri LN. Closure of diastema and gingival recontouring using direct adhesive restorations: a case report. *J Esthet Restor Dent.* 2009;21(4):229–40.
24. Clark D. The bioclear matrix and peg lateral treatment. *Inside Dent.* 2011;7(5):112–6.
25. Ardu S, Braut V, Uhac I, Benbachir N, Feilzer AJ, Krejci I. Influence of mechanical and chemical degradation on surface gloss of resin composite materials. *Am J Dent.* 2009;22(5):264–8.

26. Gurel G. The science and art of porcelain laminate veneers. Carol Stream: Quintessence Publishing Co. Ltd., Ergolding, Germany; 2003. p. 231–332.
27. Kourkouta S, Walsh TT, Davis LG. The effect of porcelain laminate veneers on gingival health and bacterial plaque characteristics. *J Clin Periodontol.* 1994;21(9):638–40.
28. Gurel G, Chu S, Kim J. Restorative space management. In: *Aesthetic restorative dentistry principles and practice.* Mahwah: Montage Media; 2008. p. 405–25.
29. Richardson G, Russell KA. Congenitally missing maxillary lateral incisors and orthodontic treatment considerations for the single-tooth implant. *J Can Dent Assoc.* 2001;67(1):25–8.
30. Kinzer GA, Kokich Jr VO. Managing congenitally missing lateral incisors. Part III: single-tooth implants. *J Esthet Restor Dent.* 2005;17(4):202–10.

Taner Yucel, Esra Yildiz, and Ugur Erdemir

Abstract

Recent development and improvements in dental technology have made it possible to restore teeth as same as natural, biomimetic, and functional by creating a strong bond between tooth structures with minimal invasive or no tooth preparation by preserving the healthy tooth. Innovations in the resin composites' material formulation have led to the use of new monomers and fine inorganic fillers in the material composition, and these improvements have allowed reduced polymerization shrinkage, high mechanical and physical properties, and high polishability and also mimic nearly as the same natural tooth structures. Moreover, advances in ceramic technology have also led to major development in these systems typically reinforced materials that withstand occlusal forces and translucency that mimic natural tooth structures in the esthetic zone.

The closure of diastema in the restorative treatment procedures is often successfully accomplished with resin composite materials and porcelain laminate veneers [1–6]. Emerging technologies, improvements in the resin composite formulations, and adhesive materials have made it possible to restore teeth same as natural, biomimetic, and functional by creating a strong bond between tooth structures with minimal invasive or no tooth preparation by preserving the healthy tooth [7]. Significant development in the material formulation in recent years has led to the development of new monomers, fine filler size for resin composite materials with reduced polymerization shrinkage, high mechanical and physical properties, and high polishability and also mimics nearly the same as the natural tooth structures [8–10]. Due to improvements in the formulation and filler technology, resin composites can now be

T. Yucel, PhD, DDS (✉) • E. Yildiz, PhD, DDS • U. Erdemir, PhD, DDS
Operative Dentistry, University of Istanbul Faculty of Dentistry, Istanbul, Turkey
e-mail: t_yucel@superonline.com

considered both esthetic and functionally good material either in the anterior or posterior region of the mouth. When closing diastema or any anterior restoration, the clinician should mimic the dentin and enamel structures for creating esthetically pleasant and natural-looking restorations. Stratification technique (Fig. 13.1a) with a suitable composite having good handling, sculpting and viscosity characteristics are perfect for the manipulation and creation of a natural-looking final restoration (Fig. 13.1b) [11–13]. In addition to this, enhanced polishing capacity and optical properties are also essential. Resin composite materials have dramatically evolved since its inception [14], and recent technologies have made major improvements especially in the filler technology of these materials [12, 13]. As improvement in filler size and morphology, resin matrix of the composite materials decreased, and this allowed proper polymerization, manipulation, and reduced volumetric shrinkage to a degree of 0.9–1.5 % for creation esthetically pleasant restorations [12, 13, 15]. Nowadays, most resin composite manufacturers use nanotechnology to produce nanosized filler-containing resin composite materials for the improvement of the mechanical and physical properties of these materials [14]. Since the size of filler particles are reduced, overall filler level is increased in the resin matrix, and hence, increased filler level with the reduced amount of resin matrix allowed significantly reduced volumetric shrinkage and improvement in the optical, mechanical and physical characteristics of the materials [8, 14, 16]. The increase of mechanical properties of the material can also affect the hardness, compressive/flexural strength, coefficient thermal expansion, water sorption, and wear resistance of the material [14]. Due to increased fine filler particles by weight and distribution in

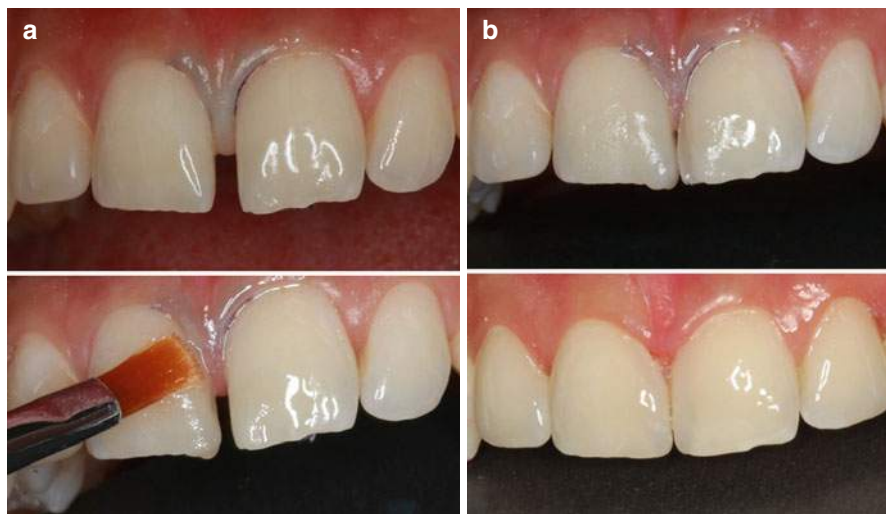

Fig. 13.1 When closing the diastema, (a) the use of stratification technique and (b) suitable composite materials with the handling, sculpting, and viscosity characteristics are important for the creation of a natural-looking final restorations

nanocomposites, these materials have also allowed perfect continuity and natural interface between the tooth structures and resin composite [14]. Today, a variety of resin composite material with different characteristics is available on the market (Fig. 13.2), and selection of the material should be based on the specific cases and area [12, 13, 17]. Microfill composites can represent good polishability and color stability and can be used in the anterior region for their high esthetic characteristics, but due to lower fracture resistance, they should not be used in the incisal region [7, 13, 17]. Reinforced microfill resin composites may be a good choice to use in this region due to increased fracture resistance for the creation of an esthetically pleasant and functional restoration [7, 13]. Hybrid-type composites especially the nanohybrids that are the “state-of-the-art” in this category can be a restorative material option in the anterior region owing to improved color stability, polishability, fracture, and wear resistance [9, 12]. Although they represent high polishability characteristics, microfill resin composites still exhibit higher polish and long-term gloss compared to nanohybrids [13]. In a recently published meta-analysis report in which clinical effectiveness of direct anterior restorations were evaluated, it has been stated that hybrid-type composites can be used in class III and IV restorations, and microfill composites demonstrated more shortcomings (i.e., fractures, impaired esthetics) [18].

Optical properties of resin composite materials are also crucial in order to mimic natural tooth structure. Novel resin composite materials can demonstrate these optical properties and in most of the resin composite sets, color characterized composite materials (i.e., opaque, amber, bluish) are available to create natural-looking restorations mimicking the characteristics of the tooth (Fig. 13.3).

The creation of a natural apparent restoration that is nearly similar to that of the real tooth, the clinician should consider to use stratification technique which mimics the dentin, enamel color, as well as incisal characterization (Fig. 13.4) [7, 19]. Selecting an appropriate shade for direct anterior restoration is another important factor, and sometimes it can be difficult [12, 13]. Regarding the shade selection for

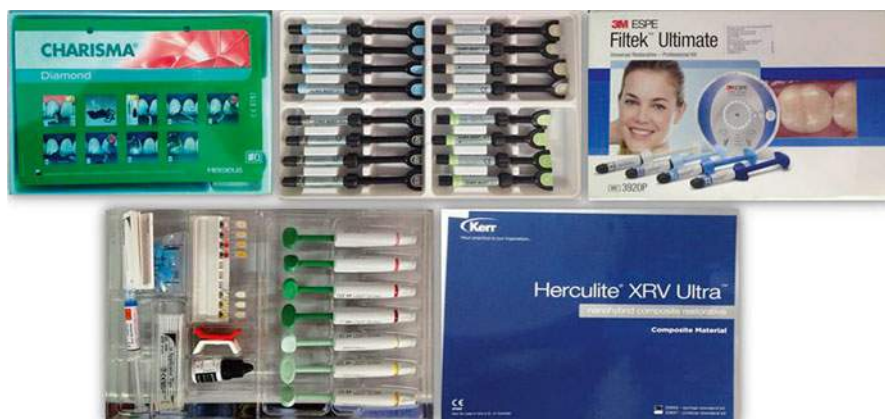
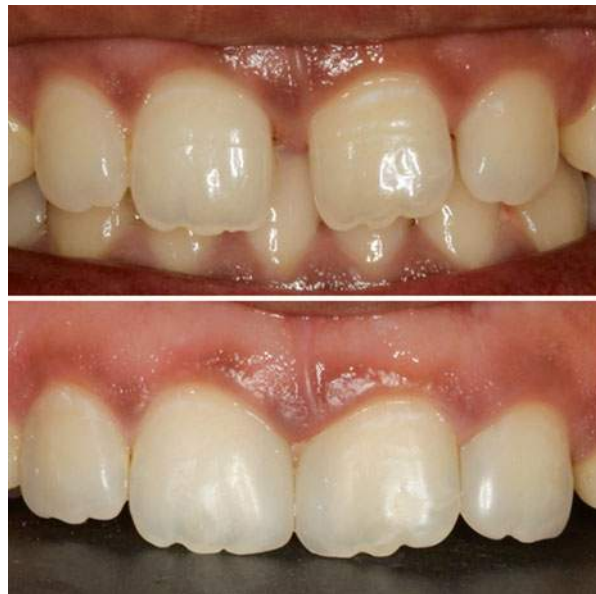
Fig. 13.2 Example of the some of the resin composite material available on the market

Fig. 13.3 Example of the characterization composite materials (i.e., opaque, amber, bluish) which can be found in resin composite sets



Fig. 13.4 Creation of a natural appearance restoration using stratification technique to mimic the dentin, enamel color, as well as incisal characterization



creation restoration that is similar in color with the tooth, generally manufacturers provide color guides with the composite kit (Fig. 13.5) or the clinician can use traditional Vita shade scale (Fig. 13.6). However, the use of manufacturers' color guide or Vita shade scale sometimes results in restorations that are not the same in color with that of the natural tooth structure. Moreover, it has been reported that Vita shade guide did not show true correlation with the resin composite material [12, 13].

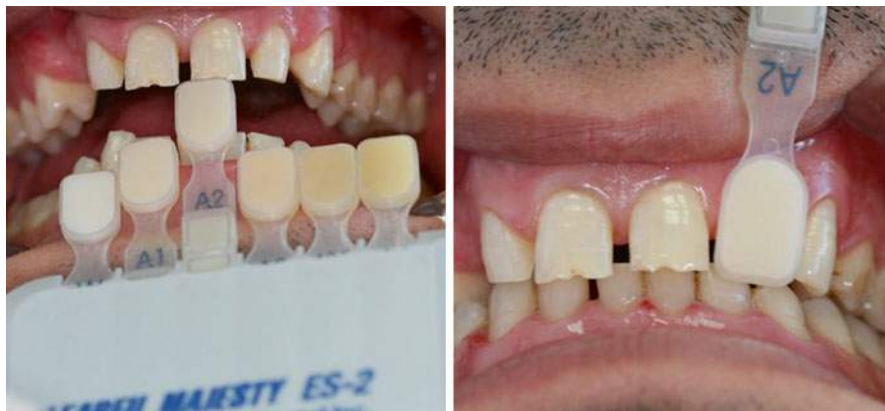
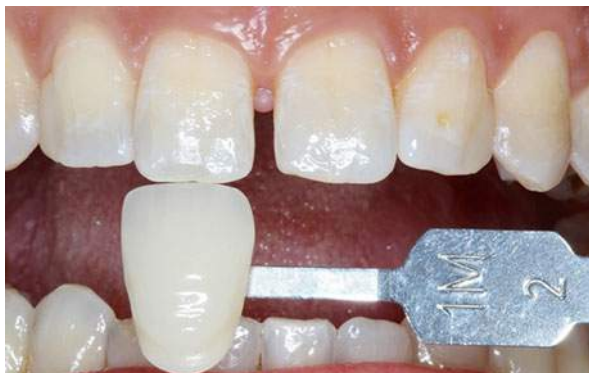
Fig. 13.5 Selecting an appropriate shade for direct anterior restoration is another important factor, and generally manufacturers provide shade guides with the composite kit

Fig. 13.6 The use of Vita shade scale can also use for selecting appropriate color for anterior restoration



To overcome this problem, clinicians can construct custom shade guide by using composite material itself (Fig. 13.7), especially those who use different composite materials in their clinic [7, 12, 13].

Key Note

When deciding to use resin composite material for an anterior restoration, clinicians can construct custom shade guide using composite material for selecting an appropriate color.

Nanosized composite materials have led to increased filler loading and reduced resin matrix which allowed improvement of the physical and mechanical properties of the material with enhanced esthetic characteristics and reduced polymerization

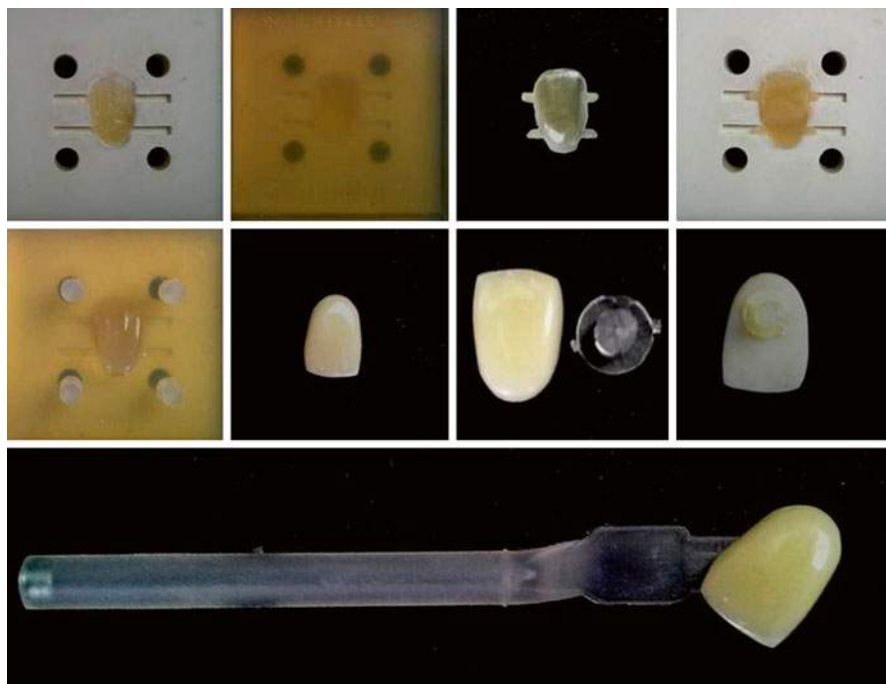
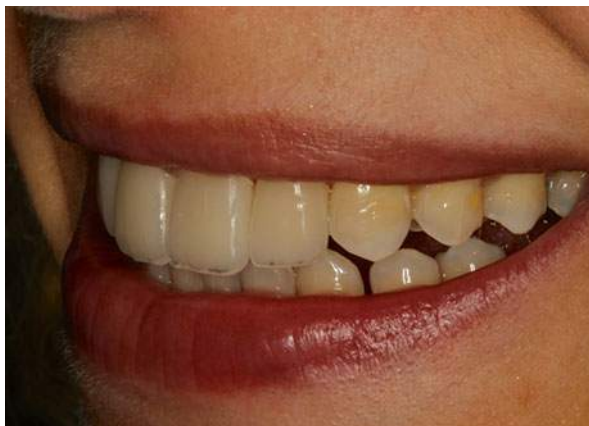

Fig. 13.7 Construction of custom shade guide using composite material itself may be helpful for appropriate color selection

shrinkage [8]. Although, there have been continuing improvement in the resin composites, the use of polychromatic stratification technique [14] is still necessary for the creation of esthetically pleasant final restoration especially in the anterior region.

Technological improvements have also increased the exponential usage of ceramic materials both in the anterior and posterior region due to enhanced mechanical and esthetic properties of materials compared to early systems. From an esthetic perspective view, all these ceramic systems exhibit similar natural tooth characteristics such as reflecting optical capacity of the enamel and dentin with indistinguishable esthetic appearance from the adjacent tooth (Fig. 13.8) [20]. Advances in ceramic technology have led to the major development in these systems typically reinforcing the materials to withstand the occlusal forces and maintain translucency needed to mimic natural tooth structures in the esthetic zone [21]. Therefore, in recent years, manufacturers have developed reinforced ceramic systems that combine the strength and esthetic characteristics for usage, both in the anterior and posterior region [21]. In general, dental ceramic systems can be divided into three categories which encompass silica-based, alumina-based, and zirconia-based systems [20], whereas for fabrication of porcelain laminate veneers, silica-based systems must be used. The use of porcelain laminate veneers (PLVs) in the case of diastema closure is one of the excellent indirect material of choice due to minimal invasive preparation design, similar esthetic quality with the natural tooth, biocompatibility, strength, and longevity of the

Fig. 13.8 Example of PLV restorations that exhibit similar natural tooth characteristics with indistinguishable esthetic appearance from the adjacent tooth



material [21, 22]. Currently, a variety of ceramic materials are available for fabrication of PLVs including feldspathic porcelain, Empress systems pressed or CAD, lithium disilicate-reinforced IPS e.max Press (Fig. 13.9a), and IPS e.max CAD (Fig. 13.9b) [22, 23] (Ivoclar-Vivadent, Schaan, Liechtenstein) with the advantages and disadvantages of each systems [21].

Silica-based feldspathic porcelains were the first types of materials used for the fabrication of PLVs in mimicking natural tooth structures due to high esthetic characteristics, and today, they are still in use to fabricate PLVs [20, 21]. When using this type of porcelain for the fabrication of PLV, either refractory die or the platinum foil technique must be used [20, 21] to support the porcelain during firing, grinding, as well as cementation due to reduced strength of the material [24]. Although feldspathic porcelain is still in use today for the fabrication of PLVs, the major drawback is the reduced flexural strength which may lead to the development of chipping or fracture [20, 24]. After an adhesive cementation to the underlying enamel surface, the material is strengthened by gaining support from the tooth structure [20, 24].

Pressed ceramic systems can also be used for the fabrication of PLVs. The first pressed porcelain system is launched on the market by Ivoclar-Vivadent in 1990 [20, 21, 25]. This material is basically a feldspathic porcelain with the addition of crystal phase (leucite) into the composition to form leucite-reinforced glass ceramic [20, 21]. The main reason for the addition of the leucite crystals into the material composition was to prevent or reduce the creation of microporosities during the sintering and improvement of the strength [20]. Fabrication of PLVs using this pre-sintered ingot materials can be accomplished by lost-wax technique or computer-aided design/computer-aided manufacturing (CAD/CAM) process [20, 21]. Although these materials exhibit excellent esthetic characteristics with the relatively improved mechanical strength rather than feldspathic porcelains, they have still reduced mechanical strength compared to the contemporary ceramic systems, and hence, they should not be used under stress-bearing areas [20].




Fig. 13.9 Examples of the lithium disilicate-reinforced ceramics. (a) IPS e.max Press, (b) IPS e.max CAD (Courtesy of Coskun Kasapoglu, Ivoclar-Vivadent, Turkey)

The newest version of Empress System with improved mechanical properties compared to Empress 1 is launched onto the dental market in 1998 with the name of IPS-Empress 2 (lithium disilicate-reinforced glass ceramic system) [20]. The fabrication process of veneers with this system is the same as Empress 1 which can be processed by lost-wax technique or CAD/CAM process [20, 22]. CAD/CAM block of this material is in bluish/light purple color (Fig. 13.10) due to intermediate oxidation phase with a weaker strength, and when sintered in an oven with appropriate heating procedure, it can achieve real mechanical strength and desired color [22, 26, 27]. When the clinician decided to use IPS e.max systems for PLVs in a case, the laboratory technician can fabricate veneers in two options, monolithic or bilayer [22]. In monolithic fabrication of veneers by using IPS e.max, solid IPS e.max is used [22] with relatively poor esthetic characteristics. In the fabrication of bilayer restoration, lithium disilicate IPS e.max is used as a core, and then on top of the core, a compatible layering porcelain with a high esthetic characteristics is added (Fig. 13.11) [22]. Lithium disilicate porcelain materials can be etched with porcelain etch (Fig. 13.12) the same as the feldspathic or leucite-reinforced porcelains to create microstructures on the surface for a shorter etching time (20 s) [28] compared to feldspathic porcelain (60 s) [22].

Cementations of PLVs are another challenging procedure in clinical applications. After tooth surface (Fig. 13.13a, b) and inner surface of the PLVs (Figs. 13.12 and 13.14a–c) are correctly prepared, the PLVs can be a cemented tooth surface. In general, light-cured luting materials are preferred for the cementing of the PLVs rather than dual-cured cement systems due to their longer working time, superior color stability, and easy to remove excess material (Fig. 13.15) [29]. Thickness and opacity of the PLV can also affect the light-curing capacity of the luting material, and hence, if the clinician prepared more than 0.7-mm thickness of PLV or used opaque ceramic for fabrication, then it should be preferred a dual-cured luting system for cementing of the PLVs in such cases [29]. If there would be no need for color change in the restoration, the clinician can use a clear or transparent luting

Fig. 13.10 Pre-sintered CAD/CAM block of IPS e.max is in bluish/light purple color. When sintered in an oven with appropriate heating procedure, it can achieve real mechanical strength and desired color

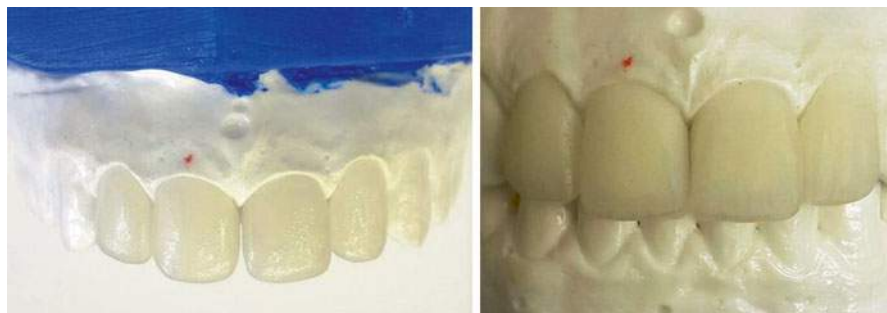
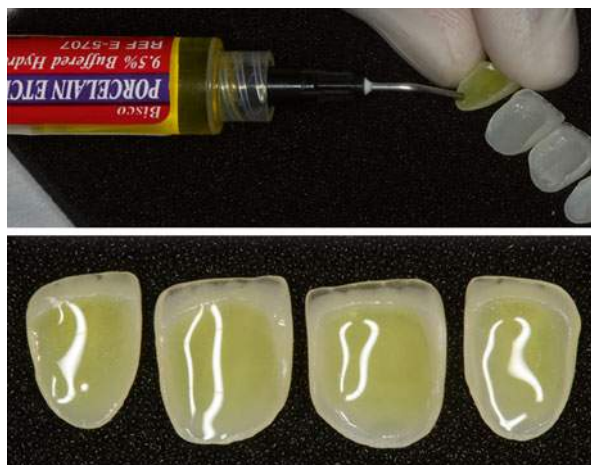
Fig. 13.11 Fabrication of PLV with IPS e.max using bilayer fabrication technique. IPS e.max is used as a core, and then on top of the core, a compatible layering porcelain with a high esthetic characteristics is added

Fig. 13.12 Etching inner surface of the PLVs with 9.5 % hydrofluoric acid (Porcelain Etchant, Bisco Inc., Schaumburg, IL, USA) for 20 s



material for cementation [29]. If there would be a need for color change, then the clinician should use the try-in pastes prior to cementation for determination of the desired color (Fig. 13.16).

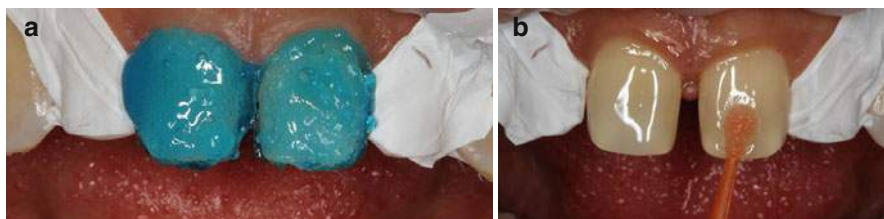


Fig. 13.13 Tooth surface preparation for cementation of PLVs. (a) 37 % phosphoric acid application to the tooth surface. (b) Application of an adhesive bonding material to the tooth surface. Note the use of Teflon bands can be helpful for protecting adjacent tooth from acid etching

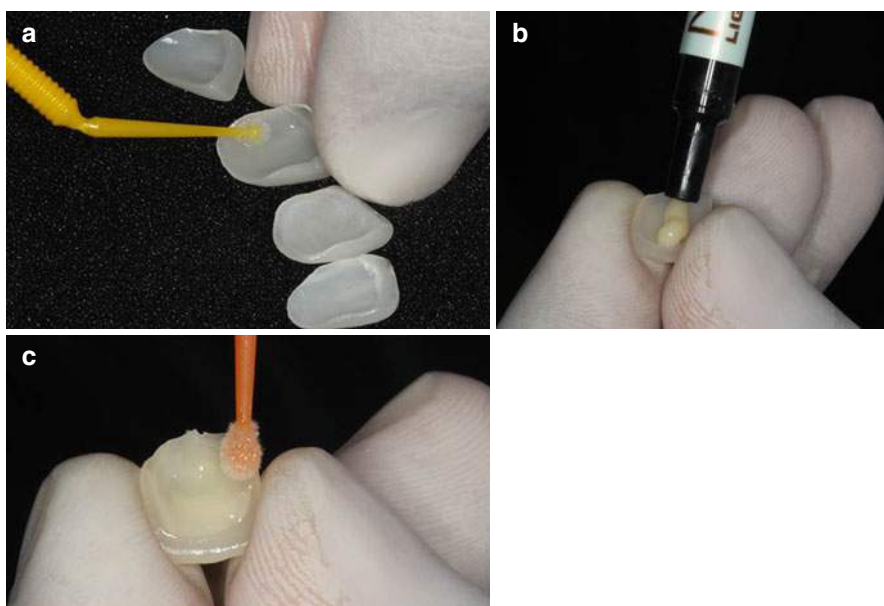
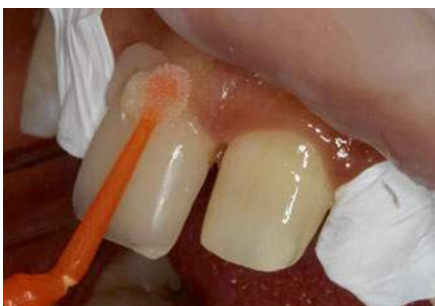

Fig. 13.14 Preparation of internal surface of the PLVs. (a) Application of silane-coupling agent after hydrofluoric acid application. (b) Application of the light-curing cement material into the internal surface of the PLV. (c) Spreading of the light-curing cement with a brush into the internal surface of the PLV

Fig. 13.15 Light-curing cement materials allow clinician longer working time and easy removing excess material



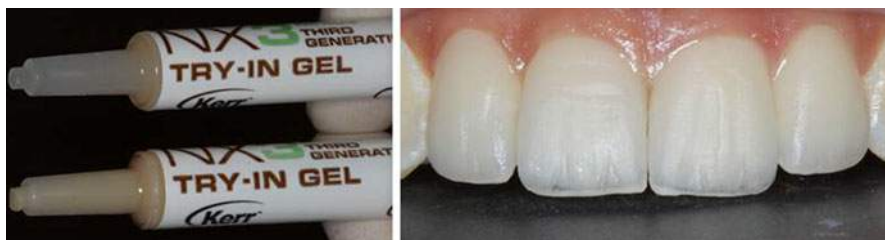

Fig. 13.16 The use try-in pastes prior to cementation can be helpful for the determination of desired color in the restoration. Note, a clear try-in paste was used on tooth number 1-1 and a yellow-colored try-in paste was used on tooth number 2-1

Esthetic opinion, skill, and experience of the clinician are crucial factors in the selection of porcelain material and pleasant outcome of the restoration. In the clinical situation, the mentioned porcelain materials can exhibit high esthetic and mechanical strength when they applied tooth structures properly. Esthetic performance and skill of the laboratory technician is also of paramount importance for the fabrication of a pleasant and natural appearance PLVs.

References

1. Oquendo A, Brea L, David S. Diastema: correction of excessive spaces in the esthetic zone. *Dent Clin N Am*. 2011;55(2):265-8.
2. Hwang SK, Ha JH, Jin MU, Kim SK, Kim YK. Diastema closure using direct bonding restorations combined with orthodontic treatment: a case report. *Restor Dent Endod*. 2012;37(3):165-9.
3. Willhite C. Diastema closure with freehand composite: controlling emergence contour. *Quintessence Int*. 2005;36(2):138-40.
4. Gurel G. The science and art of porcelain laminate veneers. Carol Stream: Quintessence Publishing Co. Ltd., Ergolding, Germany; 2003. p. 369-90.
5. Ittipuriphat I, Leevailoj C. Anterior space management: interdisciplinary concepts. *J Esthet Restor Dent*. 2013;25(1):16-30.
6. Nazarian A. Closing the gap with minimal preparation veneers. *Dent Today*. 2006;25(12):70-1.
7. Devoto W, Saracinelli M, Manauta J. Composite in everyday practice: how to choose the right material and simplify application techniques in the anterior teeth. *Eur J Esthet Dent*. 2010;5(1):102-24.
8. Chen MH. Update on dental nanocomposites. *J Dent Res*. 2010;89(6):549-60.
9. Ferracane JL. Resin composite – state of the art. *Dent Mater*. 2011;27(1):29-38.
10. Ergücü Z, Türkün LS. Surface roughness of novel resin composites polished with one-step systems. *Oper Dent*. 2007;32(2):185-92.
11. Magne P, Holz J. Stratification of composite restorations: systematic and durable replication of natural aesthetics. *Pract Periodontics Aesthet Dent*. 1996;8(1):61-8.
12. Fahl Jr N. A polychromatic composite layering approach for solving a complex Class IV/direct veneer/diastema combination: Part II. *Pract Proced Aesthet Dent*. 2007;19(1):17-22.
13. Fahl Jr N. A solution for everyday direct restorative challenges. *J Cosmetic Dent*. 2010;26(3):56-68.
14. Terry DA. Direct applications of a nanocomposite resin system: part 1 – the evolution of contemporary composite materials. *Pract Proced Aesthet Dent*. 2004;16(6):417-22.

15. Burke FJ, Palin WM, James A, Mackenzie L, Sands P. The current status of materials for posterior composite restorations: the advent of low shrink. *Dent Update*. 2009;36(7):401–9.
16. Mitra SB, Wu D, Holmes BN. An application of nanotechnology in advanced dental materials. *J Am Dent Assoc*. 2003;134(10):1382–90.
17. Mackenzie L, Parmar D, Shortall AC, Burke FJ. Direct anterior composites: a practical guide. *Dent Update*. 2013;40(4):297–308.
18. Heintze SD, Rousson V, Hickel R. Clinical effectiveness of direct anterior restorations – a meta-analysis. *Dent Mater*. 2015;31(5):481–95.
19. Devoto W, Pansecchi D. Composite restorations in the anterior region: clinical and aesthetic performances. *Pract Proced Aesthet Dent*. 2007;19(8):465–70.
20. Ahmad I. Protocols for predictable aesthetic dental restorations. Oxford, UK: Blackwell Munksgaard, Blackwell Publishing Company; 2006. p. 55–76.
21. Gurel G. The science and art of porcelain laminate veneers. Carol Steam: Quintessence Publishing Co. Ltd., Ergolding, Germany; 2003. p. 19–58.
22. Schwartzman A, Zweig AE. Improved communication with the laboratory for the fabrication of labial veneers. *J Calif Dent Assoc*. 2015;43(4):203–8.
23. Bagis B, Turgut S. Optical properties of current ceramics systems for laminate veneers. *J Dent*. 2013;41 Suppl 3:e24–30.
24. Radz GM. Minimum thickness anterior porcelain restorations. *Dent Clin N Am*. 2011;55(2):353–70.
25. Dong JK, Luthy H, Wohlwend A, Schärer P. Heat-pressed ceramics: technology and strength. *Int J Prosthodont*. 1992;5(1):9–16.
26. Fasbinder DJ. Chairside CAD/CAM: an overview of restorative material options. *Compend Contin Educ Dent*. 2012;33(1):50–8.
27. Fasbinder DJ. Materials for chairside CAD/CAM restorations. *Compend Contin Educ Dent*. 2010;31(9):702–9.
28. Erdemir U, Sancakli HS, Sancakli E, Eren MM, Ozel S, Yucel T, Yildiz E. Shear bond strength of a new self-adhering flowable composite resin for lithium disilicate-reinforced CAD/CAM ceramic material. *J Adv Prosthodont*. 2014;6(6):434–43.
29. Gurel G. The science and art of porcelain laminate veneers. Carol Steam: Quintessence Publishing Co Ltd., Ergolding, Germany; 2003. p. 231–332.

Esra Yildiz, Taner Yucel, Ugur Erdemir, Korkmaz Sayinsu, Derya Germec Cakan, and Korkud Demirel

Abstract

In this chapter, treatment of diastema cases by direct (resin composite), indirect technique (PLVs) and multidisciplinary approach (orthodontic/restorative treatment) to achieve functional and esthetic results will be presented.

14.1 Case 1: Direct Composite Buildup with the Help of Silicone Index

A healthy 50-year-old female adult was referred to the clinic because of a significant gap between maxillary central incisors. She was complaining about her smile because of the large space between her upper teeth and wanted the problem to be solved (Fig. 14.1a, b). Her clinical examination revealed a maxillary midline diastema, a healthy gingiva and no hard tissue pathology. No periodontal pockets over 3 mm and no gingival recession were detected. In occlusion analysis, a healthy canine guidance was noted without any interference between teeth that would contraindicate diastema closure, and no sign or symptom was found during temporomandibular joint evaluation (Fig. 14.2). In addition, no pain or sensitivity was noted during maximum opening and lateral or protrusive excursions. Patient perception, personality, lifestyle, and

E. Yildiz, PhD, DDS (✉) • T. Yucel, PhD, DDS • U. Erdemir, PhD, DDS
Operative Dentistry, University of Istanbul Faculty of Dentistry, Istanbul, Turkey
e-mail: eyildiz1966@hotmail.com

K. Sayinsu, DDS, PhD
Orthodontics, Private Practice, Istanbul, Turkey

D. Germec Cakan, DDS, PhD
Orthodontics, Yeditepe University, Dental Faculty, Istanbul, Turkey

K. Demirel, PhD, DDS
Periodontology, University of Istanbul Faculty of Dentistry, Istanbul, Turkey

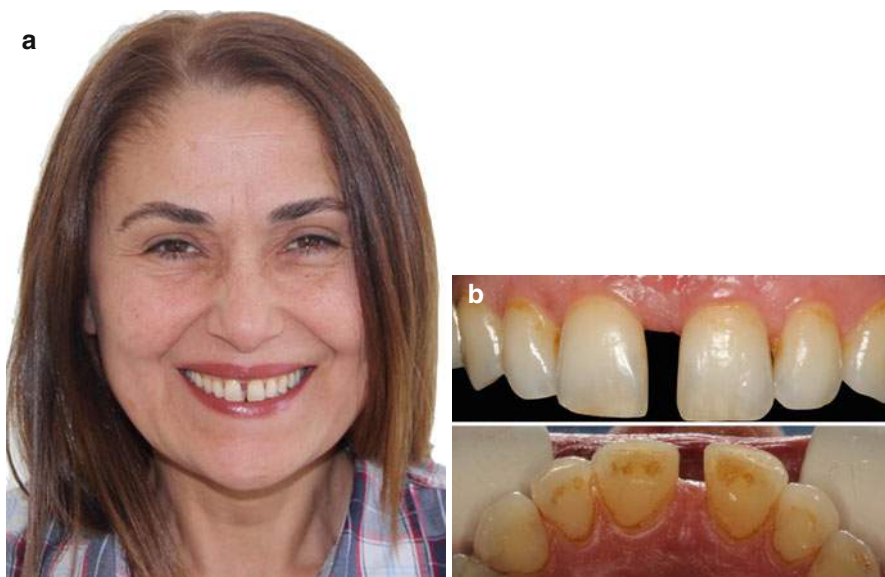
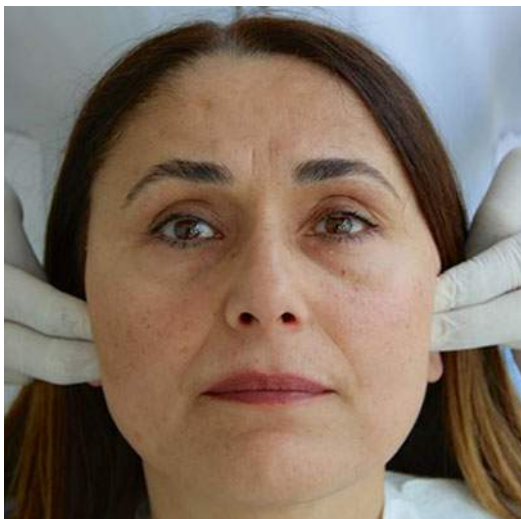

Fig. 14.1 (a) Facial and, (b) intraoral view of the patient

Fig. 14.2 TMJ evaluation of the patient



desires were all recorded in a personal interview. An impression was taken at this stage to prepare a diagnostic study model with wax setup (Fig. 14.3). At the second visit, the study model with sectional wax setup was shown to the patient in order to evaluate the appearance of the closed diastema (Fig. 14.4), and treatment options were discussed. As a part of the clinical examination, panoramic radiograph, and intra- and extraoral photographs (Fig. 14.5) of the patient were also obtained. At this stage, treatment limitations, possible risks, types of treatments, and possible costs of the

Fig. 14.3 Prepared study model with sectional wax setup

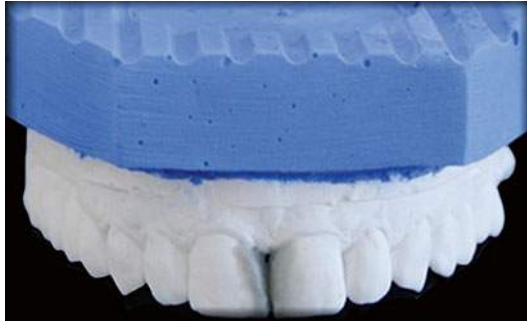

Fig. 14.4 Evaluating the wax setup and appearance of the diastema closed on the study model with the patient

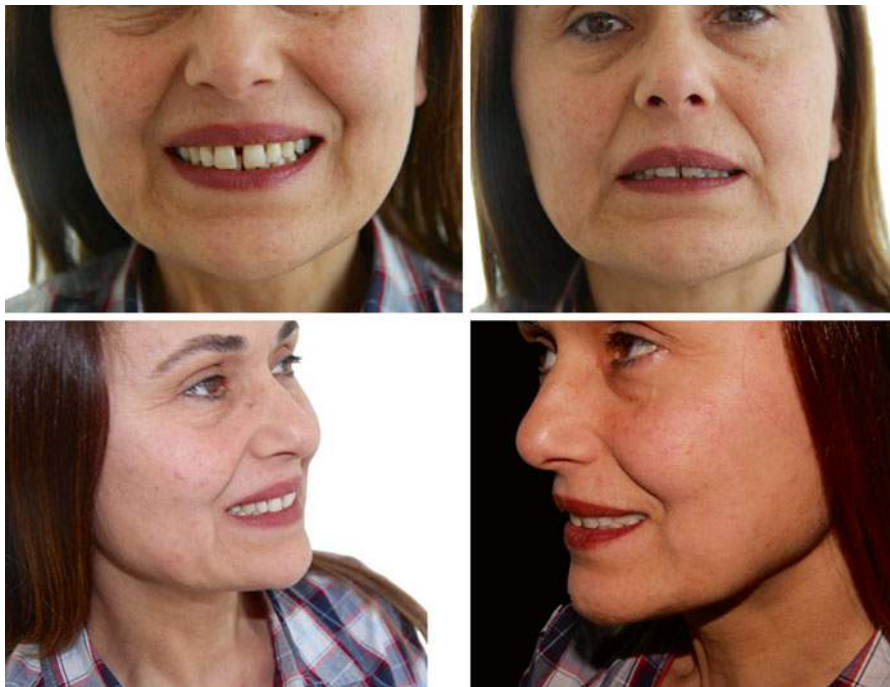
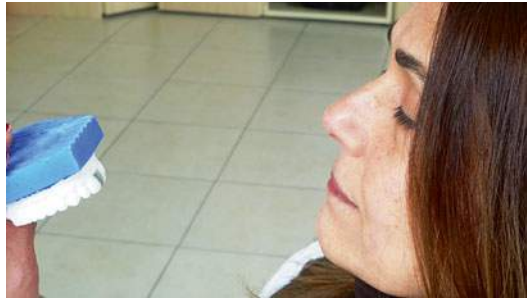
Fig. 14.5 Some of the extraoral photographs of the patient

treatment options were discussed with the patient, and she preferred a conservative and repeatable treatment option with resin composite. Before initiation of restorative procedure, a palatal silicone putty index (Fig. 14.6) was fabricated to assist in guiding palatal morphology and dimensional placement of resin composite. Fabricated silicone putty index was also previewed in the patient's mouth before resin composite placement (Fig. 14.7). Before initiation of restorative treatment, shade selection of the teeth was made using shade guide (Fig. 14.8) that was provided by the manufacturer and then enamel surface of the teeth was roughened with a fine diamond bur (Fig. 14.9) to expose fresh enamel surface for optimal bonding. Her lips and cheeks were properly retracted and retraction cords were placed into the gingival sulcus (Fig. 14.10) in order to control the sulcular fluid and prevent composite resin overhang over this area. The mesial surfaces of the central incisors were then etched (Fig. 14.11) for 30 s with 32 % phosphoric acid (Uni-etch, Bisco Inc., Schaumburg, IL, USA), rinsed for 20 s, and air-dried (Fig. 14.12). A multimode adhesive (Adper Single Bond Universal, 3M ESPE, Neuss, Germany) was applied to the etched enamel surface for 20 s (Fig. 14.13), gently air-dried for 5 s, and then light-cured with a quartz-tungsten-halogen curing light (Hilux, Benlioglu Dental, Ankara, Turkey) for 10 s for each tooth (Fig. 14.14). Then, first lingual/palatal layer of resin composite was applied using A2 shade enamel nanofilled composite material with the help of silicone putty index (Fig. 14.15). A nanofilled resin composite material (Clearfil Majesty ES-2, Kuraray, Okayama, Japan) was used in this case for the resin composite buildup owing to its good handling and color matching characteristics. Placed resin composite material was

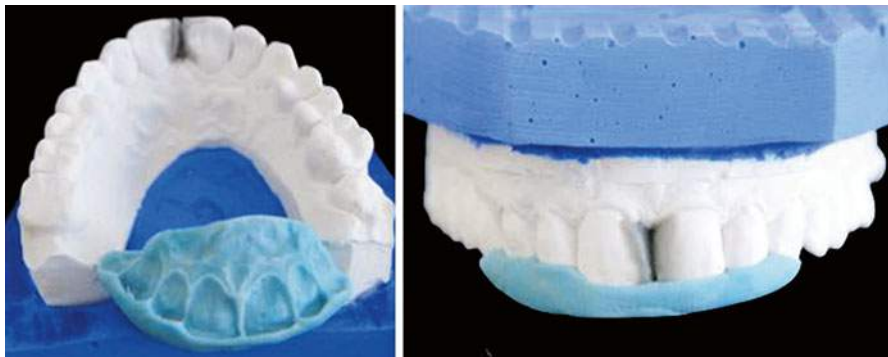


Fig. 14.6 Prepared palatal silicone putty index

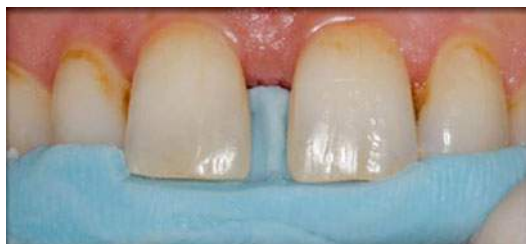

Fig. 14.7 Preview of the silicone putty index in the patient's mouth

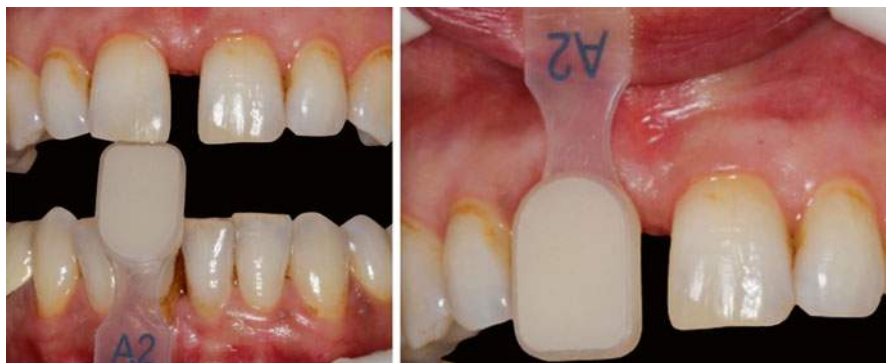

Fig. 14.8 Shade selection of the teeth using manufacturer's shade guide

Fig. 14.9 Roughening enamel surface with a fine diamond bur before initiation of restorative procedure

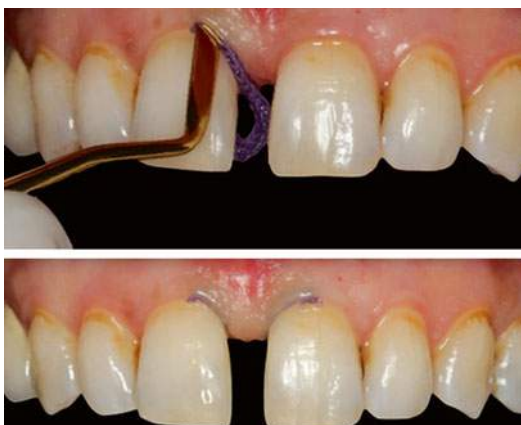
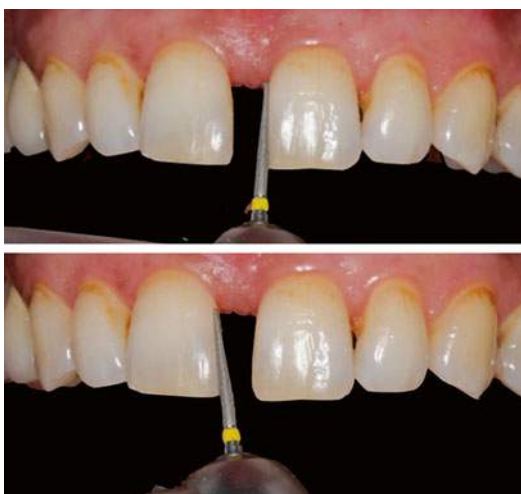
Fig. 14.10 Placement of retraction cords into the gingival sulcus in order to control the fluid

Fig. 14.11 Etching mesial surfaces of the central incisors with 32 % phosphoric acid

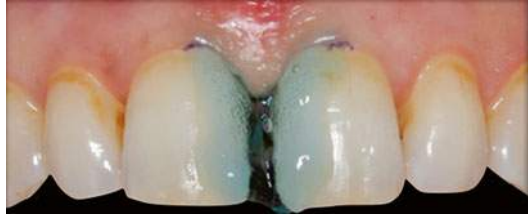

Fig. 14.12 Chalky-white appearance of the enamel surface after acid etching

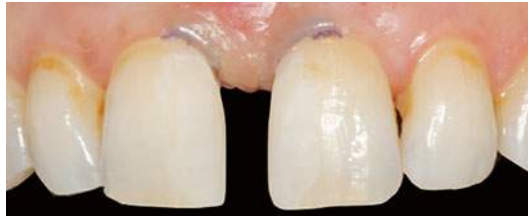

Fig. 14.13 Application of multimode adhesive bonding to the enamel surface

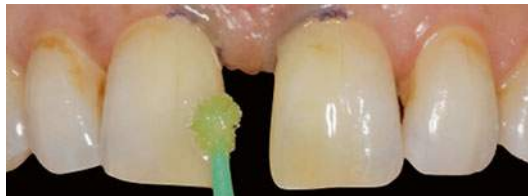

Fig. 14.14 Light-curing of the adhesive bonding

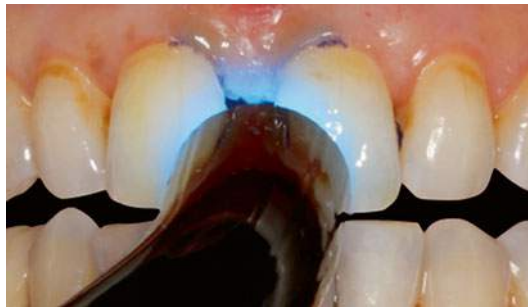
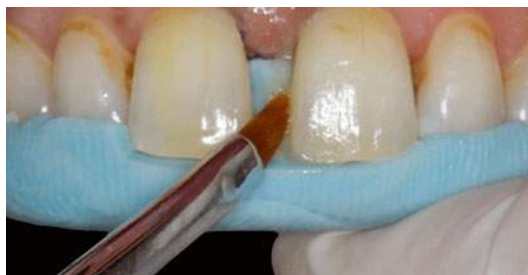
Fig. 14.15 Placement of resin composite with the help of silicone putty index as guide on lingual/palatal surface



carefully shaped and spread with the help of a brush using silicone putty as a guide and then light-cured. After lingual/palatal surface was created for each tooth (Fig. 14.16), A2 shade dentin layer and on top surface A2 shade enamel layer were applied for each tooth, thinned with a brush (Fig. 14.17), and each layer was light-cured. The resin composite material was applied using layering technique in order to simulate natural tooth color. For incisal contours of the teeth, quite a few translucent resin composite materials was added, light-cured and care was taken to create desired proximal contours and avoid to over-contouring especially in the gingival area. After completion of the restorations, each restoration was then light-cured for 40 s from facial and palatal directions and retraction cords were removed. Finishing and polishing of the restorations were done primarily with a fine diamond bur (Fig. 14.18) and proximal contacts were finished and polished using progressively finer-grit finishing strips (Fig. 14.19). Palatinal contours of the restorations were also finished from composite to enamel using a fine-grit diamond bur (Fig. 14.20). Thereafter, finishing and polishing of the restorations were sequentially done using aluminum oxide impregnated polishing discs (Super-Snap, Shofu Inc., Kyoto, Japan), both vestibular and palatal surface (Fig. 14.21). In addition to polishing discs, palatinal surface were also polished using a polishing point (Fig. 14.22) (PoGo, Dentsply, Konstanz,

Fig. 14.16 Creation of lingual/palatal enamel layer for each tooth using silicone putty index as a guide

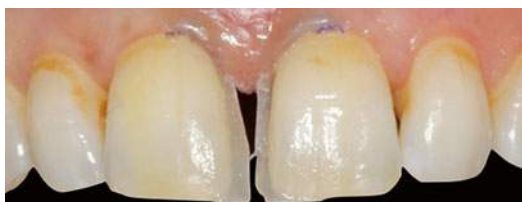

Fig. 14.17 Placement of enamel layer on top surface and thinning with a brush

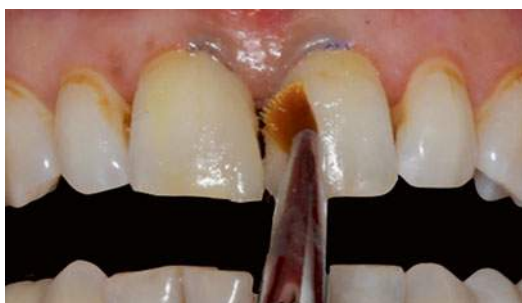
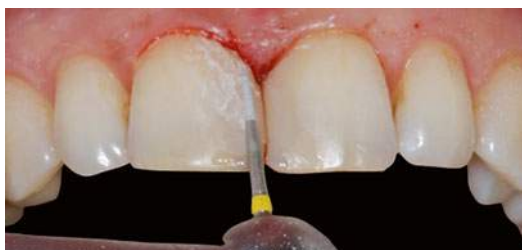
Fig. 14.18 Finishing of the restorations with a fine diamond bur



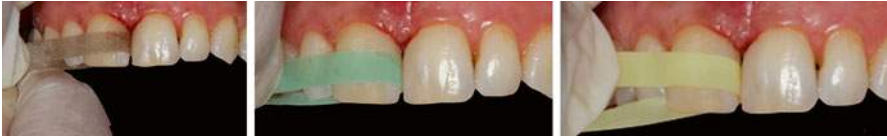

Fig. 14.19 Finishing and polishing of the proximal surfaces using progressively finer-grit strips

Fig. 14.20 Finishing palatal contours of the restorations from composite to enamel using a fine-grit diamond bur

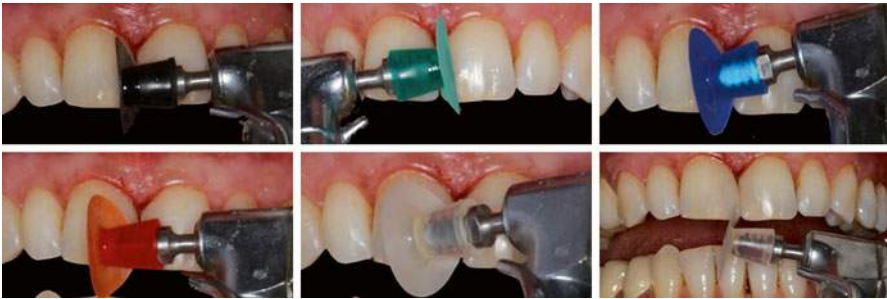
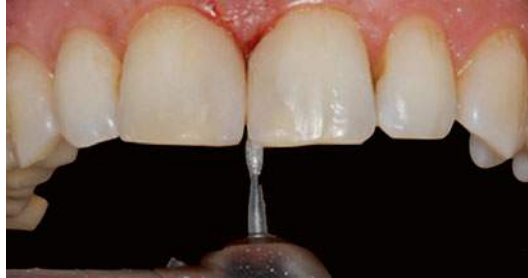
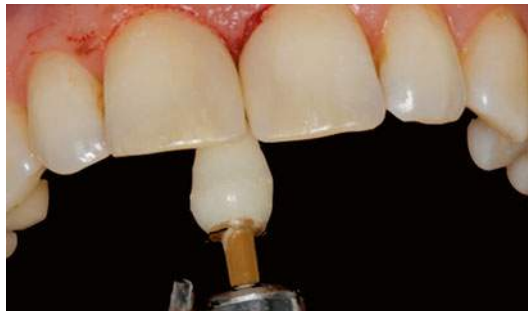Fig. 14.21 Finishing and polishing of the restorations with sequentially used polishing discs

Fig. 14.22 Polishing palatal surface using diamond impregnated polishing point



Germany). After finishing of the restorations, no working interferences were detected during lateral and protrusive movement examinations of the mandible. Figure 14.23 shows the intraoral appearance of the diastema closure with direct resin composite buildup immediately after finishing. The patient was very happy and satisfied with the final natural appearance of the restorations and closed space (Fig. 14.24). Intraoral and facial photographs showed stable results 3 months after the completion of the restorations (Fig. 14.25a, b).

Fig. 14.23 Postoperative appearance of the restorations immediately after finishing and polishing

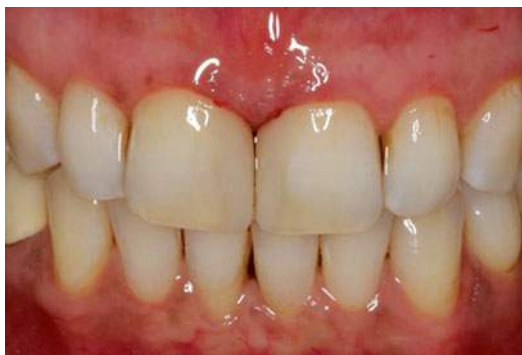

Fig. 14.24 The patient was very happy and satisfied for the closing of the space



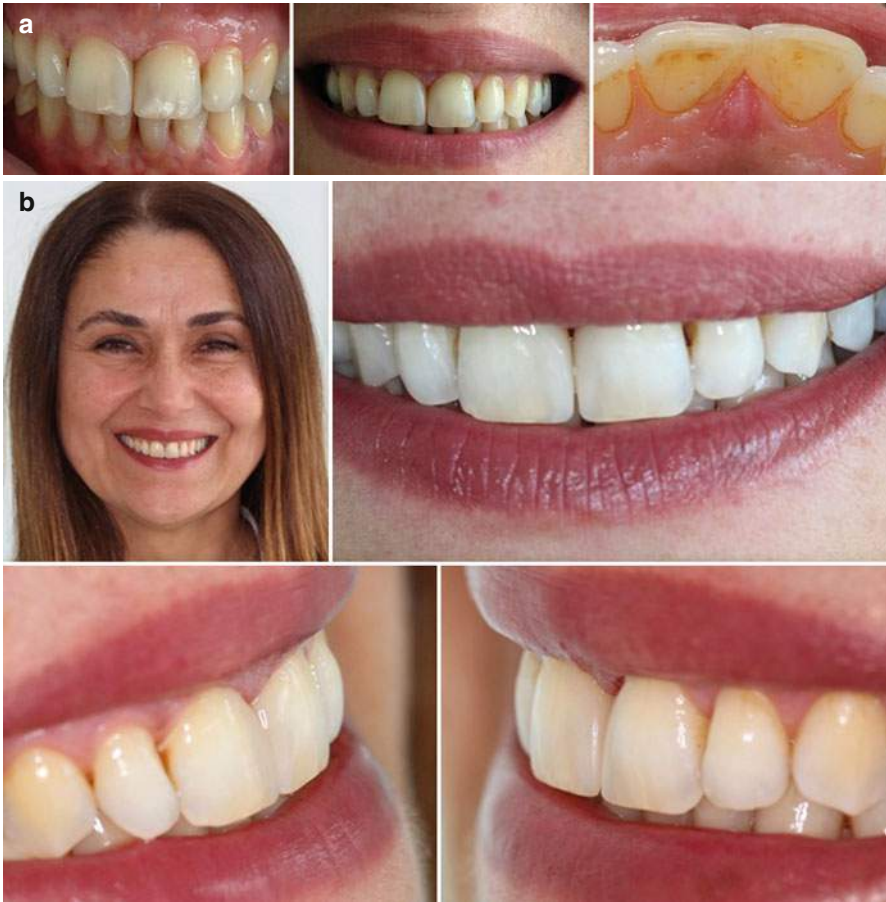

Fig. 14.25 (a) Intraoral and (b) facial photographs of the patient after 3 months

14.2 Case 2: Midline Diastema Closure with Direct Resin Composite Buildup

A 25-year-old male referred to our clinic because of spacing between his maxillary central incisors and he was unhappy with his smile. The clinical examination revealed maxillary midline diastema (approximately 2-mm width) with excellent oral hygiene and incisal wear on his mandibular incisors (Fig. 14.26a–c). Occlusal examination also revealed no pathology or interferences that would contraindicate diastema closure with direct resin composite between maxillary central incisors. After discussing the treatment options with the patient, he decided to have resin composite restorations for the closure of midline diastema. Before starting the diastema closure with direct resin composite buildup, patient lips and cheeks were retracted and the operation field was isolated with retraction

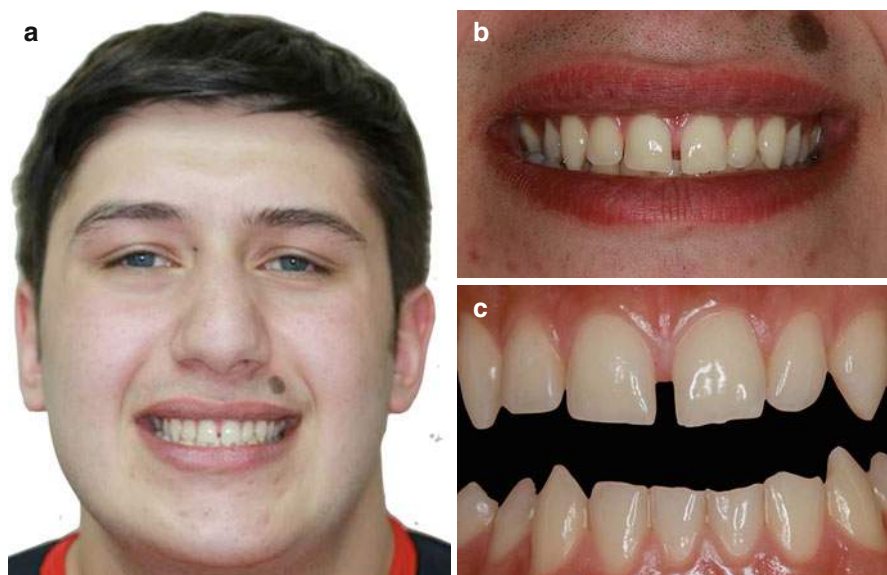
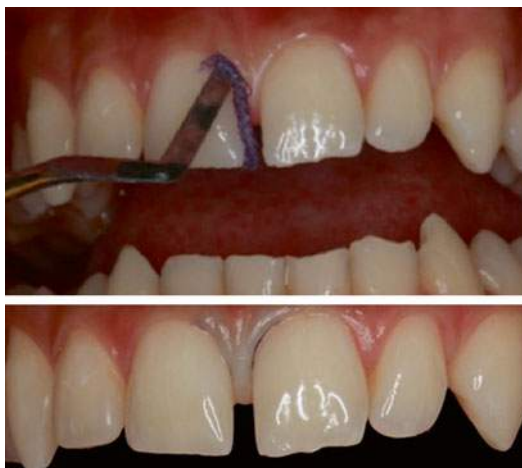
Fig. 14.26 (a) Frontal and (b, c) intraoral view of the patient

Fig. 14.27 Retraction of patient lips and cheeks and isolation of operation field with retraction cords



cords (Fig. 14.27). After placement of retraction cords, shade selection of the teeth was made using shade guide (Fig. 14.28) that was provided by the manufacturer. In this case, no enamel roughening procedure was used, and uncut mesial enamel surfaces were acid-etched (Fig. 14.29) for 30 s with 32 % phosphoric acid gel (Uni-etch, Bisco Inc.), rinsed for 20 s, and air-dried. A multimode adhesive bonding agent (Single Bond Universal, 3M ESPE) was applied to the acid-etched surfaces (Fig. 14.30), gently air-dried, and light-cured for 10 s. Then,

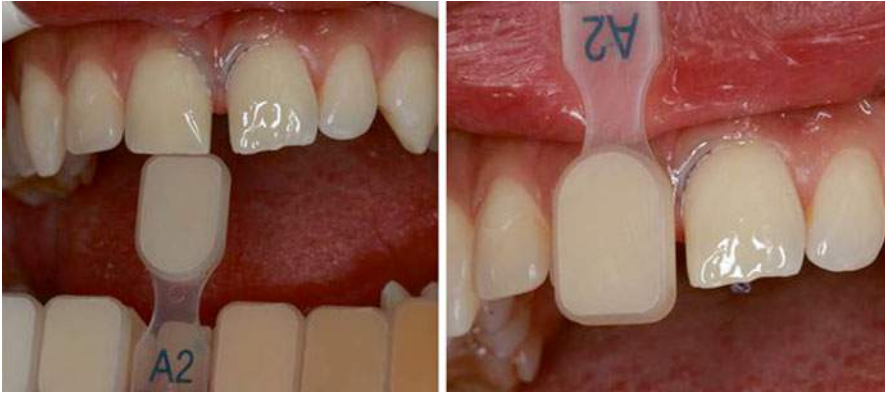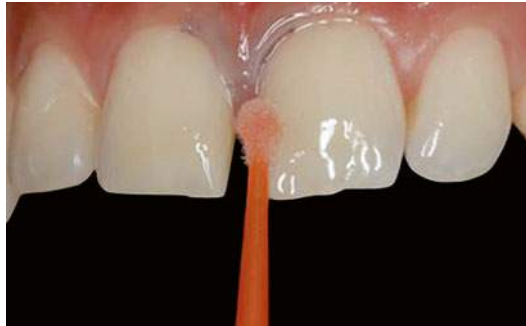


Fig. 14.28 Shade selection of the teeth after retraction cord placement

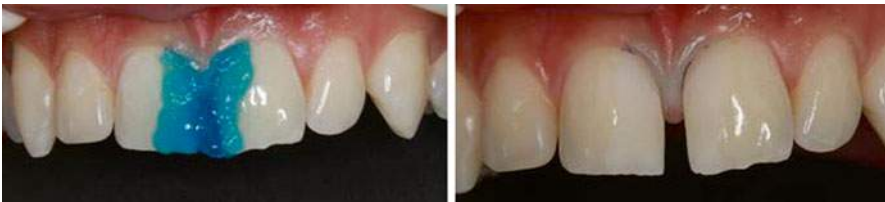

Fig. 14.29 Acid etching of uncut enamel surfaces and chalky-white appearance of the surfaces after acid etching

Fig. 14.30 Application of multimode adhesive bonding agent to the acid-etched surfaces



first proximal layer of resin composite in A2 enamel shade (Clearfil Majesty ES-2, Kuraray) was placed on tooth #11 and light-cured (Fig. 14.31). Thereafter, dentin replacement layer in A2 dentin shade and final enamel composite layer were placed and each layer light-cured. During this step, resin composite

Fig. 14.31 Placement of lingual/proximal enamel layer

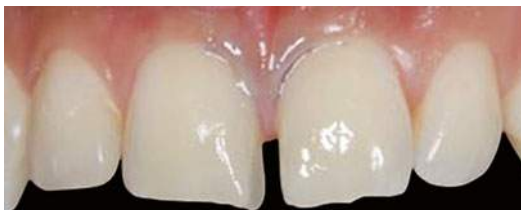

Fig. 14.32 Placement of dentin and final enamel layer and manipulation using a brush

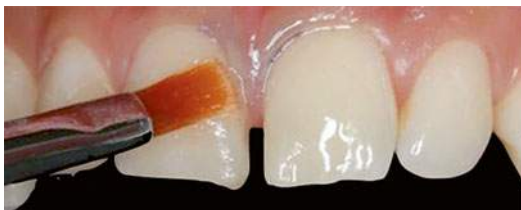
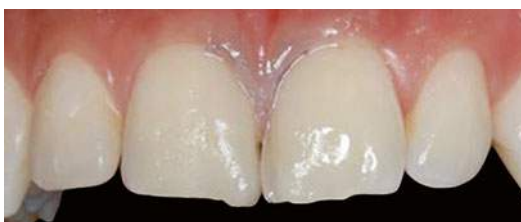
Fig. 14.33 Placement of resin composite on tooth #21 and creation of anatomical proximal contacts



material was carefully manipulated and shaped using a brush (Fig. 14.32). The same procedure was also followed on tooth #21 and restorations were finished. After completion of the restorations, retraction cords were removed and each restoration was then light-cured for 40 s from facial and palatal directions. During placement of the resin composite, care was taken to create the desired anatomical proximal contacts especially in the gingival region (Fig. 14.33). Finishing and polishing of the restorations were primarily done with a fine diamond bur (Fig. 14.34a) and then with sequentially used polishing discs and progressively finer-grit finishing strips (Fig. 14.34b) (Super-Snap, Shofu). Figure 14.35 shows the postoperative appearance of the diastema closure with direct resin composite buildup. Patient was happy with the final outcome.

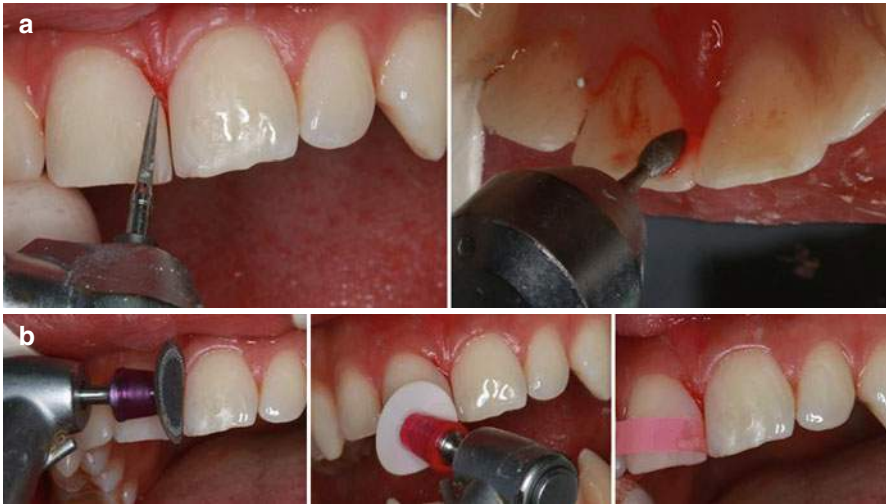

Fig. 14.34 (a) Finishing facial and palatal contours of the restorations using a fine diamond burs. (b) Finishing and polishing of the restorations with sequentially used polishing discs and progressively finer-grit finishing strips

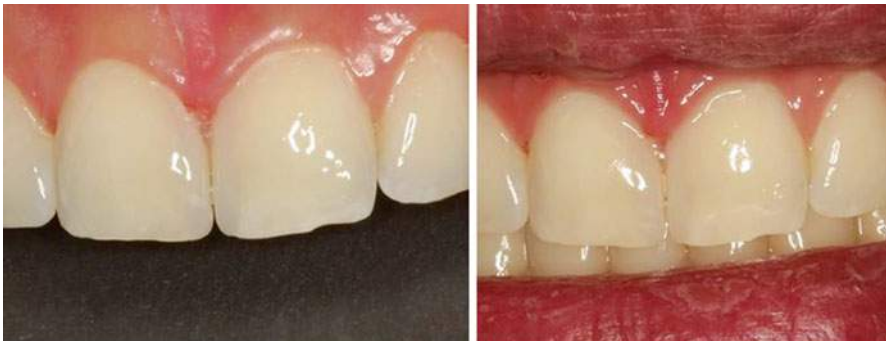

Fig. 14.35 Postoperative view of the restorations

14.3 Case 3: Diastema Closure with Porcelain Laminate Veneers

A healthy 36-year-old woman presented to the clinic with a chief complaint of spaces in her maxillary anterior teeth (Fig. 14.36a, b). She explained that she had orthodontic treatment 6 years ago but the spacing relapsed. She also explained that her lateral incisors were restored with resin composites because of the space at this region. She rejected a further orthodontic intervention. She was also complaining about the color of the teeth. She wanted to have esthetic and stable laminate restorations. Intraoral and radiographic examinations (Fig. 14.37) revealed that she had carious lesion on tooth #18 and #28 with good periodontal health. Caries lesion of tooth #18 was restored with resin composite, and tooth #28 was extracted before initiation of esthetic

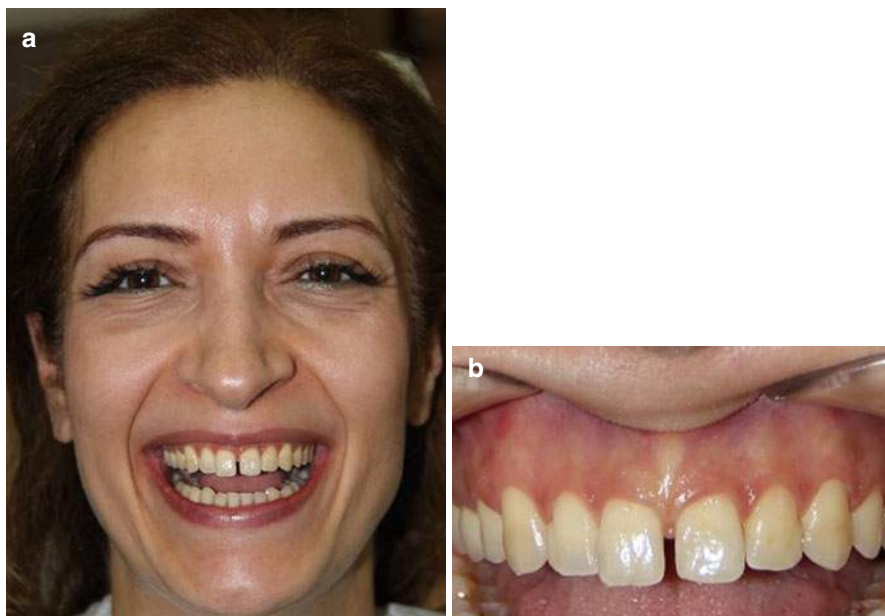

Fig. 14.36 (a) Frontal and (b) intraoral view of the patient

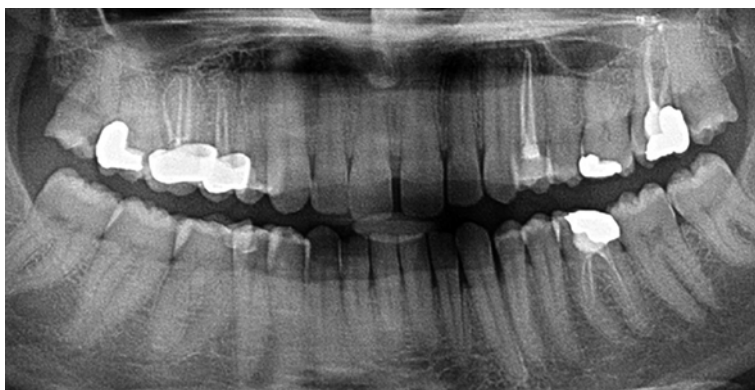

Fig. 14.37 Panoramic radiograph of the patient

restorative rehabilitation. Temporomandibular joints were asymptomatic with no pain or sensitivity during maximum opening and lateral or protrusive excursions. (Fig. 14.38). Before any restorative procedure, patient perception, personality, lifestyle, and desires were all recorded in a personal interview. In addition, her medical and dental history were recorded, and photographs of the patient from different directions were obtained (please see Figs. 5.7, 5.8, 5.9, 5.10, 5.11, and 5.12). An impression was taken at this stage to prepare a diagnostic study model with wax setup for the second visit (Fig. 14.39). Patient occlusion was also checked with diagnostic models with wax setup that were mounted on an articulator (Fig. 14.40). In the second visit,

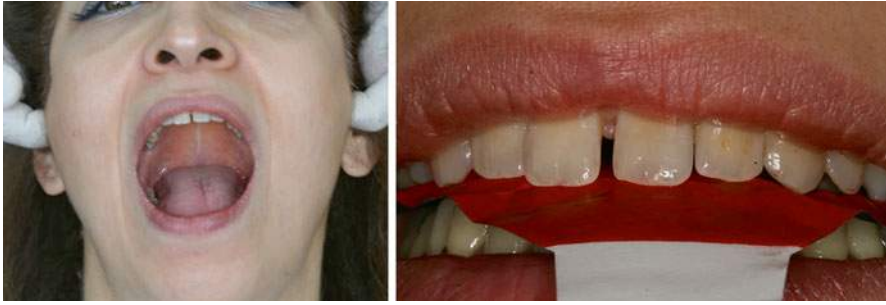

Fig. 14.38 Temporomandibular joint examination during maximum opening and lateral or protrusive excursions of the mandible

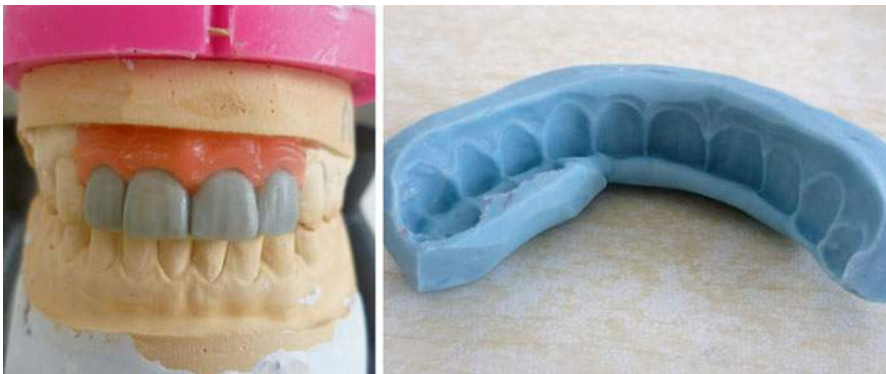

Fig. 14.39 Diagnostic study model with wax setup and laboratory-prepared rigid silicone key.. Note the simulation of pink gingiva around the teeth can help patient to understand the final outcome more easily

the study model with wax setup was shown to the patient in order to visualize the desired modifications (Fig. 14.41). Smile analysis was also performed for the patient to better visualize the proposed treatment (Fig. 14.42). Before initiation of any operative procedure, the patient requested to change the color of the teeth, and two-session in-office bleaching (Opalescence Boost PF, Ultradent Products, South Jordan, UT, USA) each for 20 min was performed (Fig. 14.43). One week after this stage, a mock-up was created using the silicone key (Fig. 14.44) and filled with A2 shade temporary acrylic (Provi Temp K, Bisico, Bielefeld, Germany) to show the nearly ideal restoration to the patient. Pronunciation of the patient, incisal edge position, occlusion, tooth proportions, and smile were also evaluated at this stage, and patient agreement on final outcome was obtained. Tooth preparation was begun using a round diamond bur (size no: #021), while the mock-up placed on teeth and initially the marginal borders and then the facial surface depth guide were prepared. The entire surfaces were then prepared using round-ended diamond bur in accordance with the tooth convexity, and incisal edges were also reduced with the same bur (Fig. 14.45a–c). After the teeth surface preparation was completed, reduction and preparations were controlled by placing silicone index onto the teeth and sufficient preparation were verified (Fig. 14.46). After the retraction cord placement, final impression was taken and sent

Fig. 14.40 Occlusion control with wax setup on an articulator

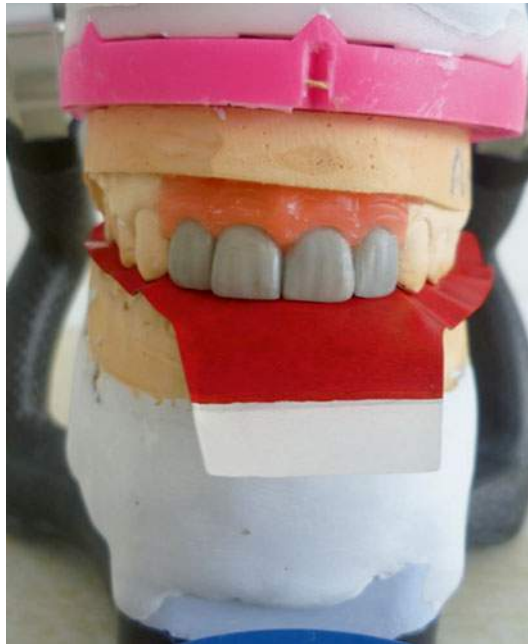

Fig. 14.41 Showing study model with wax setup to the patient in order to visualize the desired modifications

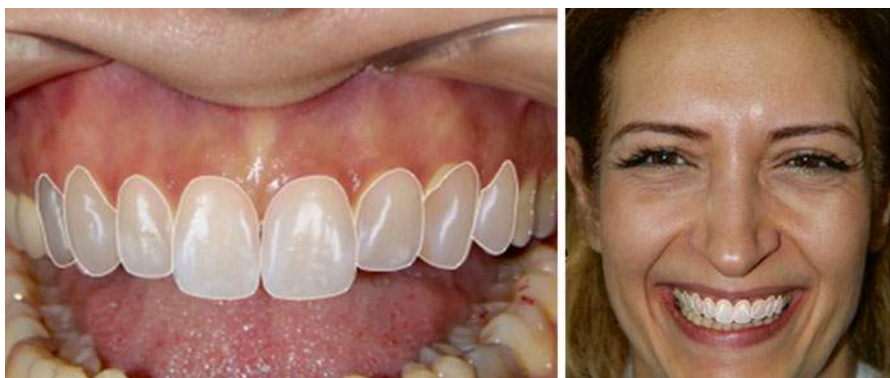
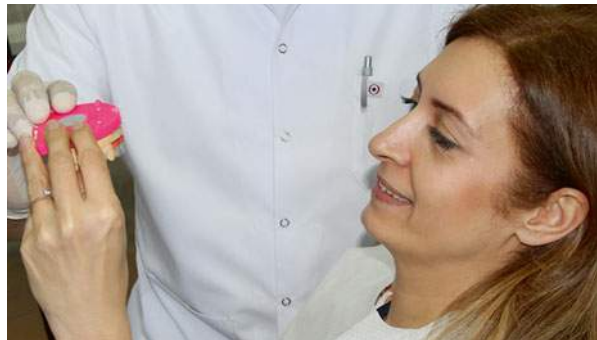
Fig. 14.42 Performed part of the smile analysis for the patient

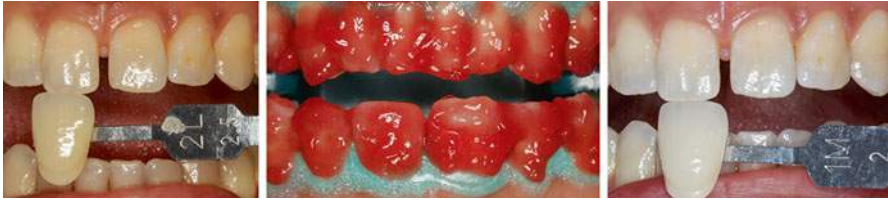

Fig. 14.43 Change of teeth color with in-office bleaching before restorative procedures

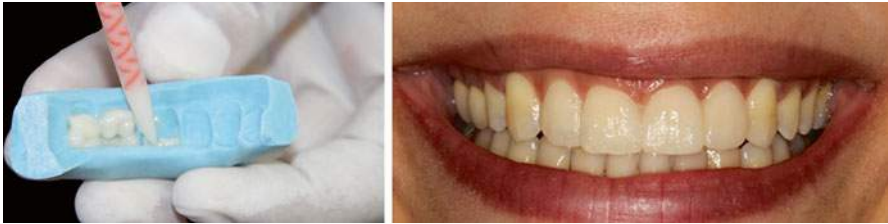

Fig. 14.44 Creating a mock-up for the patient using silicone key

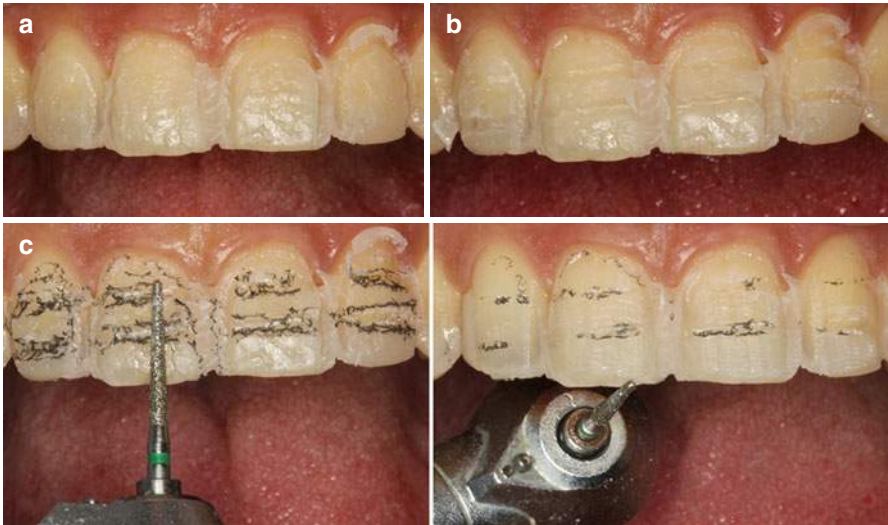


Fig. 14.45 Tooth preparation while the mock-up is in place. (a) Preparation of marginal borders depth guide. (b) Preparation of facial surface depth guide. (c) Preparation of entire surface and incisal edge

to the laboratory for fabrication of PLVs. Prepared PLVs were controlled onto the patient teeth for verifying adequate contacts, fitting on marginal borders and color test using try-in pastes (NX3 Try-in gel, Kerr Corp., Orange, CA, USA) before final glaze and finishing (Fig. 14.47). Before cementation of PLVs, teeth surfaces and internal surface of the veneers were correctly prepared (please see Figs. 13.12, 13.13, 13.14, and 13.15). The completed PLVs were cemented on the tooth surface using a multi-mode dentin adhesive (Single Bond Universal, 3M ESPE) and light-curing resin cement (NX3, Kerr Corp., Orange, CA, USA). After cementation, excess resin cement

Fig. 14.46 Teeth surface reductions and preparations were verified by placing silicone index onto the teeth. Note, on the diastema side, the preparations were finished lingually

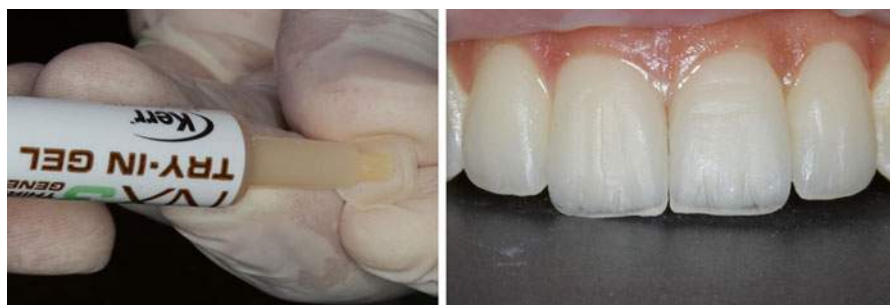
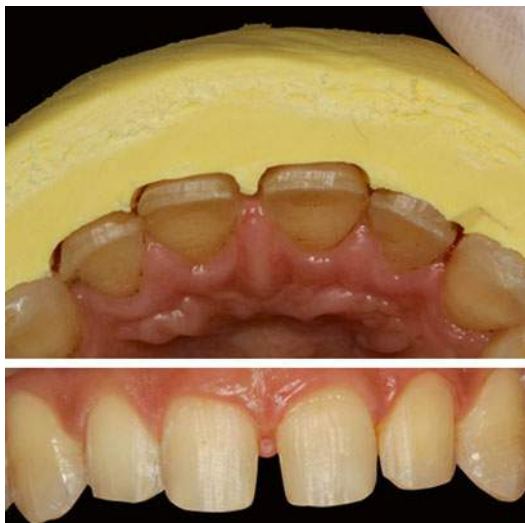
Fig. 14.47 Controlling of PLVs using try-in pastes before final glaze and cementation

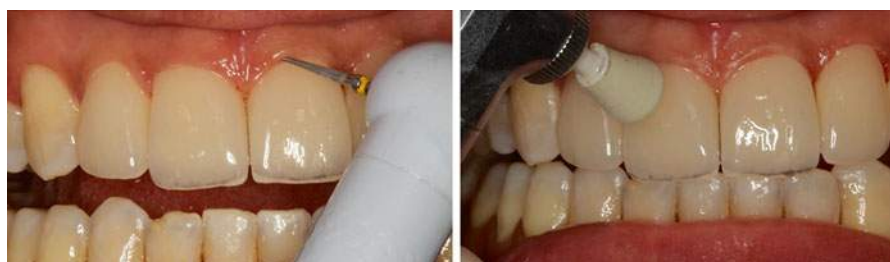

Fig. 14.48 Correction and polishing of the gingival area using fine diamond bur and porcelain polishing cup

was removed from the subgingival area using a scalpel blade, and further necessary corrections were done using fine diamond burs, and polishing was carried out using porcelain polishing cups (Fig. 14.48). The occlusion of the patient was then reexamined after cementation of PLVs (Fig. 14.49), and if necessary, corrections were done with a fine-grain diamond bur. Figure 14.50a–c shows the intraoral and facial view of the patient. The patient was very happy with the harmonious and natural final results.

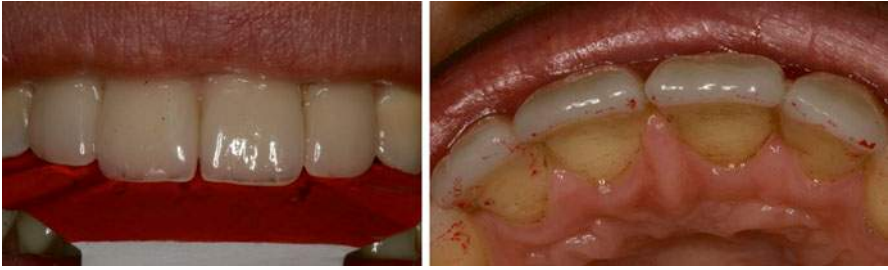

Fig. 14.49 Occlusion examination after cementation of PLVs

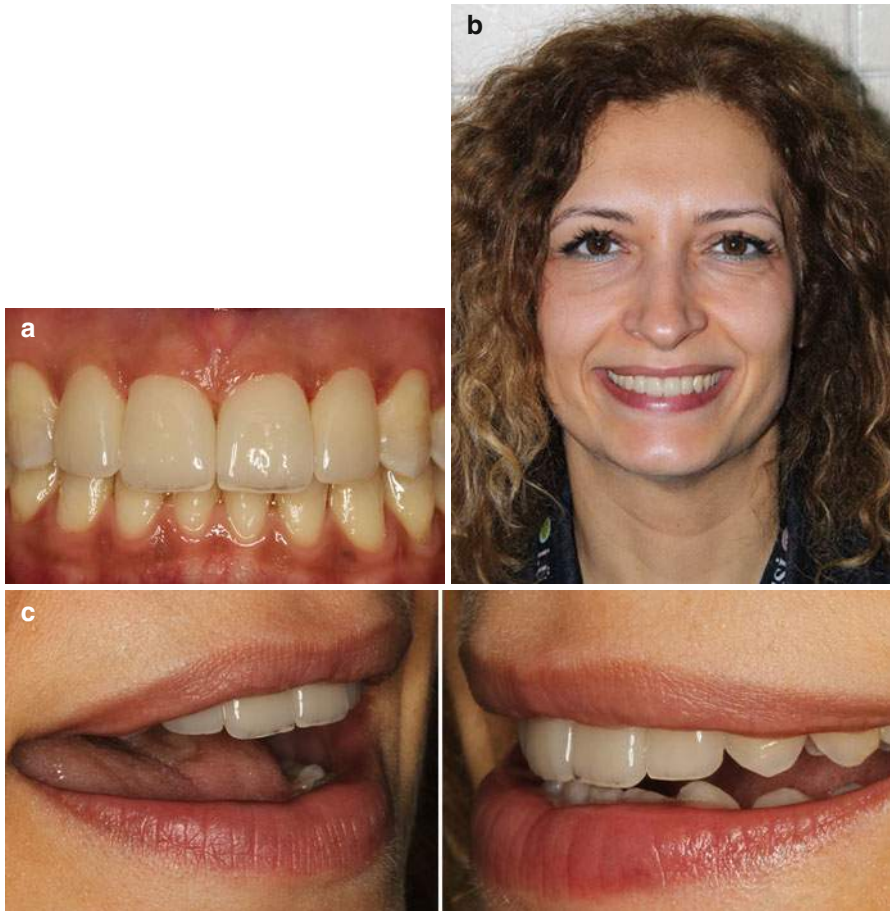

Fig. 14.50 (a) Intraoral and (b, c) facial view of the patient after cementation of PLVs

14.4 Case 4: Orthodontic-Restorative Treatment of Diastema

The main concern of this 21-year-old male patient was a median diastema and an unpleasant smile (Fig. 14.51). His primary goal was to improve his smile with a conservative treatment approach.

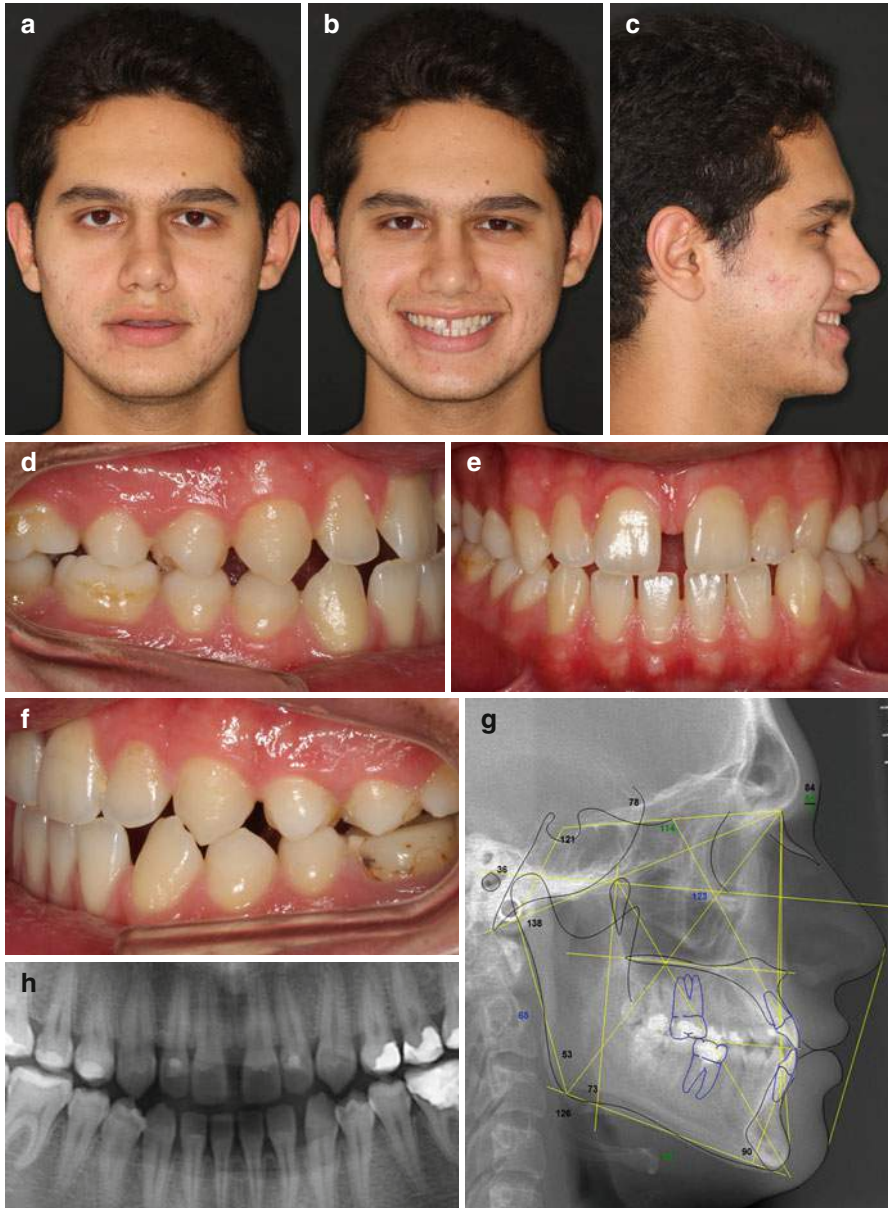


Fig. 14.51 (a–c) Pretreatment extraoral photographs, (d–f) pretreatment intraoral photographs, (g, h) pretreatment radiographs

14.4.1 Medical History

His medical history was noncontributory.

14.4.2 Diagnosis

14.4.2.1 Extraoral Findings

- Retrognathic maxilla
- Low smile line, inadequate incisor display
- Maxillary midline shifted to the right side

14.4.2.2 Intraoral Findings

- Maxillary median diastema
- Undersized maxillary lateral incisors
- High frenum attachment
- Polydiastema in the lower jaw
- Angle Class III molar and canine relationships
- Insufficient overbite and overjet
- Maxillary left lateral incisor and canine in crossbite
- Healthy gingival status

14.4.2.3 Dental Cast Analysis

- Hays Nance: 5-mm excess space in the maxillary dental arch
3.5 mm excess space in the mandibular dental arch
- Bolton: 1.8 mm mandibular excess for 6 anterior teeth

14.4.2.4 Radiographic Findings

- No bone loss

14.4.2.5 Cephalometric Findings

- Slight Class III skeletal pattern
- Retrognathic maxilla
- Normal vertical growth pattern
- Proclined maxillary incisor
- Normal mandibular incisor inclination
- Straight profile

14.4.2.6 Summary

The patient had skeletal and dental Class III malocclusion with maxillary median diastema and mandibular polydiastema. His overbite and overjet was reduced.

14.4.3 Treatment Plan

In this case, diastemas were mainly caused by arch-tooth size discrepancies and tooth size anomalies. In addition to the spacing, he had skeletal and dental malocclusion.

Treatment goals were to close existing spaces, correct anterior crossbite, obtain skeletal and dental Class I relationships with proper overjet and overbite, eliminate tooth size discrepancy, and achieve esthetic and functional occlusion.

14.4.4 Treatment Alternatives

His main concern was the presence of the median diastema. In order to close the diastema, restorative treatment modality was considered as the first plan. But a satisfactory dental appearance and a pleasant smile would not have been achieved because of the uneven distribution of the spacing between maxillary incisors.

A second treatment option was planned to solve both the skeletal and dental malocclusion and the spacing. This interdisciplinary treatment plan, including orthodontic treatment, orthognathic surgery, and restorative treatment, was rejected by the patient because it was an invasive approach.

The third alternative was an interdisciplinary approach including orthodontics to address the malocclusion and redistribute the spacing, followed by a restorative treatment. A frenectomy was also planned. The patient preferred the third option because it was more conservative.

14.4.5 Treatment Progress

The treatment started with orthodontics. Maxillary and mandibular dental arches were aligned and leveled. In the mandibular dental arch, diastemas were closed by retraction of the anterior teeth (Fig. 14.52). In the maxillary arch, mesialization of the posterior teeth partly closed the spacing. Class III intermaxillary elastics which were used to correct molar and canine relationships further helped to achieve mesial movement of the maxillary teeth and distal movement of the mandibular teeth (Fig. 14.53). Maxillary midline diastema was closed; however, frenectomy was not performed because the patient

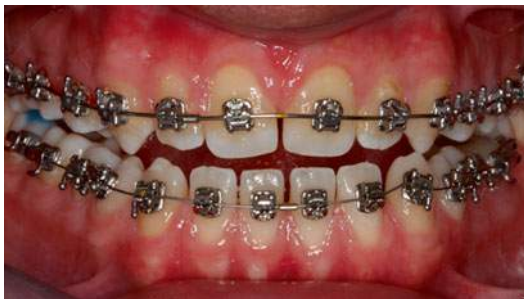

Fig. 14.52 Initial alignment with orthodontic treatment

rejected any surgical intervention. The remaining maxillary spaces due to undersized teeth were distributed mesial and distal to the lateral incisors (Fig. 14.54). Before debonding, the position of the maxillary teeth was checked by the restorative dentist. Upon her approval, orthodontic treatment has been completed and the braces were removed. The restorative dentist waited for 2 weeks for the recovery of the gingival tissue. The

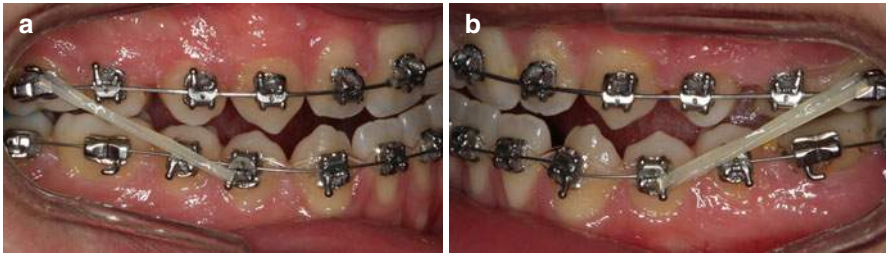


Fig. 14.53 (a, b) Use of intermaxillary elastics

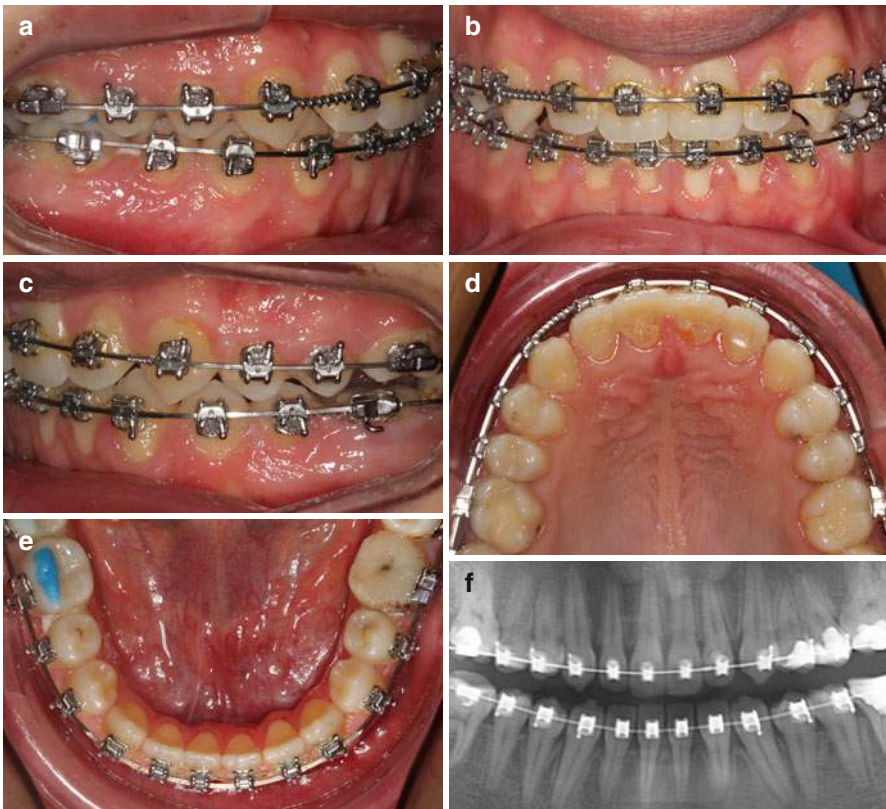


Fig. 14.54 (a–d) Redistribution of the remaining spaces in the maxillary arch mesial and distal to the lateral incisors, (e) closure of the mandibular diastema with orthodontics, (f) panoramic radiograph showing spaces distal to the maxillary lateral incisors

maxillary lateral incisors were restored with direct composite restorations. To maintain alignment and diastema closure, fixed lingual retainers were bonded (Fig. 14.55).

14.4.6 Treatment Results

This conservative interdisciplinary treatment approach enabled to close the diastemas, obtain Class I canine and molar relationships with proper overjet and overbite, and achieve good tooth proportions. Thus, satisfactory esthetic outcomes and a functional occlusion were achieved. The posttreatment follow-up of the patient after 1 year showed stable orthodontic and restorative results with healthy gingival status (Fig. 14.56).

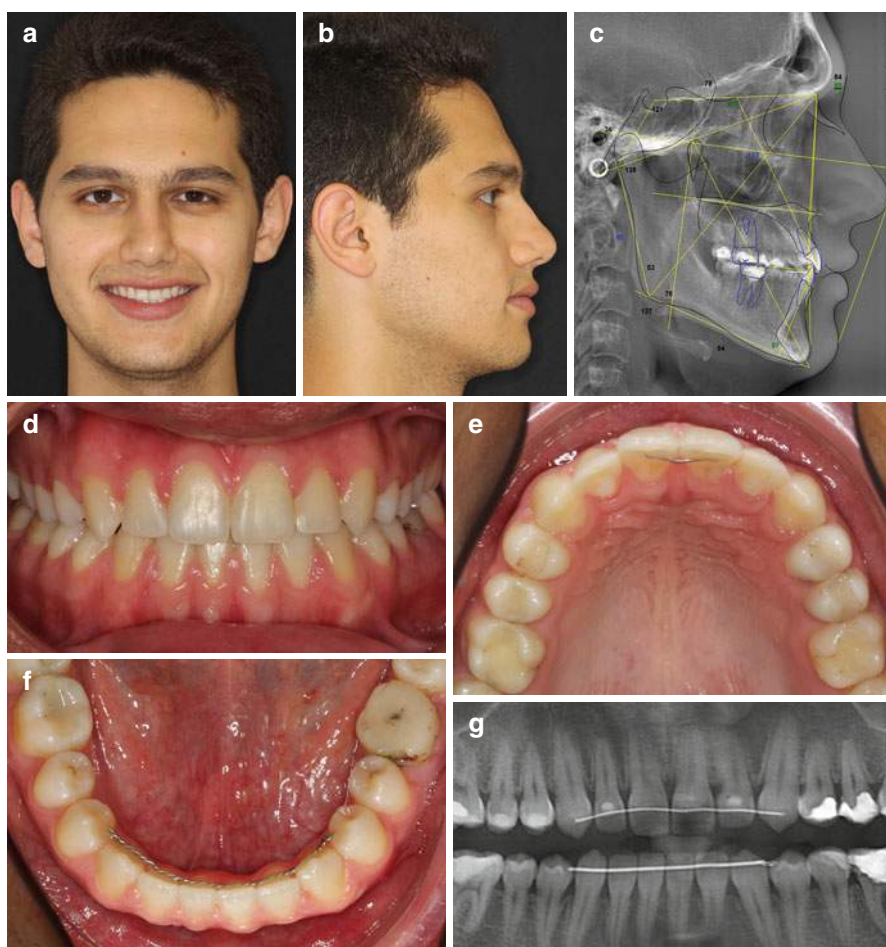


Fig. 14.55 (a, b) Extraoral photographs after orthodontic and restorative treatment, (c) lateral cephalometric radiograph, (d–f) intraoral photographs, (g) panoramic radiograph (Restorations by Dr. Sehnaz Kazokoglu)

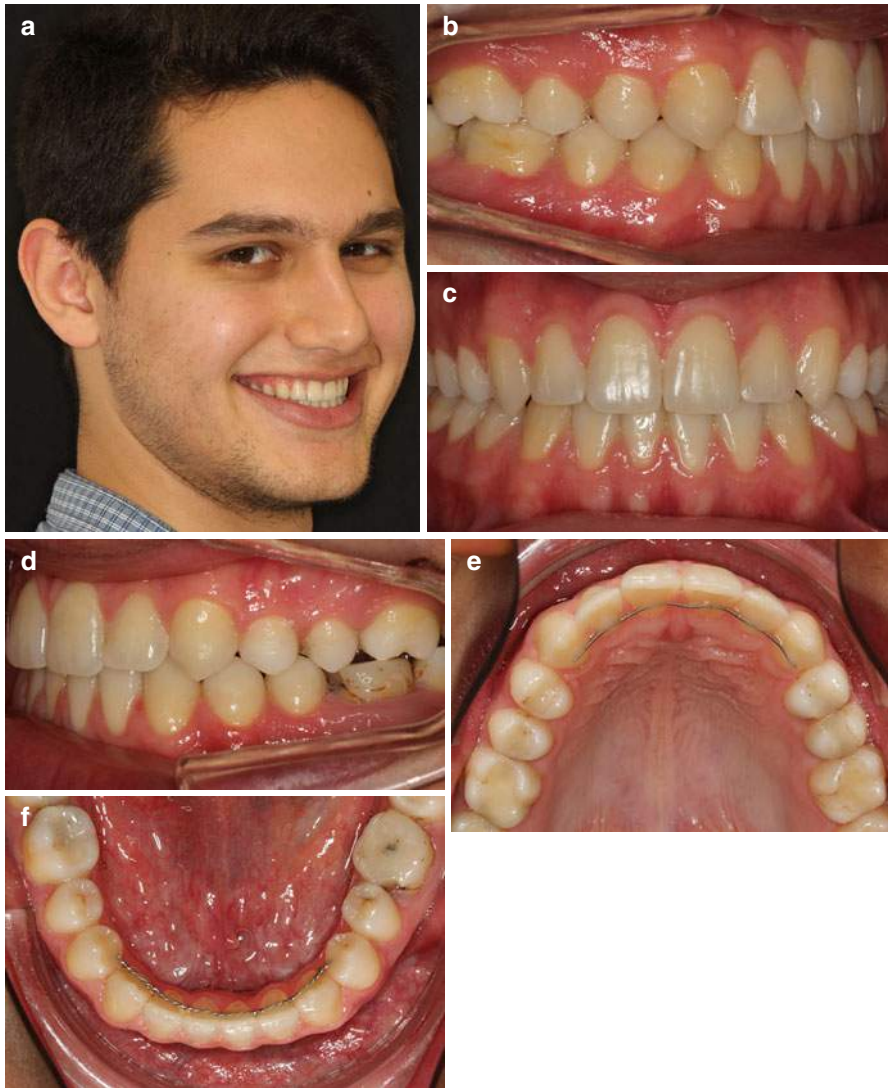


Fig. 14.56 (a) Extraoral photograph 1 year after treatment, (b–f) intraoral photographs

Index

A

Acquired diastema. *See* Congenital/acquired diastema

B

Bioclear Matrix Systems, 174, 175
Blanching test, 30
Bolton analysis
 maxillary and mandibular tooth size relationships, 109, 110
 mesiodistal widths, measurement of, 108

C

CAD/CAM. *See* Computer-aided design/computer-aided manufacturing (CAD/CAM)
Cementoenamel junction (CEJ), 125
Cephalometric analysis
 measurements, 76
 IMPA, 77
 lower lip and esthetic plane, 78
 upper incisor-SN, 77
 upper incisor to Frankfort horizontal (U1-FH), 77
 upper lip and esthetic plane, 78
 objectives of, 76
Circular fibers, 125
Computer-aided design/computer-aided manufacturing (CAD/CAM), 191–193
Congenital/acquired diastema
 dentition, physiological development of
 mixed dentition stage, maxillary midline diastema in, 6, 7
 primary interdental spacing, 6, 7
 ugly duckling stage, 6, 8
 enlarged labial frenum and deficient intermaxillary suture, 10–12

 heredity and ethnicity, 7, 8
 rapid maxillary expansion, 14
 systemic, pathologic, and physical conditions, 12–13
 tooth size and arch length discrepancies
 generalized diastema, 9, 10
 generalized maxillary spacing, 8, 9
 peg-shaped maxillary lateral incisor, 9
 small-sized lateral incisor, 9
 unbalanced muscular function and habits, 13–14
Crown lengthening procedure, 89–91, 132, 136, 177–178
Cupid's bow, 74, 75

D

Dental analysis
 Bolton analysis (*see* Bolton analysis)
 dental model analysis, 106–107
 maxillary central teeth, 102
 occlusion, 119
 space analysis
 actual arch length, 107
 mesiodistal tooth widths, 107
 software program, 107, 108
tooth form and design
 aligned maxillary anterior teeth, incisal embrasure size, 112
 axial inclination, 110, 111
 color, surface texture, transparency and incisal characterization, 113
 interdental contact area/connector space, 111–112
 shade progression, incisal part characteristics, 114
 tooth surface characteristics, 113, 114
tooth proportions, 118
 golden proportion and golden percentage, 115, 117

- Dental analysis (*cont.*)
 Golden Section Divider, 116–117
 RED proportions, 115, 117
 tooth size, maxillary central incisor, 102
 digital caliper, 103
 esthetic zone, 105, 106
 gingival margin, 104, 105
 natural and perfect perception, 105
- Dentogingival fibers, 125
- Dentolabial analysis
 buccal corridor
 deficiency, 93
 healthy gingival structure, 96, 97
 interdental papilla formation, 96–98
 less/minimal negative space, 93, 94
 marginal gingival level, 94–95
 maxillary lateral incisors, 95
 restorative treatment procedures, 98, 99
 zenith point, 96, 97
 incisal display, 89–91
 incisal edge position
 definition, 84
 “E” sound pronunciation, 87, 88
 “F” and “V” sound pronunciation, 87, 88
 maxillary canines, 85
 at rest, 82
 “S” sound pronunciation, 87–89
 temporary acrylic resin, 86
 lip length, 82
 lip mobility, 82, 84
 lip movement, 81, 82
 lip thickness, 82
 smile line
 definition, 90, 91
 maxillary centrals, 90, 92
 reverse smile line, 92
 tooth structure, visibility of, 82, 83
- Dento-periosteal fibers, 125, 126
- Diagnosis
 diagnostic setup
 pretreatment models, 50, 51
 three-dimensional virtual treatment simulation, 51
 digital imaging, 46, 48, 49
 extraoral digital photographs, 40, 41
 mock-up, 46
 auto-cure temporary filling, 47, 48
 incisal edge position, “F” sound pronunciation, 47
 silicone putty, 47, 48
 smile analysis, 48, 49
 wax-up model
 chairside direct evaluation, 43, 44
 multidisciplinary treatment procedure, 43
 occlusion control, 40
 and photographic evaluation, 41
 pink matrix, 43–45
 plaster models, 42–45
 silicone matrices, 42–46
- Diastema
 congenital/acquired diastema, causes of
 dentition, physiological development of, 6–8
 dentoalveolar discrepancies, 8–10
 enlarged labial frenum and deficient intermaxillary suture, 10–12
 heredity and ethnicity, 7, 8
 iatrogenic factors, 14
 systemic, pathologic, and physical conditions, 12–13
 unbalanced muscular function and habits, 13–14
 definition of, 1, 5
 direct-indirect restorative treatment (*see* Direct-indirect restorative treatment)
 etiology of, 1, 2
 midline diastema (*see* Midline diastema)
 orthodontics (*see* Orthodontics)
 periodontal treatments, 3
 polydiastema (*see* Polydiastema)
 soft tissue considerations (*see* Soft tissue considerations)
- Direct-indirect restorative treatment, 1, 2
 Bioclear Matrix Systems, 174, 175
 composite mock-ups, 176
 dental midline, 178, 180
 diagnostic wax setup, 176
 digital smile design software, 176
 gingival tissue recontouring, provisional restorations, 178, 180
 interproximal contact area, 179, 181
 maxillary diastema, 176, 177
 minimal enamel preparation, fine diamond bur, 171, 172
 natural triangular-shaped papillae, 178, 179, 181
 operated enlarged frenulum, 172, 174
 periodontal crown lengthening procedure, 177–178
 porcelain laminate veneers
 disadvantages, 175–176
 incisal crown lengthening and diastema closure, 178, 179
 minimal invasive tooth preparation for, 174, 175

resin composite buildup, 170
 resin composite materials, 171–173
 short clinical crown, 176–178
 silicone index, 172, 173
 small space, 176, 177
 tooth surface, cleaning of, 172–174
 unaesthetic appearance and disproportionate tooth form, 178, 179
 wax setup/direct mock-ups, 171

E

Empress systems, 191, 192
 Esthetic parameters/smile design
 decision-making treatment process, 55, 57
 dental photographs
 facial and profile photographs, static and dynamic smile, 58, 60
 intraoral examination, 62, 63
 maxillary anterior teeth display, 59, 63
 natural postural head position, 58, 59, 61
 12 o'clock position, patient face, 58, 62
 rest position, half smiling and full smiling, 59, 62
 digital smile designing protocol, 57
 harmoniously aligned teeth, restorations, 55, 57
 Keynote, 55, 57, 58
 macroesthetic evaluation, 55, 56
 microesthetic evaluation, 55, 56
 objective analysis protocols, 54–55
 patient awareness, 54
 teeth measurements, digital caliper for, 63, 64

F

Facial-dentofacial analysis
 Burststone's line, 72, 74
 canted midline, 75
 commissural line, 69, 70
 dental midline, 73–75
 facial esthetics, 70, 71
 facial midline, 73–75
 facial profile evaluation, 71, 72
 facial symmetry, 73
 facial thirds, evaluation of, 66
 Frankfort horizontal plane, 69, 70
 incisal plane, 68, 69
 interpupillary line, 68, 69
 labial line, 72, 73
 lateral cephalometric analysis, 71

lateral facial profile, 71
 mid- and lower-face heights, 67
 nasal line, 72, 73
 Ricketts E-plane, 72
 Steiner's line, 72, 74
 Frenectomy
 enlarged frenum, 132, 134
 and periodontal crown lengthening procedure, 132, 136
 timing of, 164–165

G

Golden Section Divider, 116–117

H

Hays Nance analysis
 measurement of
 actual arch length, 107
 mesiodistal tooth widths, 107
 software program, 107, 108

I

Incisor mandibular plane angle (IMPA), 77
 Initial consultation and clinical considerations
 clinical examination, 19
 esthetic dentistry, comprehensive evaluation in, 18
 esthetic evaluation, 36
 extraoral examination
 12 o'clock position, 19, 20
 TMJ examination (*see* Temporomandibular joint (TMJ))
 intraoral examination
 intraoral camera/professional digital photographs, use of, 28
 professional tooth cleaning, 28
 series of photographs, 29
 labial frenum examination, 30
 medical history, 19
 muscle examination
 anterior temporalis muscle, 23, 24
 digastric muscle, 26, 27
 lateral pterygoid area, superior maxillary tuberosity, 24, 26
 masseter muscle, 23, 24
 medial pterygoid muscle, 24, 26
 occipital muscle, 24, 25
 sternocleidomastoid muscle, 24, 25

Initial consultation and clinical considerations
(*cont.*)

- occlusion examination
 - centric occlusion, 32, 33
 - interarch and tooth-to-tooth relationships, visualization of, 32
 - lateral excursion control, 32
 - lateral motions, 33
 - occlusal interference, factors/problems for, 34
 - T-Scan computerized system, 34, 35
- periodontal examination, 29–30
- private consultation room, 18
- radiographic evaluation, 31–32
- tongue examination, 30–31

K

Keynote, 55, 57, 58

M

- Macroesthetics, 55, 56, 58
- Microesthetics, 55, 56, 59
- Midline diastema, 1–3
 - clinical practice guidelines of, 143
 - direct resin composite buildup, midline diastema closure
 - dentin and final enamel layer, placement of, 209
 - fine diamond bur, 209, 210
 - frontal and intraoral view, 206, 207
 - lingual/proximal enamel layer, placement of, 208, 209
 - multimode adhesive bonding agent, 207, 208
 - resin composite, placement of, 209
 - restorations, postoperative view of, 209, 210
 - retraction cord placement, 207
 - shade selection, shade guide, 207, 208
 - uncut enamel surfaces, acid etching of, 207, 208
- maxillary central incisors, 5, 6
 - in mixed dentition stage, 6, 7
 - ugly duckling stage, 6, 8

O

- Orthodontic-restorative treatment of diastema
 - cephalometric findings, 218
 - dental cast analysis, 218
 - extraoral findings, 218
 - interdisciplinary approach, 219
 - intraoral findings, 218

- medical history, 218
- pretreatment extraoral photographs, 217
- pretreatment intraoral photographs, 217
- pretreatment radiographs, 217
- radiographic findings, 218
- restorative treatment modality, 219
- skeletal and dental malocclusion and spacing, 219
- treatment plan, 219
- treatment progress, 219–221
- treatment results, 221, 222
- Orthodontics, 2, 3, 151
 - abnormal oral habits, habit breakers, 148–151
 - congenital tooth agenesis and bimaxillary diastema, 159, 162, 163
 - diastema, orthodontic closure of
 - anterior segmental archwires, 2 × 4 appliances, 144, 145
 - flared maxillary incisors, retraction of, 143
 - generalised anterior diastemas, 144, 145
 - generalised diastemas, 146–148
 - Hawley appliance, 144
 - maxillary midline diastema, 145–146
 - minor diastema, distal crown angulation, 144
 - posterior teeth, mesialisation of, 143, 144
 - tooth movement, fixed orthodontic appliances, 144, 145
 - finger sucking and maxillary spacing, 149–151
 - frenectomy, timing of, 164–165
 - interdisciplinary management, 154
 - maxillary and mandibular generalised spacing, 151
 - microdentic upper lateral incisor, mesial positioning of, 153, 154
 - periodontal loss, spacing in, 162, 164
 - relapse and retention of diastema, 165–167
 - tooth-arch size discrepancy and bimaxillary generalised spacing
 - extra teeth, generating space for, 155, 159–162
 - periodontal surgery, 155, 158–159
 - redistribution of the spaces, 154–157

P

- Palpation
 - muscle examination
 - anterior temporalis muscle, 23, 24
 - digastric muscle, 26, 27

- lateral pterygoid, superior maxillary tuberosity, 24, 26
 - masseter muscle, 23, 24
 - medial pterygoid muscle, 24, 26
 - occipital muscle, 24, 25
 - sternocleidomastoid muscle, 24, 25
 - TMJ examination
 - mandible, opened and closed position of, 21
 - 12 o'clock position, 19, 20
 - Patient history. *See* Initial consultation and clinical considerations
 - Pink esthetics, 121
 - PLVs. *See* Porcelain laminate veneers (PLVs)
 - Polydiastema, 2
 - anterior esthetic concerns, 102
 - generalized spacing, teeth, 5, 6
 - maxillary digital model of, 51
 - Porcelain laminate veneers (PLVs), 3, 190
 - cementations of, 192, 194
 - diastema closure
 - fine diamond bur and porcelain polishing cup, 215
 - in-office bleaching, 212, 214
 - intraoral and radiographic examinations, 210, 211
 - maxillary anterior teeth, 210, 211
 - mock-up, silicone key, 212, 214
 - occlusion examination, 215, 216
 - smile analysis, 212, 213
 - teeth surface reductions and preparations, silicone index, 212, 215
 - temporomandibular joint examination, 211, 212
 - try-in pastes, 214, 215
 - wax setup, 211–213
 - disadvantages of, 175–176
 - esthetic restorations, 175
 - etching inner surface of, 192, 193
 - incisal crown lengthening and diastema closure, 178, 179
 - IPS e.max, bilayer fabrication technique, 192, 193
 - light-curing cement materials, 192, 194
 - minimal invasive tooth preparation for, 174, 175
 - natural tooth characteristics, 191
 - silane-coupling agent, hydrofluoric acid application, 192, 194
 - thickness of, 192
 - custom shade guide, 189, 190
 - Empress systems, 191, 192
 - hybrid-type composites, 187
 - IPS e.max CAD, 191, 192
 - IPS e.max Press, 191, 192
 - mechanical properties, 186
 - microfill composites, 187
 - nanocomposites, weight and distribution in, 186, 187
 - PLVs (*see* Porcelain laminate veneers (PLVs))
 - resin composite materials, 186–188
 - shade selection, 187–189
 - stratification technique, 186–188
 - try-in pastes, 193, 195
 - Vita shade scale, 188, 189
 - Ring esthetic dental (RED) proportions, 115, 117
- S**
- Sharpey's fibers, 125
 - Silicone index, direct composite buildup
 - chalky-white appearance, acid etching, 200, 202
 - clinical examination, 197
 - diamond impregnated polishing point, palatal surface, 203, 204
 - enamel layer, placement of, 203
 - etching mesial surfaces, phosphoric acid, 200, 202
 - extraoral photographs, 198, 199
 - fine diamond bur, 200, 201, 203
 - fine-grit diamond bur, 203, 204
 - finishing and polishing
 - polishing discs, 203, 204
 - postoperative appearance of restorations, 205
 - progressively finer-grit strips, proximal surfaces, 203, 204
 - intraoral and facial photographs, 205, 206
 - light-curing, adhesive bonding, 200, 202
 - lingual/palatal surface, 200, 202, 203
 - multimode adhesive bonding, enamel surface, 200, 202
 - palatal silicone putty index, 200
 - restorations and closed space, final natural appearance of, 205
 - retraction cords, placement of, 200, 201
 - shade selection, manufacturer's shade guide, 200, 201
 - TMJ evaluation, 197, 198
 - wax setup, 198, 199
- R**
- Restorative materials
 - ceramic systems, 190, 191

- Silicone matrices, diagnostic wax-up model
 acrylic overlays, use of, 45
 auto-cure temporary filling, 46
 control of, 42, 43
 overflowing temporary filling, 46
 pink matrix, 43, 44
- Soft tissue considerations, 3
 marginal gingiva, 128
 median diastema, 121, 123
 multiple Miller type III recessions, 121, 122
 papilla, 123, 124
 contact point/surface, position of, 123
 interdental papilla, 121
 interdental space, lateral walls of, 124–125
 neighboring teeth, 126
 root surface cementum, 125–126
 tissue biotype, 127
 tissues, health status of, 126
 single Miller type II recession, 121, 122
 treatment plan of diastemas, 121, 122
- T**
- Temporomandibular joint (TMJ), 197, 198
 load-bearing capacity, bimanual guidance, 22
 mandible, opened and closed position of, 21
 and muscle examination, 27
- 12 o'clock position, 19, 20
 step-by-step evaluation chart, 22
- Transseptal fibers, 126
- Treatment planning
 adhesive-type bridges, 134, 137
 clinical applications, restorative treatment chart, 138, 139
 frenectomy
 enlarged frenum, 132, 134
 and periodontal crown lengthening procedure, 132, 136
 full facial appearance, 133
 midline space, 137, 138
 multidisciplinary approach procedure, 132
 orthodontic-restorative combined procedures, 132, 135
 orthodontic treatment, 132, 134
 over-counter restoration, 132, 136
 restorative treatment, 132, 135
 smile design software, 132, 133
 vital bleaching, in-office/home technique, 137, 138
- V**
- Vita shade scale, 188, 189
- W**
- White esthetics, 121